

Successful Visual Recovery: A Challenge to Overcome After Pediatric Cataract Surgery

Jacqueline Machin Perez^{1,*}, Tania Milagros Fernandez Dominguez², Grester Anais Pineda Duran¹, Yenny Perez Recio¹, Lianne Morales Cardenas¹, Daniuby Perez Aguedo¹, Yuleika Nunez Rojas³, Eri Sanchez Lopez⁴

¹Ophthalmology Department, Octavio de la Concepcion de la Pedraja Children's Hospital, Holguin, Cuba

²Ophthalmology Department, Lucia Iniguez Landin Clinical Specialties-Surgical Hospital, Holguin, Cuba

³Languages Department, Faculty of Medical Sciences, Holguin, Cuba

⁴Department of Technical Services and Investments, Tourism Insurance Company - SERVISA S.A., Holguin, Cuba

Email address:

jmachin2009@gmail.com (Jacqueline Machin Perez), taniamila@infomed.sld.cu (Tania Milagros Fernandez Dominguez),

grether@infomed.sld.cu (Grester Anais Pineda Duran), yennyperez@infomed.sld.cu (Yenny Perez Recio),

lmc1981@infomed.sld.cu (Lianne Morales Cardenas), daguedo@infomed.sld.cu (Daniuby Perez Aguedo),

yule@infomed.sld.cu (Yuleika Nunez Rojas), erisanchez238@gmail.com (Eri Sanchez Lopez)

*Corresponding author

To cite this article:

Jacqueline Machin Perez, Tania Milagros Fernandez Dominguez, Grester Anais Pineda Duran, Yenny Perez Recio, Lianne Morales Cardenas, Daniuby Perez Aguedo, Yuleika Nunez Rojas, Eri Sanchez Lopez. Successful Visual Recovery: A Challenge to Overcome After Pediatric Cataract Surgery. *American Journal of Applied Scientific Research*. Vol. 9, No. 3, 2023, pp. 90-96. doi: 10.11648/j.ajars.20230903.12

Received: May 21, 2023; Accepted: July 3, 2023; Published: July 13, 2023

Abstract: *Introduction:* pediatric cataracts are rare, but challenging. Diagnosis delay and prompt treatment of this condition can lead to significant visual loss. The aim of the study was to evaluate the visual recovery after pediatric cataract surgery. *Methods:* a retrospective, descriptive, observational study was conducted at the Octavio de la Concepción de la Pedraja Children's Hospital, from January 2016 to December 2022. This included a sample of 65 eyes, corresponding to 52 patients. The following variables were evaluated: age, sex, etiology, poor preoperative visual prognostic factors, preoperative and postoperative visual acuity, as well as complications. *Results:* The age group 5 to 9 years predominated with 34.6% and the male sex with 78.8%. Congenital etiology represented 60% and the most relevant poor preoperative visual prognostic factors were strabismus (16.9%) and other ocular anomalies (20%). Preoperative visual acuity of light perception at 0.2 was present in 69.2% and postoperative visual acuity between 0.6 and 1.0 was obtained in 58.5%, reaching the vision unit 32.3% of the cases. The most common complication was posterior capsule opacity in 32.3%, and glaucoma was present in 4.6%. *Conclusions:* strabismus and other ocular anomalies that may negatively influence the final visual outcome after pediatric cataract surgery. However, good results are obtained with early diagnosis and timely treatment. Minimal incision has proven to be one of the most advantageous techniques in pediatric patients and additional procedures such as pupilloplasty may be necessary. Prevention and management of complications are also vital for a successful visual recovery.

Keywords: Pediatric Cataract, Cataract Surgery, Visual Acuity, Visual Rehabilitation

1. Introduction

Pediatric cataract is defined as any opacity of the crystalline lens present at birth or in childhood. Although it is not a common entity, it is an important cause of decreased vision, because if not treated in time it causes amblyopia,

resulting in many cases of low vision. This condition causes a reduction in best-corrected visual acuity secondary to neurological deficits in visual efference caused by abnormal brain stimulation during the critical period of visual development [1].

An estimated 1.4 million children worldwide are blind, 4% of whom are blind as a result of non-operated bilateral

cataracts, amblyopia due to late surgery, complications of surgery or the presence of other associated anomalies [2].

The overall incidence is estimated between 2.2 per 10,000 and 13.6 per 10,000 live births, varying from one region to another depending on early detection programs for eye diseases, immunization, as well as the genetic load of the populations in different geographic areas [3].

Congenital and pediatric cataract occurs in 10-30% of cases of blindness in children. In the USA it is reported in one of every 2,000 live births, in some form, and in Latin America it is estimated in one of every 200-300 births per year, being responsible for 5-20% of the causes of blindness during childhood [4].

Although cataract is a preventable cause of blindness in children, the decrease in visual acuity due to cataract is a huge problem in developing countries in terms of morbidity, economic loss and social burden [2]. A delay in surgical treatment leads to serious alterations in the organization of the visual function, as well as in the observable behaviors in the motor, cognitive and language areas, limiting the integral and adequate child's development [5].

Pediatric cataracts are divided into two main groups: congenital and acquired. Congenital cataracts can be idiopathic, hereditary or associated with genetic, metabolic and systemic diseases, uterine infections or associated with eye anomalies such as aniridia, anterior segment dysgenesis, microphthalmia, persistence of fetal vasculature and posterior lenticonus.

Acquired cataracts can be secondary to uveitis, intraocular tumors, retinal detachment, after laser treatment in retinopathy of prematurity, toxic, radiation exposure, the ingestion of long-term steroid medications, metabolic diseases, as well as traumatic cataracts due to contusion, penetrating wound or intraocular foreign body [2, 6].

Cataract management in the pediatric ages is long and complex. The functional outcome of this surgery is influenced by several factors such as age at diagnosis, age at surgical treatment and visual rehabilitation, so it is of vital importance to take measures during the critical period of visual development.

It is considered the end of the critical period of visual development between 7 and 8 years of age, although there are currently studies showing that this period exceeds 17 years of age [7]. However, visual development is most active and vulnerable during the first 3 months of life, because in late infancy development is slower and plasticity becomes progressively less. If visual stimulus is deficient, for instance, due to opacity of the crystalline lens, permanent damage is generated in the visual centers of the brain [4].

The treatment of this entity is surgical, but only those with a significant visual impact are intervened, since in pediatric ages, when the process of visual development is taking place, aphakia is more amblyopic than a small cataract [8].

At present, despite the development of surgical techniques in pediatric cataract surgery with intraocular lens implants, it is difficult to predict visual results, since the growth of the pediatric eye, the adequate compliance with the indicated

optical correction, as well as the therapy of amblyopia, make it impossible to establish a prediction of this long-term result.

Early treatment of this condition is essential to obtain good visual function [4], especially in unilateral cataracts, since patients with monocular cataract have two predisposing factors to develop amblyopia: binocular rivalry and visual deprivation [9].

In addition to this, there are other preoperative factors conditioning a poor visual prognosis, such as nystagmus, strabismus, wide interval between the age at diagnosis and surgery, as well as other associated eye anomalies. The presence of ocular deviations implies that the cataract has a long-term progress and that amblyopia is present.

Advances in microsurgery have allowed the surgical treatment of pediatric cataract to be a successful method, however, certain complications may occur such as: opacification of the posterior capsule, anterior uveitis with membrane formation, pupillary displacement, decentering of the intraocular lens, endophthalmitis, retinal detachment and glaucoma. The most important complication of pediatric cataract surgery, due to its amblyopic capacity, is posterior capsule opacity [10]. A delay in its diagnosis may lead to the development of irreversible amblyopia.

In a factual diagnosis of pediatric cataract patients attending the ophthalmology service of the "Octavio de la Concepción de la Pedraja" University Pediatric Hospital, it was found that most of them require surgical treatment. Taking into account the foregoing, the authors proposed as aim of this paper to evaluate the visual recovery in children who underwent surgery for this condition.

2. Method

A retrospective, descriptive, observational study was carried out. The medical records of patients suffering from congenital and acquired cataract treated at "Octavio de la Concepción de la Pedraja" Pediatric University Hospital, who underwent total or partial surgery in the province of Holguin, Cuba, between January 2016 and December 2022, were reviewed. A total of 65 eyes of 52 patients were included in the study. Patients who discontinued the consultation within the study date were excluded.

To diagnose cataract in these children, remote ophthalmoscopy and slit-lamp biomicroscopy were performed to determine the opacity of the crystalline lens. For surgical criteria, patients with central cataracts larger than 3 millimeters or partial cataracts with visual acuity of 20/40 or worse were considered.

The following demographic, etiologic and clinical variables were investigated in patients who underwent cataract surgery: age, sex, etiology, visual acuity (VA) without glasses (SGL) and best corrected (BC), as well as preoperative and postoperative refraction, preoperative poor visual prognostic factors, intraocular lens (IOL) implantation or not, undergoing or not amblyopia treatment, postoperative follow-up and complications.

1) Age groups: 0 to 4, 5 to 9, 10 to 14, 15 to 19.

- 2) Sex: male and female.
 - 3) Etiology: congenital and acquired. Acquired cataracts included traumatic and metabolic cataracts. Traumatic cataract comprising those produced by blunt trauma or penetrating wounds and metabolic cataracts in patients with diabetes mellitus and hypoparathyroidism.
 - 4) Visual acuity: best corrected preoperatively and postoperatively.
- Patients are grouped into:
- 1) LP (light perception) – 0,2
 - 2) 0,3 – 0,5
 - 3) 0,6 – 0,8
 - 4) 1,0

Both VA measurement and refraction were performed at the time of diagnosis and before surgery. They were monitored at the following day, week, month and 3 months. This was measured with Snellen chart, figures and numbers test according to age in verbal patients. In preverbal patients, fixation and tracking reflexes were taken into account. However, since visual acuity cannot be quantified by these methods, these patients were grouped as unconfirmed. For the preoperative refraction, schiascopy was performed after pharmacological mydriasis with 1% cyclopentolate and for the postoperative dynamic schiascopy.

As for the preoperative poor visual prognostic factors, the following were taken into account: nystagmus, strabismus, wide interval between the age at diagnosis and surgery (considered 3 months or more), unilaterality and other associated eye anomalies such as microphthalmos, microcornea or corneal opacities.

Those operated patients who had a difference of 2 lines of vision between each eye underwent amblyopia treatment. This consisted of patching the dominant eye from 2 to 6 hours a day, depending on age, with periodic check-ups and a minimum treatment duration of 9 months.

The surgical technique used consisted of capsulorhexis, aspiration of the crystalline material and insertion of foldable acrylic IOL in the capsular bag, through a small 3.2 mm self-sealing corneal incision in a clear cornea, valvular type, with superior temporal location, without sutures. IOL was implanted in patients older than 3 years, with good capsular support in the same surgical time and pupiloplasty was performed in cases of sphincter rupture.

Complications: posterior capsule opacity, fibrinous anterior uveitis, IOL decentration, pupillary displacement, endophthalmitis, retinal detachment and secondary glaucoma.

A registry was used as the primary source of information collection where patient data was collected, including age, sex, etiology of cataract, visual acuity (VA) without crystals (SGL) and best corrected (BC), as well as pre- and postoperative refraction, preoperative visual prognostic factors, whether or not the patient underwent intraocular lens (IOL) implants, whether or not amblyopia was treated, and complications. The medical records of all cases were reviewed. Data on surgical and postoperative procedures performed, as well as aspects related to visual rehabilitation

and follow-up were added to the registry.

The data were analyzed and processed using descriptive statistical methods and procedures: distribution of simple frequencies, absolute numbers and percentages. A database was created using Microsoft Excel (Office, 2013) and then SPSS for Windows version 20. The information collected was presented in tables and graphs, facilitating data management and results interpretation, as well as allowing conclusions to be reached.

3. Results

More than one third of the patients were between 5 and 9 years of age (34.6%), mainly males.

Table 1. Distribution of the patients undergoing surgery, according to age group and sex.

Age (years old)	Male		Female		Total	
	No.	%	No.	%	No.	%
0 – 4	7	13.5	7	13.5	14	27.0
5 – 9	17	32.6	1	2.0	18	34.6
10 – 14	14	27.0			14	27.0
15 – 19	3	5.7	3	5.7	6	11.4
Total	41	78.8	11	21.2	52	100

Source: medical records

Regarding the etiology, congenital cataract predominated in 60% of the eyes (n=39), in addition, traumatic cataract was present in 35.4% of the cases. (n=23) and metabolic cataract in 4.6% (n=3).

More than one third (38.4%) had preoperative poor visual prognostic factors: strabismus in 11 patients, nystagmus in 4, unilaterality in 8 and other eye anomalies in 13, including corneal opacities, as well as microcornea (Figure 1).

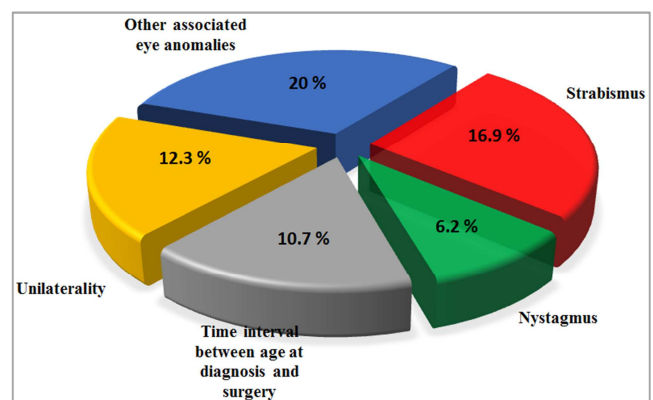


Figure 1. Distribution of patients according to preoperative poor visual prognosis factors.

Regarding visual acuity, (Table 2) shows that visual acuity with correction between LP- 0.2 (69.2%) was most commonly found in the preoperative examination. In the postoperative assessment, a VA of 0.6- 1.0 (58.5%) was achieved in more than half of the patients, reaching unity of vision in 32.3% of the cases. In eyes with vision less than 0.2 was associated with patients with late diagnosed congenital cataract and patients with traumatic cataract who had other

structural lesions.

Table 2. Distribution of patients according to preoperative and corrected postoperative visual acuity.

Visual Acuity	Preoperative		Postoperative	
	No.	%	No.	%
LP – 0,2	45	69.2	7	10.7
0,3 – 0,5	6	9.2	14	21.6
0,6 – 0,8			17	26.2
1,0			21	32.3
Not detected	14	21.6	6	9.2
Total	65	100	65	100

Source: medical records

Among the most common complications (Figure 2) was posterior capsule opacity (32.3%) and glaucoma was present in 4.6% of cases.

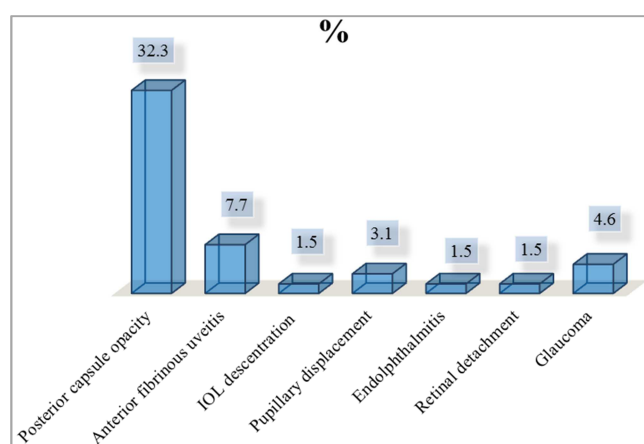


Figure 2. Distribution of patients according to postoperative complications.

4. Discussion

Congenital and pediatric cataracts are rare but challenging because delay in diagnosis and timely treatment may lead to profound visual loss. The definitive treatment remains surgery, in those that are visually significant, regardless of the surgical technique used. A group of factors makes pediatric cataract surgery more difficult to manage than adult cataract surgery, including difficulties in optical correction and rehabilitation, which may negatively influence the final visual outcome.

Early detection is essential for proper management. The need for treatment varies depending on whether they are dense cataracts present at birth, partial cataracts or developmental cataracts that may progress during childhood. Untreated dense cataracts lead to irreversible neurophysiological changes and amblyopia due to sensory deprivation [3].

In the study, the age group 5 to 9 years predominated, with 34.6%, similar to the study conducted by Jerez [9], who obtained a prevalence of 63.3% in this age group. However, these results differ from those found in other studies, where the age range of the operated children is between 2 months and 10 years [2]. Early diagnosis and proper treatment is vital

to obtain good results, in these cases, so screening programs that are carried out with aiming at diagnosing this and other eye conditions affecting visual development in the pediatric ages are considered essential.

The American Academy of Pediatrics (AAP), the American Academy of Ophthalmology (AAO), and the American Association for Pediatric Ophthalmology and Strabismus (AAPOS) have established that, at least, an eye examination with the Brückner maneuver (red pupil) should be performed at birth to rule out leukocoria and the patient should be immediately referred to a pediatric ophthalmologist for evaluation [2]. Early identification of cataract and proper treatment is the key to optimal results [11]. It represents a challenge for the ophthalmologist, not only because of its short-term surgical resolution, but also because of its postoperative follow-up and rehabilitation, the most important aspects of its treatment.

In terms of gender there was a prevalence of male, consistent with other authors, such as Guido Jimenez [4] and Burgos Elías [12] who reveal similar results, with 57.4% and 75%, respectively, in contrast to Busto, Zimmermann and collaborators [2] who find a prevalence of females. On the other hand, Shatnawi [13] considers that both sexes are affected almost equally.

In addition to timely intervention, pediatric cataract requires an accurate diagnosis because it is a highly heterogeneous disorder associated with a number of systemic diseases. Etiologies may include trauma, TORCH infections (toxoplasmosis, rubella, cytomegalovirus, herpes simplex and syphilis), intrauterine exposure to chemicals or drugs, biochemical alterations or genetic variation, including chromosomal abnormalities or disorders associated with single gene mutations [3, 8].

In this study, congenital cataracts prevailed in 60%, which coincides with another article [3] stating that the majority of pediatric cataracts have a genetic basis. Auto, Taylor and collaborators [3] affirm that the largest group presents an autosomal dominant inheritance, while in the present study only 3 bilateral cases were obtained, with a higher incidence of idiopathic congenital cases in 33 cases. These results are consistent with other authors who report a prevalence of congenital diseases with 23 patients (38.9%), with idiopathic diseases in first place [2].

As is evident, congenital and infantile cataracts result from multiple causes, such as family histories of congenital cataract, associated infectious diseases such as TORCHS, metabolic diseases and genetic syndromes [8, 11]. In this study, cataracts of metabolic cause were also found in genetic syndromes such as Wolfram and Kenny-Caffey.

Taking these elements into account, the pediatric cataract patient should be evaluated by a multidisciplinary team including assessment by pediatrics, genetics, endocrinology and other specialties. This entity may be a sign of a genetic, metabolic or systemic disease in an apparently healthy child.

Traumatic etiology represented an important element in the research, in 23 patients for 35.4%, consistent with other studies such as that of Jerez Carvajal [9] who obtained 35.9%.

Eye trauma is a significant problem worldwide and is the leading cause of unilateral non-congenital blindness in children. The incidence of severe visual impairment or blindness caused by pediatric eye trauma varies from 2% to 14% according to Burgos Elías [12].

In this study, traumatic cataracts were mainly due to blunt trauma and penetrating corneal wounds. This type of cataract, when it occurs during the stage of sensory plasticity, is capable of devaluing visual acuity, producing amblyopia by deprivation, even after adequate visual development has been achieved up to that point.

Regarding the preoperative poor visual prognosis factors, strabismus was found in 16.9%, the most common, similar to another article [4] where it was found in 38.9% of the cases. However, in other studies nystagmus is identified as the most significant with 61% [2], which does not coincide with this series in which it was present in only 6.2%. Unilaterality was another of the poor prognostic factors reported in 12.3%, coinciding with other authors such as Louison [14] and Uzun [15] who reported 26.8% and 37.1%, respectively.

Strabismus secondary to sensory deprivation is often associated with pediatric cataracts, generating sensory disturbances, requiring early surgical treatment. Unilateral strabismus needs to be managed faster for a better visual prognosis, because in this case the phenomenon of binocular rivalry is added to sensory deprivation [9, 16].

Postoperative VA was positive, 58.5% of the patients had final VA, with a correction of 0.6 - 1.0; results corresponding to those of other researchers, such as Burgos Elías [12] who reported good postoperative visual acuity in 63.6% of the patients, as well as Jerez Carvajal [9], who reported postoperative visual acuity between 0.5 and 1.0 in 52.4% of the cases. In patients with vision less than 0.2 it was related to congenital cataracts diagnosed late, traumatic cataracts that had other structural lesions such as corneal leukomas, in the case of wide penetrating wounds, retinal detachment secondary to the trauma itself and patients with secondary glaucoma, which led in these cases to poor final visual acuity.

Traumatic cataract is a special category, since it is associated with other eye alterations, such as corneal lesions (Figure 3), iris lesions, alterations in the cameral angle, vitreous hemorrhage, traumatic retinopathy and retinal detachment, which affect the patient's visual prognosis.

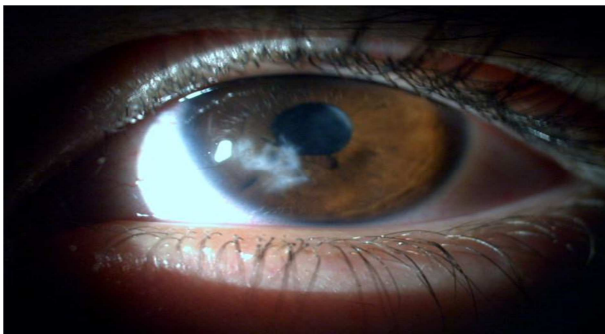

Figure 3. Corneal lesion in case with traumatic cataract.

In recent years, with the development of ophthalmology, equipment and instruments for eye microsurgery, the surgical technique for pediatric cataract surgery has been improved. These new procedures have allowed a better visual outcome and quality of life for patients affected by this entity.

Pediatric cataract surgery remains a complex procedure due to the characteristics of the child's eye. During cataract surgery the anterior chamber collapses due to positive vitreous pressure, the anterior and posterior capsule is more elastic, there is miosis and fibrin release, and the anterior and posterior capsule is more elastic [9]. Intraocular lens implants in these patients are a major challenge due to low scleral rigidity, anterior capsule elasticity, iris hypoplasia, immaturity of the trabecular meshwork and small eye size [3, 9].

In patients who underwent surgery at this Hospital, the surgical technique used consists of capsulorhexis, aspiration of crystalline material and foldable acrylic IOL implants in the capsular bag, through a small 3.2 mm self-sealing corneal incision in a clear cornea, valvular type, with superior temporal location, without sutures. IOL is implanted in patients older than 3 years, with good capsular support in the same surgical time and pupilloplasty is performed (Figure 4) in cases of sphincter rupture or other pupillary anomalies requiring it. Out of the 21 cases achieving unit vision, it was necessary to perform pupilloplasty in 9 patients due to other associated structural alterations, obtaining satisfactory visual results.

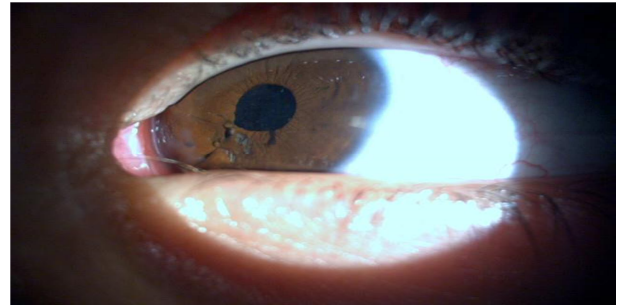


Figure 4. Pupilloplasty in ruptured sphincter in case of traumatic cataract.

Congenital or acquired iris anomalies may cause a number of symptoms in the patient such as photophobia, halos or even monocular diplopia in pseudophakic patients. Pupillary reconstruction has been shown to obtain better visual results by restoring a more physiological anterior chamber, with a pupillary diameter regulating the amount of light reaching the retina, decreasing the diffraction of the rays and allowing better focus and image sharpness [17].

A safe bimanual technique is recommended for most congenital and infantile cataracts. However, the choice of surgical technique may vary according to the characteristics of the affected eyes and the surgeon's preference. More than 50% of ophthalmologists in an AAPOS survey reported a preference for vitrectomy in young children and manual anterior capsulotomy in older children [3].

In the cases undergoing surgery in this study, sutureless valvular type microincision is preferred because it offers

some advantages compared to other techniques. It is safe, with a relative astigmatic neutralization, which means that in the child, in the absence of previous alterations, the corneal curvature is practically unchanged, the trans-operative time is shorter, decreasing the anesthetic risk, reducing costs and improving the postoperative cosmetic appearance of the globe [18, 19]. However, most pediatric surgeons prefer to use 10/0 Vicryl suture for the closure of the corneal incision, claiming greater safety [3].

The most common complication in this series was posterior capsule opacity (32.3%), consistent with other studies such as that of Louison [14] reporting this as the most common postoperative complication in 60% of unilateral cataracts and 46.3% of bilateral cataracts in his study. It coincides with other articles such as those by Shatnawi [13] and Uzun [15] who found it in 17.7% and 39% respectively.

Pediatric eyes have mitotically active lens epithelial cells leading to a higher incidence of posterior capsule opacification. The inflammatory response is severe in children and the membranes forming in the intact anterior vitreous result in opacification at this level as well. It is therefore essential to perform posterior capsulotomy and anterior vitrectomy in young children, which is recommended mainly for all children under 6 years of age, in order to avoid additional surgeries [15].

Regarding the patients in this research, capsulotomy and anterior vitrectomy were performed in the same surgery in all patients under 4 years of age, and those older than 4 years of age presenting posterior capsule opacity underwent capsulotomy with yag laser. Primary posterior capsulotomy and anterior vitrectomy are standard for young children as a result of the high rate of early posterior capsule opacification, which can be treated with yag laser capsulotomy in older children [20].

Another of the complications recorded was glaucoma, which although it was only found in 3 cases, is one of the most frightening. Glaucoma after cataract surgery may develop in the early postoperative period or even decades later, hence the importance of follow-up of pediatric cataract patients. In our study it occurred in patients with traumatic cataracts, probably secondary to structural alterations. This result does not coincide with other authors [13] reporting this complication in aphakic patients undergoing congenital cataract surgery. Some researchers maintain that in aphakic patients operated on before 4 weeks of age, the risk of glaucoma is increased [15, 21, 22].

5. Conclusion

Pediatric cataract is a highly heterogeneous disorder associated with a number of genetic and systemic diseases, so each case must be evaluated comprehensively for proper selection of surgical technique and IOL. There are some factors, such as strabismus, unilaterality and other ocular anomalies that can negatively influence the final visual outcome, so early diagnosis and timely treatment are essential for a good prognosis. In these patients, the growth of the eyeball, adequate compliance with optical correction and

amblyopia therapy make it impossible to predict the degree of long-term visual recovery. However, minimal incision has proven to be one of the most advantageous techniques in pediatric patients, guaranteeing good visual acuity. Pupilloplasty is also an important technique in pediatric cataract surgery, in which prevention and management of complications are vital for a good visual recovery.

Conflict of Interest

The authors declare that they have no competing interests.

Ethical Approval

The study was approved by the Institutional Ethics Committee.

Acknowledgements

To “William Soler” Pediatric Hospital and “Ramón Pando Ferrer” Cuban Institute of Ophthalmology (ICO) for their collaboration in the surgery of children under 3 years of age.

References

- [1] Lei Gao, Yang Gao, Fengrong Hong, Peng Zhang & Xiangwen Shu. (2021). Assessment of Foveal Avascular Zone and Macular Vascular Plexus Density in Children with Unilateral Amblyopia: A Systemic Review and Meta-Analysis. *Frontiers in Pediatrics* (9). <https://doi.org/10.3389/fped.2021.620565>
- [2] Evelyn del Busto Wilhelm, Martin Arturo Zimmermann Paiz, Ana Marissa Ordóñez Rivas, Nancy Carolina Quezada del Cid, Verónica Yaneth Burgos Elías & Nora Lucía Oliva Castillo. (2022). Characterization of congenital cataract and postoperative visual outcome in a Pediatric Ophthalmology Unit in a middle-income country. *Andes pediátrica* 93 (4). <http://dx.doi.org/10.32641/andespediatr.v93i4.3875>.
- [3] J. E. Self, R. Taylor, A. L. Solebo, S. Biswas, M. Parulekar, A. Dev Borman, J. Ashworth, R. McClenaghan, J. Abbott, E. O’Flynn, D. Hildebrand & I. C. Lloyd. (2020). Cataract management in children: a review of the literature and current practice across five large UK centres. *Eye* (34). doi: <https://doi.org/10.1038/s41433-020-1115-6>.
- [4] Marilú Anahí Guido Jiménez, José Fernando Pérez Pérez & María Estela Arroyo Yllanes. (2017). Strabismus in the patient with congenital cataracts: Clinical features. *Mexican Journal of Ophthalmology* 91 (3). <http://dx.doi.org/10.1016/j.mexoft.2016.04.011>
- [5] Lizbeth Uribe-Campos, Leticia Arroyo-Muñoz, Mario Mandujano-Valdés, Hortensia Moreno-Macías, Juan C. Zenteno-Ruiz, Roxana Muñoz-Hernández & Carmen Sánchez. (2018). Bilateral Congenital Cataract: Deprivation Amblyopia and its relation to development. *Mexican Journal of Ophthalmology*. 92 (4). doi:10.24875/RMO.M18000030.
- [6] Sudarshan Khokhar, Abhidnya Surve, Saurabh Verma, Shorya Azad, Parijat Chandra, Chirakshi Dhull & Rajpal Vohra. (2022). Cataract in retinopathy of prematurity – A review. *Indian Journal of Ophthalmology*. 70 (2). doi: 10.4103/ijo.IJO_125_21.

- [7] Santhan KS Gopal, Jai Kelkar, Aditya Kelkar & Abhishek. (2019). Simplified updates on the pathophysiology and recent development in the treatment of amblyopia: A review. *Indian Journal of Ophthalmology* (67). doi: 10.4103/ijo.IJO_11_19. PMID: 31436180; PMCID: PMC6727694.
- [8] Mehrdad Mohammadpour, Amirreza Shaabani, Alireza Sahraian, Bitá Momenaei, Fereshteh Tayebi, Reza Bayat & Reza Mirshahi (2019). Updates on managements of pediatric cataract. *Journal of Current Ophthalmology* (31). <https://doi.org/10.1016/j.joco.2018.11.005>
- [9] Fabiola Jerez Carvajal, Alberto Ehrler & Iván Espinoza. (2019). Visual results of cataract surgery in children at Hospital san Felipe January 2001-january 2017. *Acta Pediátrica Hondureña* 10 (1). <http://www.bvs.hn/APH/pdf/APHVVol10/pdf/APHVVol10-1-2019-4.pdf>
- [10] Ying-Bin Xie, Mei-Yu Ren, Qi Wang & Li-Hua Wang (2018). Intraocular lens optic capture in pediatric cataract surgery. *International Journal of Ophthalmology* (11). doi: 10.18240/ijo.2018.08.24. PMID: 30140648; PMCID: PMC6090124.
- [11] Natalia Rebottaro, Sandra Díaz, Carolina José, José Marmo, María Medina, Agustín Bernatzky, Ernesto Goldschmidt & Juan Pablo Berazategui. (2022). Congenital bilateral cataract in a newborn with Down syndrome. *Archivos de Pediatría del Uruguay*. 93 (2). <https://doi.org/10.31134/AP.93.2.24>
- [12] Verónica Y. Burgos-Elías, Ma. José Marroquín-Sarti, Martin A. Zimmermann-Paiz, Ana Marissa Ordoñez Rivas & Nancy C. Quezada-del Cid. (2018). Surgery of traumatic cataract in pediatric patients. *Archivos argentinos de pediatría*. 116 (3). doi: 10.5546/aap.2018.216.
- [13] Raed Shatnawi, Motasem Al-Latayfeh & Mohammad Abu-Ain. (2021). Cataract Surgery: A Retrospective Analysis of 62 Patients in a Developing Country. *Computational and Mathematical Methods in Medicine*. <https://doi.org/10.1155/2021/6431276>
- [14] S Louison, J Blan, C Pallot, S Alassane, A Praudel & A-M Bron. (2019). Visual outcomes and complications of congenital cataract surgery. *Journal francais d'ophtalmologie*. 42 (4). <https://doi.org/10.1016/j.jfo.2018.10.007>
- [15] Aslihan Uzun & Huban Atilla. (2020). Surgical outcomes of nontraumatic pediatric cataracts. *Journal of Ophthalmology* 10 (2). doi: 10.4236/ojoph.2020.102013.
- [16] Yooyeon Park, Hae Ri Yum, Sun Young Shin, Shin Hae Park. (2022). Ocular biometric changes following unilateral cataract surgery in children. Myopic shift in unilateral pseudophakia. *Plos One*. <https://doi.org/10.1371/journal.pone.0272369>.
- [17] Katarzyna Nowomiejska, Dariusz Haszcz, Katarzyna Adamczyk, Agnieszka Brzozowska, Vincenza Bonfiglio, Mario Damiano Toro & Robert Rejdak. (2022). Visual Outcomes of Pupiloplasty in Ocular Trauma and Iatrogenic Damage. *Journal of Clinical Medicine* (11). doi: 10.3390/jcm11113177.
- [18] Jacqueline Machin Pérez, Tania M. Fernández Domínguez, Josefina Chang Velázquez, Grester A. Pineda Durán, Daniuby Pérez Aguedo & Yadelin Escalona Almarales. (2018) Minor Incision pediatric cataract surgery. *CCM* 22 (4). <https://www.medigraphic.com/pdfs/correoccm/2018/ccm184h.pdf>
- [19] Pradhnya Sen, KritiChandra, Elesh Jain, Alok Sen, Amit Kumar, Amit Mohan & Chintan Shah. (2020). Audit of 1000 consecutive cases of sutureless cataract surgery in children above two years of age. *Indian Journal of Ophthalmology*. 68 (3). doi: 10.4103/ijo.IJO_1138_19.
- [20] Deborah K. VanderVeen & Lorri B. Wilson. (2022). Congenital and childhood cataracts. In: Albert, D. M., Miller J. W., Azar D. T., Young L. H. (eds) *Albert and Jakobiec's Principle and practice of Ophthalmology*. Springer, Cham. https://doi.org/10.1007/978-3-030-42634-7_278
- [21] Zuhui Zhang, Yana Fu, Jiajun Wang, Xinpei Ji, Zhangliang Li, Yinying Zhao, Pingjun Chang & Yun-e Zhao. (2022). Glaucoma and risk factors three years after congenital cataract surgery. *BMC Ophthalmology* (22). <https://doi.org/10.1186/s12886-022-02343-9>
- [22] Sooyeon Choe, Ahnul Ha, Sung Uk Baek, Jin-Soo Kim & Young Kook Kim. (2022). Incidence and risk factors of glaucoma after surgery for congenital cataract diagnosed. Protocol for KoNEC Study Protocol for Korean Nationwide Epidemiological Study for Childhood Glaucoma (KoNEC). *Plos One*. <https://doi.org/10.1371/journal.pone.0264020>