



Case Report

Case Report: Chloroquine Induced Keratopathy – Toxicity from Systemic Use

Daniel Choi¹, Stephen Orlin¹, Taylor Linaburg², Vivian Lee^{1,*}

¹Department of Ophthalmology, University of Pennsylvania, Philadelphia, United States

²Perelman School of Medicine, University of Pennsylvania, Philadelphia, United States

Email address:

Daniel.Choi@pennmedicine.upenn.edu (D. Choi), Stephen.Orlin@pennmedicine.upenn.edu (S. Orlin),

Taylor.Linaburg@pennmedicine.upenn.edu (T. Linaburg), Vivian.Lee@pennmedicine.upenn.edu (V. Lee)

*Corresponding author

To cite this article:

Daniel Choi, Stephen Orlin, Taylor Linaburg, Vivian Lee. Case Report: Chloroquine Induced Keratopathy – Toxicity from Systemic Use. *American Journal of Clinical and Experimental Medicine*. Vol. 8, No. 5, 2020, pp. 78-81. doi: 10.11648/j.ajcem.20200805.11

Received: August 13, 2020; **Accepted:** August 31, 2020; **Published:** September 30, 2020

Abstract: The application of chloroquine has been expanded over time from the treatment of malaria to a variety of connective tissue, inflammatory, and dermatologic disorders. More recently, chloroquine and its derivative, hydroxychloroquine, have been investigated for its possible application against SARS-CoV-2 due to their antiviral properties. We present a case of a patient receiving chloroquine as adjuvant therapy for glioblastoma multiforme who developed significant keratopathy and review this overlooked entity in view of the resurgence of this enduring medication. A 48-year-old woman with a history of Marfan syndrome presented with a five-day history of pain and discomfort in her right eye. She had a history of glioblastoma multiforme that had been treated with surgical resection, radiation, and chemotherapy and was currently undergoing adjuvant treatment with chloroquine and cimetidine. Her exam was notable for decreased visual acuity, bilateral epithelial erosions, multiple subepithelial white dots in a whorl-like distribution, and decreased corneal sensation. These corneal changes reversed following cessation of chloroquine. While chloroquine related retinopathy is reported frequently in the literature, the corneal changes related to chloroquine have been less frequently discussed. With the resurgence of interest in using chloroquine and hydroxychloroquine as therapy for SARS-CoV-2 due to their promising in-vitro activity against the virus [1, 2], corneal toxicity is an important side effect to identify and monitor.

Keywords: Chloroquine, Hydroxychloroquine, Keratopathy, Cornea, Glioblastoma Multiforme

1. Introduction

Hydroxychloroquine and chloroquine are two well-known medications that have been used for many decades to treat malaria and a variety of rheumatologic and inflammatory conditions. With the recent development of SARS-CoV-2 virus infecting nearly 8 million people worldwide, the scientific community has taken a renewed interest in chloroquine and hydroxychloroquine for their antiviral properties. Early in-vitro studies looking at these two medications have shown that they are effective in preventing coronavirus replication [1, 2]. While clinical studies evaluating the drugs' efficacy in vivo have been less favorable or limiting [3], there is sustained interest in its use in

SARS-CoV-2 infected patients [4]. On a broader scale, chloroquine may reinvent itself again in the future given that the drug and its analogues have also been found to have metabolic, cardiovascular, antithrombotic and antineoplastic effects [5].

With the increased prevalence and administration of chloroquine and hydroxychloroquine, the potential ophthalmological adverse effects of these medications must be revisited. Chloroquine can cause corneal deposits, posterior subcapsular lens opacity, ciliary body dysfunction, and retinal dysfunction [6]. The toxicity is often dependent on duration and dosage of drug taken. While chloroquine related

irreversible retinal toxicity is a well-known entity that was described as early as 1959 [7], chloroquine related corneal findings are less well known. Although drug deposition in the cornea has been observed in as many as 95% of patients taking the drug [8], these changes have been less frequently discussed, likely as a result of an overall decrease in the use of chloroquine [9] and the relatively benign nature of the keratopathy [10]. Given recent trends, discussion of ocular surface findings is significant as current treatment protocols targeting SARS-CoV-2 involve high doses of chloroquine/hydroxychloroquine. We present a case of a patient receiving chloroquine as adjuvant therapy for glioblastoma multiforme who developed significant keratopathy.

2. Case Report

A 48-year-old woman with a history of Marfan syndrome presented with a five-day history of pain and discomfort in her right eye. Her past ocular history was significant for strabismus surgery as a child and bilateral subluxed crystalline lenses two years prior to presentation. Since then, she underwent uncomplicated bilateral pars plana lensectomy with sutured intraocular lens implantation. She had a normal corneal exam at that time. Six months prior to the intraocular surgeries, the patient was diagnosed with glioblastoma multiforme and treated with surgical resection, radiation, and chemotherapy. She was subsequently placed on oral chloroquine and cimetidine as adjunctive cancer therapy, and had been on this regimen for five months prior to presentation. Additionally, she also participated in a phase II clinical trial with cilengitide, an antiangiogenesis drug.

On examination, she had bilateral, non-dendritiform, intrapalpebral, punctate epithelial erosions, more prominent in the right eye than left. There were anterior basement membrane changes bilaterally consisting of multiple subepithelial whitish dots in a whorl-like distribution, which had not been noted on prior examinations [Figure 1]. Furthermore, corneal sensation was decreased bilaterally. Her visual acuity was reduced from 20/20 in both eyes to 20/40 in the right eye and 20/25 in the left eye. Posterior segment examination however was normal. She was initially treated with topical lubrication and 1% prednisolone acetate eye drops in both eyes four times a day, which were then tapered over the following weeks. However, there was little improvement in her symptoms at 6-weeks follow up.

Because of the temporal relationship between the onset of the keratopathy and the duration of chloroquine therapy, drug toxicity was considered. After careful consultation with the patient and her oncologist, chloroquine was discontinued. The patient's foreign body sensation and discomfort resolved after a month while the anterior basement changes persisted for a few months longer. When the patient presented six months later, her corneas returned to baseline with no basement membrane changes noted, and visual acuity returned to 20/20 in both eyes [Figure 2].

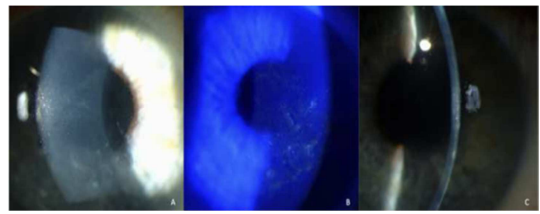


Figure 1. A. Right cornea demonstrating non-dendritiform, intrapalpebral, white punctate epithelial deposits and erosions. B. Some lesions stain with fluorescein. C. Additionally, anterior basement membrane changes consisting of multiple subepithelial whitish dots in a whorl-like distribution are present. The left cornea, which is not shown here, demonstrated similar findings (Photographs courtesy of Stephen E. Orlin, MD).

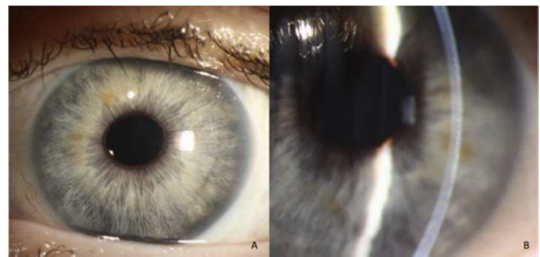


Figure 2. A. Right cornea demonstrating resolution of punctate epithelial keratopathy and B. anterior basement membrane changes. Findings in left cornea also resolved (not shown here) (Photos courtesy of Stephen E. Orlin, MD).

3. Discussion

The quinolone, chloroquine, has been used for malaria prophylaxis and treatment since 1946. Its applications have since been expanded to a variety of connective tissue, inflammatory, and dermatologic disorders. More recently, chloroquine has been shown to be effective as adjunctive therapy in prolonging midterm survival in patients with glioblastoma multiforme, possibly by potentiating the effect of radiation on prohibiting multiplication; inducing ultrastructural destruction; and preventing or delaying the transport of antineoplastic drugs from malignant glial cells [11].

Chloroquine and its metabolites, desethylchloroquine and N-acetyldesethylchloroquine, are absorbed completely from the digestive tract and deposited in large amounts in cellular tissues throughout the body [12]. Accumulations of the drug in tissue reservoirs slowly deplete over time but can persist as long as five years after discontinuation [12]. The ocular side effects of chloroquine therapy are thought to stem mainly from the deposition of the medication in ocular structures. In addition to causing epithelial and anterior basement membrane changes in the cornea, chloroquine has also been shown to affect the ciliary body causing accommodative weakness; crystalline lens causing axial posterior subcapsular cataracts; and retina causing maculopathy [12-14].

Calkins first reported corneal changes from chloroquine in 1958 in 7 patients with “halos” and reversible corneal pathology [10]. Clinically, the epithelial layer is most affected, where deposits present as punctate epithelial whitish dots that progress to a golden brown color [12, 13, 15]. Occasionally, the changes take on a whorl-like appearance just inferior to the

central cornea or involve the basement membrane [12]. In 1968, Percival et al. followed 272 patients taking either chloroquine or hydroxychloroquine and observed that the corneal changes were dose dependent and reversible [14]. More recently, Slowik et al. examined 20 patients on chloroquine using confocal scanning and found deposits in the wing cell layer of the epithelium and anterior stroma [15]. Xiaoyun et al. also utilized confocal microscopy to show that chloroquine was associated with hyperreflective deposits in the superficial epithelium, basal epithelium, anterior stroma, and posterior stroma [16]. Moreover, they found that chloroquine led to statistically significant reduction of anterior keratocyte density and abnormal sub-basal nerves [16]. Chloroquine induced changes to the corneal nerves may explain why up to 50% of patients on chloroquine may have decreased corneal sensation [12]. The earliest corneal changes have been documented after 8 weeks of chloroquine use and in up to 95% of patients [8]. Of note, early changes may not be visible on slit lamp examination and may only be seen with confocal microscopy.

Despite our knowledge about its metabolism in the body, the ocular changes caused by chloroquine are not precisely understood [17]. The retina appears to be exquisitely susceptible to toxicity from chloroquine because the drug has a high affinity for melanin, therefore accumulating preferentially in retinal pigment epithelium, uveal tract, and other pigmented ocular structures at much higher concentrations than elsewhere in the body [13]. The mechanism for chloroquine deposition in the cornea is even less well understood, but it is thought to involve an affinity between chloroquine and corneal acid mucopolysaccharides and nucleoproteins [13]. Chloroquine is concentrated in lysosomes and then protonated and complexed with polar lipids [13]. Key lysosomal enzymes, such as galactosidase A, are inhibited causing cell death [22]. Phospholipid debris is phagocytosed by neighboring keratocytes with inhibited lysosomal enzymes, leading to the accumulation of intracellular deposits [18, 19, 22]. This mechanism and presentation is similar to the inherited phospholipidosis, where there is an enzymatic deficiency in intralysosomal alpha-galactosidase A [18, 19, 22]. These corneal findings do not correlate to retinopathy and are, therefore, not useful for retinal toxicity screening purposes [17].

Although the use of chloroquine for connective tissue disease has diminished since the introduction of hydroxychloroquine [17], our patient was taking chloroquine as a chemotherapeutic agent for glioblastoma multiforme. In addition, our patient was also taking cimetidine concurrently, which has shown efficacy as adjuvant treatment for glioblastoma as well [20]. Cimetidine prolongs the clearance of chloroquine in healthy individuals shortening the half-life from 3.11 days to 4.62 days [21]. Given the high frequency of observed corneal changes, it has been suggested that if keratopathy is not seen in patients taking chloroquine, compliance should be questioned [8]. In contrast, only 10% of patients using hydroxychloroquine will show corneal changes; and if these changes are seen prominently, it should

prompt concern for over dosing [8].

4. Conclusion

In summary, chloroquine can cause numerous ophthalmological side effects that include corneal deposits, posterior subcapsular lens opacity, ciliary body dysfunction, and retinal dysfunction [6]. The toxicity is often dependent on duration and dosage of drug taken. Our case report demonstrates a specific example of chloroquine induced keratopathy that involved corneal epithelial erosions and deposits as well as anterior basement membrane changes that reversed with cessation of the drug.

On a broader scale, the renewed interest in the scientific community in using quinolones to treat SARS-CoV-2 patients places a new burden on physicians and ophthalmologists to have a heightened awareness of the potential for serious ocular complications of this drug.

References

- [1] Wang M, Cao R, Zhang L, Yang X, Liu J, Xu M, et al. Remdesivir and chloroquine effectively inhibit the recently emerged novel coronavirus (2019-nCoV) in vitro. *Cell Res.* 2020; 30 (3): 269-71.
- [2] Liu J, Cao R, Xu M, Wang X, Zhang H, Hu H, et al. Hydroxychloroquine, a less toxic derivative of chloroquine, is effective in inhibiting SARS-CoV-2 infection in vitro. *Cell Discov.* 2020; 6: 16.
- [3] Cavalcanti AB, Zampieri FG, Rosa RG, Azevedo LCP, Veiga VC, Avezum A, et al. Hydroxychloroquine with or without Azithromycin in Mild-to-Moderate Covid-19. *N Engl J Med.* 2020.
- [4] Arshad S, Kilgore P, Chaudhry ZS, Jacobsen G, Wang DD, Huitsing K, et al. Treatment with hydroxychloroquine, azithromycin, and combination in patients hospitalized with COVID-19. *Int J Infect Dis.* 2020; 97: 396-403.
- [5] Al-Bari MA. Chloroquine analogues in drug discovery: new directions of uses, mechanisms of actions and toxic manifestations from malaria to multifarious diseases. *J Antimicrob Chemother.* 2015; 70 (6): 1608-21.
- [6] Costedoat-Chalumeau N, Dunogue B, Leroux G, Morel N, Jallouli M, Le Guern V, et al. A Critical Review of the Effects of Hydroxychloroquine and Chloroquine on the Eye. *Clin Rev Allergy Immunol.* 2015; 49 (3): 317-26.
- [7] Hobbs HE, Sorsby A, Freedman A. Retinopathy following chloroquine therapy. *Lancet.* 1959; 2 (7101): 478-80.
- [8] Easterbrook M. Is corneal deposition of antimalarial any indication of retinal toxicity? *Can J Ophthalmol.* 1990; 25 (5): 249-51.
- [9] Wyler DJ. Landmark perspective: The ascent and decline of chloroquine. *JAMA.* 1984; 251 (18): 2420-2.
- [10] Calkins LL. Corneal epithelial changes occurring during chloroquine (aralen) therapy. *AMA Arch Ophthalmol.* 1958; 60 (6): 981-8.

- [11] Sotelo J, Briceno E, Lopez-Gonzalez MA. Adding chloroquine to conventional treatment for glioblastoma multiforme: a randomized, double-blind, placebo-controlled trial. *Ann Intern Med.* 2006; 144 (5): 337-43.
- [12] Bernstein HN. Chloroquine ocular toxicity. *Surv Ophthalmol.* 1977; 12 (5): 415-47.
- [13] Mason CG. Ocular accumulation and toxicity of certain systemically administered drugs. *J Toxicol Environ Health.* 1977; 2 (5): 977-95.
- [14] Percival SP, Meanock I. Chloroquine: ophthalmological safety, and clinical assessment in rheumatoid arthritis. *Br Med J.* 1968; 3 (5618): 579-84.
- [15] Slowik C, Somodi S, von Gruben C, Richter A, Guthoff R. [Detection of morphological corneal changes caused by chloroquine therapy using confocal in vivo microscopy]. *Ophthalmologe.* 1997; 94 (2): 147-51.
- [16] Ma X, He L, He D, Xu J. Chloroquine keratopathy of rheumatoid arthritis patients detected by in vivo confocal microscopy. *Curr Eye Res.* 2012; 37 (4): 293-9.
- [17] Marmor MF, Carr RE, Easterbrook M, Farjo AA, Mieler WF, American Academy of O. Recommendations on screening for chloroquine and hydroxychloroquine retinopathy: a report by the American Academy of Ophthalmology. *Ophthalmology.* 2002; 109 (7): 1377-82.
- [18] Muller-Hocker J, Schmid H, Weiss M, Dendorfer U, Braun GS. Chloroquine-induced phospholipidosis of the kidney mimicking Fabry's disease: case report and review of the literature. *Hum Pathol.* 2003; 34 (3): 285-9.
- [19] Seiler KU, Thiel HJ, Wassermann O. [Chloroquine keratopathy as an example of drug-induced phospholipidosis (contribution to the pathogenesis of cornea verticillata) (author's transl)]. *Klin Monbl Augenheilkd.* 1977; 170 (1): 64-73.
- [20] Lefranc F, Yeaton P, Brotchi J, Kiss R. Cimetidine, an unexpected anti-tumor agent, and its potential for the treatment of glioblastoma (review). *Int J Oncol.* 2006; 28 (5): 1021-30.
- [21] Ette EI, Brown-Awala EA, Essien EE. Chloroquine elimination in humans: effect of low-dose cimetidine. *J Clin Pharmacol.* 1987; 27 (10): 813-6.
- [22] Krachmer JH, Mannis MJ, Holland EJ. *Cornea: 2-Volume Set with DVD (Expert Consult: Online and Print), 3e.* 3rd ed. Mosby; 2010.