

Morphological Research of Incisor Root Resorption After Camouflaged Orthodontic Treatment of Adult Skeletal Class III Malocclusion

Wang Lin-na¹, Hou Yan¹, Zhang Yu-ze¹, Chang Wei-wei¹, Liu Zi-yang¹, Zhao Li-ru¹, An Shi-xuan², Ma Wen-sheng^{1,*}

¹Hebei Clinical Research Center for Oral Diseases, Hebei Key Laboratory of Stomatology, Department of Orthodontics, School and Hospital of Stomatology, Hebei Medical University, Shijiazhuang, China

²Department of Stomatology, Hebei Medical University, Shijiazhuang, China

Email address:

wlina90@sina.com (Wang Lin-na), Yilice@qq.com (Hou Yan), 853782050@qq.com (Zhang Yu-ze), 2308005681@qq.com (Chang Wei-wei), roman94@126.com (Liu Zi-yang), 136848172@qq.com (Zhao Li-ru), anshixuan@outlook.com (An Shi-xuan), wsma02@sina.com (Ma Wen-sheng)

*Corresponding author

To cite this article:

Wang Lin-na, Hou Yan, Zhang Yu-ze, Chang Wei-wei, Liu Zi-yang, Zhao Li-ru, An Shi-xuan, Ma Wen-sheng. Morphological Research of Incisor Root Resorption After Camouflaged Orthodontic Treatment of Adult Skeletal Class III Malocclusion. *American Journal of Clinical and Experimental Medicine*. Vol. 11, No. 3, 2023, pp. 47-51. doi: 10.11648/j.ajcem.20231103.11

Received: May 8, 2023; Accepted: May 26, 2023; Published: May 29, 2023

Abstract: *Objective:* CBCT and Mimics software were performed to investigate the incisor root resorption after camouflaged orthodontic treatment of adult skeletal class III malocclusion. *Methods:* Thirty permanent dentition adult patients with skeletal class III malocclusion were included in orthodontic department. CBCT data of each patient at pretreatment and posttreatment were acquired and three-dimensional (3D) digital models were reconstructed. Image registration was performed of each incisor 3D model before and after camouflaged treatment. Observation, classification and statistics of 3D model overlap were performed, as well as the morphological changes of root resorption were described. *Results:* (1) Either the upper or lower incisors, slope form resorption had the most percentage (49.17%, 46.67%; 51.67%, 49.16%), followed by cone-shaped form resorption, and flat form resorption had the less percentage. In the upper incisors, the root resorption was mainly in the lingual-labial direction (46.67%, 41.67%), while in the lower incisors, it was in the labial-lingual direction. (2) The result of Kappa consistency test is good ($K=0.471, 0.441$). *Conclusions:* The root of the upper and lower incisors showed various morphological changes after camouflaged treatment of adult skeletal class III malocclusion. The absorption was mainly manifested as slope form and cone-shaped form, and flat form resorption can be seen. 3D model registration can be used as a reliable auxiliary method for the morphological study of root absorption.

Keywords: Skeletal Class III Malocclusion, Camouflaged Treatment, Three-Dimensional Reconstruction, Registration, Root Resorption, Morphology

1. Introduction

Adult skeletal class III malocclusion is a relatively common type of malocclusion in clinical [1]. For mild skeletal class III malocclusions, camouflaged orthodontic treatment is often chosen, and the degree of skeletal deformity is concealed by continuing to tilt the upper anterior teeth to the lip and tilting the lower anterior teeth to the

tongue [2-4]. Studies have shown that root resorption is highly related to orthodontic treatment, and the incidence is higher in the upper and lower incisors [5, 6]. Root resorption is characterized by volume reduction in three dimensions. More and more scholars use CBCT three-dimensional images to observe the morphological characteristics of root resorption, but the three-dimensional information has not been fully utilized [7, 8]. Mimics (materialise's interactive medical image control system) can restore the CBCT data to

a three-dimensional model, which can more fully and comprehensively reflect the morphological characteristics of the tooth root. Based on this, this paper uses Mimics software to analyze the CBCT data before and after adult mild skeletal class III malocclusion camouflaged treatment, reconstruct and register the 3D model of the incisors before and after treatment, and obtain the overlapping images of the 3D model. The morphological changes of root resorption in the incisors after treatment should be described to provide a reference for incisor movement in camouflaged treatment for skeletal class III malocclusion.

2. Materials and Methods

2.1. Normal Information

A total of 30 adult skeletal class III malocclusion orthodontic treatment patients were selected from the Department of Orthodontics, School and Hospital of stomatology, Hebei Medical University during 2014-2022, including 13 males and 17 females, with an average age of (24.22 ± 2.30) years.

Inclusion criteria: 1) Aged 18-40 years old. 2) Mild skeletal Class III malocclusion in adults, $-2^\circ < \text{ANB} < 0^\circ$. 3) Patient case records are complete. 4) The incisor root has been fully developed, the shape is normal, the pulp vitality is normal, there is no history of trauma, and the incision margin has no obvious change during orthodontic treatment. 5) Good oral hygiene, healthy gum tissue, no gingival swelling or gingival recession, no periodontal tissue disease. 6) Two experienced orthodontists in the department use standard straight wire arch technology to complete the orthodontic treatment, without tooth extraction, with light force throughout the process, and the treatment course is 1.5-2.5 years. 7) All patients have signed the informed consent before participating in this study. This study has been approved by our Ethics Committee (No. [2021] 053).

Exclusion criteria: 1) Having neurological diseases or cognitive dysfunction, unable to cooperate with the treatment and examination. 2) Congenital specific root deformity and cheilopalatoschisis patients. 3) Incisor trauma history, root canal treatment history, orthodontic treatment history, combined orthognathic and orthodontic treatment history.

2.2. Methods

The subjects were taken wide-field CBCT (KaVo 3D eXam, Germany) before treatment (T0) and after treatment (T1). The scanning parameters were tube voltage 120kV, tube current 5mA, effective exposure time 4s, and scanning layer thickness 0.3mm.

The patient's shooting position: the patient takes the upright sitting position, adjusts the head position with the mandibular splint, so that the frankfort horizontal plane is parallel to the ground, the upper and lower dentition are lightly closed at the intercuspal position, and the upper and lower lips are naturally closed. All subjects were collected by the same radiologist using the same CBCT machine.

All the medical images collected from subjects should be

first processed and digitized by the dedicated CBCT graphics workstation, and those digital medical images should be uniformly saved in the DICOM storage format. After being read by Mimics 17.0 (Materialise, Belgium), the 3D model of the upper and lower incisors before and after orthodontic treatment was reconstructed (threshold value 1279 ~ 4287), through threshold segmentation, region growing, and layer-by-layer editing (Figure 1). Carry out three-dimensional model registration on the three-dimensional reconstruction model of the incisors of the same tooth before and after orthodontic treatment. Specifically run the "Registration-Global registration" command, set the registration parameters in "Settings", and select "Automatic" to let the computer automatically set for registration (Figure 2). Select two orthodontists as observers to observe the overlapping images of the three-dimensional models of 120 maxillary incisors and 120 mandibular incisors, then do classification and statistic according to the different absorption forms of the roots.

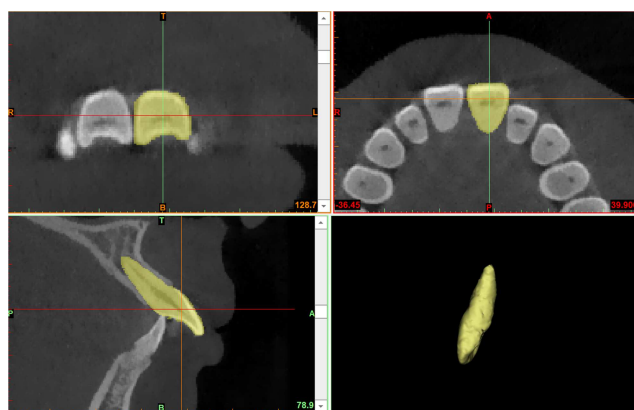


Figure 1. 3D reconstruction model of teeth.

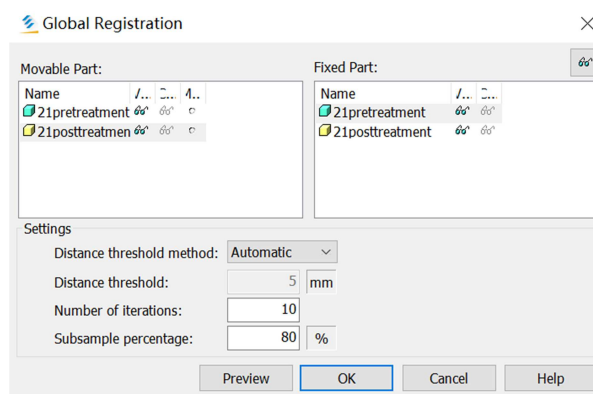
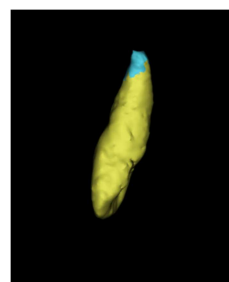


Figure 2. 3D model registration.

2.3. Statistical Method

Using SPSS 21.0 to perform statistical analysis on the data, cross-tabulate the classification results of the three-dimensional model overlay diagrams of the upper and lower jaw incisors after observation; and perform Kappa consistency test. $K < 0.4$, consistency is poor; K value is $[0.4, 0.75]$, consistency is good; $K > 0.75$, consistency is excellent.

3. Results

3.1. Classification Results of Three-Dimensional Models of Upper and Lower Incisors Before and After Camouflaged Orthodontic Treatment

According to the morphological classification of root resorption by Campos MJ [9] in 2013, observations in Table 1. The four absorption forms in the results were type I, type

IV, type V and type VI. It manifests as flat form, cone-shaped form, slope form from the labial side to the lingual side (Labial-lingual slope form), and slope form from the lingual side to the labial side (Lingual-labial slope form) (Figure 3).

The root resorption in the maxillary incisors was mainly characterized by type IV conical absorption and type V Lingual-labial slope form, which accounted for (28.33%, 29.17%) and (46.67%, 41.67%) respectively. The proportion of no obvious absorption and type I was next, and the proportion of type VI was the smallest (2.50%, 5.00%). The root resorption in the mandibular incisor group was mainly characterized by type IV cone-shaped form and type VI Labial-lingual slope form, accounting for (27.50%, 26.67%) and (49.17%, 43.33%) respectively. The proportion of no obvious absorption and type I was next, and the proportion of type V was the smallest (2.50%, 5.83%).

Table 1. Statistical observation results of 3D overlapping images of upper and lower incisors before and after camouflaged orthodontic treatment.

observer	No obvious absorption n (%)	Type I n (%)	Type IV n (%)	Type V n (%)	Type VI n (%)
Maxillary					
A	12 (10.00)	15 (12.50)	34 (28.33)	56 (46.67)	3 (2.50)
B	11 (9.17)	18 (15.00)	35 (29.17)	50 (41.67)	6 (5.00)
Mandible					
A	8 (6.67)	17 (14.17)	33 (27.50)	3 (2.50)	59 (49.17)
B	12 (10.00)	17 (14.17)	32 (26.67)	7 (5.83)	52 (43.33)

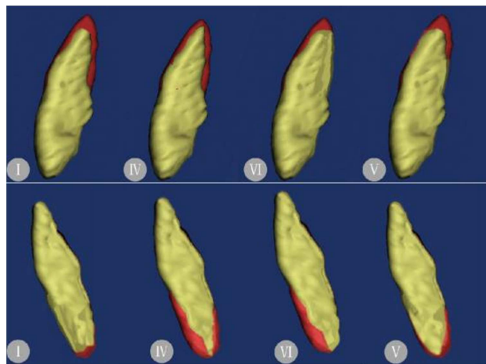


Figure 3. The morphological changes of root resorption with upper and lower incisors.

(I. flat form; IV. cone-shaped form; VI. Labial-lingual slope form; V. Lingual-labial slope form)

3.2. Kappa Consistency Test

The results of cross-tabulation showed that no matter the maxillary incisors or the mandibular incisors, the root resorption observed by the two observers was mostly slope form, followed by type IV cone-shaped form, and the other types were relatively less. In the maxillary incisor group, the slope absorption was mainly type V lingual-labial slope form, while in the mandibular incisor group, the slope absorption was mainly type VI Labial-lingual slope form (Table 2, Table 3).

Table 4 shows that the K value of the Kappa consistency test for two observers in the maxillary incisor group was 0.471, and the consistency was good; the K value of the Kappa consistency test for two observers in the mandibular incisor group was 0.441, and the consistency was good.

Table 2. Cross tabulation of the observation results of two observers in the maxillary incisor group.

Observer A	Observer B					total
	no absorption	Type I	Type IV	Type V	Type VI	
no absorption	5	6	1	0	0	12
Type I	3	6	4	2	0	15
Type IV	3	2	20	6	3	34
Type V	0	4	10	42	0	56
Type VI	0	0	0	0	3	3
total	11	18	35	50	6	120

Table 3. Cross tabulation of the observation results of two observers in the mandibular incisor group.

Observer A	Observer B					total
	no absorption	Type I	Type IV	Type V	Type VI	
no absorption	4	2	0	0	2	8
Type I	4	10	2	1	0	17
Type IV	4	2	18	0	9	33
Type V	0	0	0	2	1	3
Type VI	0	3	12	4	40	59
total	12	17	32	7	52	120

Table 4. Results of Kappa consistency test for two observers.

group	Kappa	Consistency
maxillary incisor group	0.471	good
mandibular incisor group	0.441	good

4. Discussion

Root resorption is a very common complication in orthodontic treatment [10]. There are many related researches on the morphological changes of root resorption by scholars, mainly in the following three ways: observing the morphological changes of the apical root on two-dimensional plain films, observing the pit-like changes on the root surface on Micro-CT scanning images, observing the changes of the root surface on the largest sagittal longitudinal section of the tooth on the CBCT image [9, 11, 12]. Based on the use of CBCT, this study makes full use of the real restoration and 3D reconstruction characteristics of Mimics software, and adopts the overall registration method for the 3D models of incisors before and after treatment, that is, the computer automatically performs the registration on two STL models with similar geometric configurations. Select multiple corresponding points to fit the transformation matrix, and perform multiple iterative operations at the same time, so that there is a minimum distance between corresponding points on the two STL models after registration. In the end, the two models are overlapped together so that the two models have the largest overlap, thus the geometric configuration changes between the two 3D models of the incisors before and after orthodontic treatment can be better observed, furthermore, we can observe the morphological changes of root resorption and its distribution on the root surface more intuitively. This method can be applied to various types of morphological studies of root resorption in malocclusion orthodontic treatment.

Camouflaged treatment is aimed at correcting the anterior crossbite or open bite, adjusting the relationship between molars and canines, and improving the profile to a certain extent [13, 14]. Proper vertical depression or elongation of the upper and lower incisors, release of twist, application of torque, etc. are required, which inevitably result in varying degrees of root resorption. The resorption site of the root behaves differently due to the different stress distribution. Rudolph DJ [15] studied the stress distribution of maxillary central incisors by three-dimensional finite element analysis method, and found that the stress concentrated on the alveolar crest after the tilting force was loaded, and the stress

is mainly concentrated in the apical area when depression force, elongation force and rotation force were loaded, and it shows that if the correction force is too large, it is easy to cause apical resorption. The flat absorption, cone-shaped absorption and slope absorption observed in this study all show the absorption mainly in the apical area. Flat resorption and cone-shaped resorption mostly occur when the range of incisor movement is not large, and the stress distribution is relatively uniform in one-third of the apex, and the main manifestation is the shortening and thinning of the apex. For slope absorption, the upper and lower incisors show different absorption directions, the maxillary incisors are mostly obliquely from the lingual side to the labial side, and the mandibular incisors are mostly obliquely from the labial side to the lingual side. This is due to the relatively large range of labial-lingual movement of the teeth, and the uneven distribution of stress in the apical area: the maxillary incisors compensate for the labial movement of teeth as well as palatal movement of the root, and the stress is more concentrated on the palate side of apical 1/3. The mandibular incisors are more concentrated on the labial side of the apical 1/3 due to the compensatory tooth lingual movement and root labial movement. Although the crown-lingual and root-labial torque was added to the maxillary incisors, meanwhile the crown-lip and root-lingual torque was added to the mandibular incisors, the upper and lower incisors still produced obvious compensation of labial inclination and lingual inclination respectively in order to establish normal covebite, overjet and cover up the malposition of the upper and lower jaws. Weltman [5] and Roscoe [16] also pointed out that the degree of root resorption is positively correlated with the applied force and torque. It is suggested that orthodontists should pay attention to using light force in the process of camouflaged treatment, so that the force on the incisors should be as uniform as possible and moderate torque should be applied to the incisors to avoid severe root resorption.

Lyu Hangmiao [17] et al. found that in patients with skeletal class III malocclusion, during combined orthodontic and orthognathic treatment, the root volume reduction of the upper central incisors was mainly shown in the bodily part that was biased towards the apex of the tooth, and the volume reduction of the cervical part was less obvious than the former, but still not be negligible. In this study, the observers failed to observe the obvious absorption of the cervical part in the root model after the registration overlap, but it should still cause our great attention. In addition, some of the observations in this study showed no absorption, and

through analysis there may be caused by the following reasons: 1) All cases were treated with light force, and the amount of root absorption in some teeth was rather small; 2) The slight volume changes on the overlapping image after the 3D model reconstruction are not easy to be recognized by the naked eye. 3) Irregular pit-shaped absorption on the root surface is not as regular and easy to identify as shown in the schematic diagram. In this study, the consistency test of two observers eliminated the observation bias of a single observer, and obtained a consistent description of the morphological changes of the upper and lower incisor root absorption after orthodontic treatment, which improved the reliability of the research results [18]. However, this study is only a qualitative analysis of morphology. In order to clarify the severity of root resorption, it is necessary to establish detailed evaluation indicators and conduct more specific quantitative analysis.

5. Conclusion

The root of the upper and lower incisors showed various morphological changes after camouflaged treatment of adult skeletal class III malocclusion.

The absorption were mainly manifested as slope form and cone-shaped form, which were mainly shown as thinner and shorter of the apical root, and flat form resorption can be seen. The direction of slope absorption may be related to the compensatory movement of incisors, which still needs to be further explored.

It is suggested that the orthodontist should pay special attention to the root health of the incisor region, set the compensatory target carefully, and apply the corrective force and torque reasonably.

3D model registration can be used as a reliable auxiliary method for the morphological study of root absorption. Based on our current qualitative analysis, it is necessary to establish detailed evaluation indicators and conduct more specific quantitative analysis in future.

Acknowledgements

This study was supported by the grants from S & T Program of Hebei (No. 22377764D), Hebei Medical Science Research Project (No. 20221444), Hebei Medical University Student Innovative Experiment Program (No. USIP2022243).

References

- [1] Park JH, Emamy M, Lee SH. Adult skeletal class III correction with camouflage orthodontic treatment. *Am J Orthod Dentofacial Orthop*, 2019, 156 (6): 858-869.
- [2] Martinez P, Bellot-Arcís C, Llamas JM, et al. Orthodontic camouflage versus orthognathic surgery for class III deformity: comparative cephalometric analysis. *Int J Oral Maxillofac Surg*, 2017, 46 (4): 490-495.
- [3] Eslami S, Faber J, Fateh A, et al. Treatment decision in adult patients with class III malocclusion: surgery versus orthodontics. *Prog Orthod*, 2018, 19 (1): 28.
- [4] Lu CL, Li BW, Yang M, et al. Relationship between alveolar-bone morphology at the mandibular incisors and their inclination in adults with low-angle, skeletal class III malocclusion-A retrospective CBCT study. *PLoS One*, 2022, 17 (3): e0264788.
- [5] Weltman B, Vig KW, Fields HW, et al. Root resorption associated with orthodontics tooth movement: a systematic review. *Am J Orthod Dentofacial Orthop*, 2010, 137 (4): 462-476.
- [6] Araujo MTS, Squeff LR. Orthodontic camouflage as a treatment alternative for skeletal Class III. *Dental Press J Orthod*, 2021, 26 (4): e21bbo4.
- [7] Deng Y, Sun Y, Xu T. Evaluation of root resorption after comprehensive orthodontic treatment using cone beam computed tomography (CBCT): a meta-analysis. *BMC Oral Health*, 2018, 18 (1): 116-130.
- [8] Liedke GS, da Silveira HE, da Silveira HL, et al. Influence of voxel size in the diagnostic ability of cone beam tomography to evaluate simulated external root resorption. *J Endod*, 2009, 35 (2): 233-235.
- [9] Campos MJ, Silva KS, Gravina MA, et al. Apical root resorption: the dark side of the root. *Am J Orthod Dentofacial Orthop*, 2013, 143 (4): 492-498.
- [10] Sameshima GT, Iglesias-Linares A. Orthodontic root resorption. *J World Fed Orthod*. 2021, 10 (4): 135-143.
- [11] Glenn T. Sameshima, Kati O. Asgarifar. Assessment of Root Resorption and Root Shape: Periapical vs Panoramic Films. *Angle Orthod* 2001, 71: 185-189.
- [12] Zhuang Li, Meng Xianying, Li Ping, et al. A pilot study on three dimensional morphology of root by Micro-CT during orthodontic root resorption. *Journal of Modern Stomatology*, 2010, 24 (1): 36-38.
- [13] Qv Xinghui, Shi Youling, Ma Yan, et al. Study on the effect of posterior splint combined with microimplant technique in the treatment of angle Class III malocclusion. *Journal of Clinical Stomatology*, 2022, 38 (02): 90-93.
- [14] Kawai N, Watanabe M, Shibata M, et al. Treatment decision of camouflage or surgical orthodontic treatment for skeletal Class III patients based on analysis of masticatory function. *J Dent Sci*. 2022, 17 (2): 822-830.
- [15] Rudolph DJ, Willes PMG, Sameshima GT. A finite element model of apical force distribution from orthodontic tooth movement. *Angle Orthod*, 2001, 71 (2): 127-131.
- [16] Roscoe MG, Meira JB, Cattaneo PM. Association of orthodontic force system and root resorption: a systematic review. *Am J Orthod Dentofacial Orthop*, 2015, 147 (5): 610-626.
- [17] Lyu Hangmiao, Gao Juan, Ma Huimin, et al. Three-dimensional root resorption of maxillary anterior teeth in skeletal class III patients: a cone beam computed tomography study. *Chinese Journal of Orthodontics*, 2020, 27 (03): 129-133.
- [18] Landis JR, Koch GG. The measurement of observer agreement for categorical data. *Biometrics*, 1977, 33: 159-174.