

# Our Experience of Outpatient Treatment of Infantile Haemangiomas with Oral Propranolol

Rada Markova<sup>1,2,\*</sup>, Zdravka Demerdjieva<sup>3</sup>, Jana Kazandjieva<sup>4</sup>

<sup>1</sup>Medical Centre “1-st Pediatric Consultative Clinic”, Sofia, Bulgaria

<sup>2</sup>Department of Pediatrics, Medial University, Pleven, Bulgaria

<sup>3</sup>Department of Dermatology, “Tokuda” Hospital, Sofia, Bulgaria

<sup>4</sup>Department of Dermatology, University Hospital “Alexandrovska”, Sofia, Bulgaria

## Email address:

[rada\\_markova@yahoo.com](mailto:rada_markova@yahoo.com) (R. Markova)

\*Corresponding author

## To cite this article:

Rada Markova, Zdravka Demerdjieva, Jana Kazandjieva. Our Experience of Outpatient Treatment of Infantile Haemangiomas with Oral Propranolol. *American Journal of Internal Medicine*. Vol. 9, No. 6, 2021, pp. 273-279. doi: 10.11648/j.ajim.20210906.16

**Received:** October 26, 2021; **Accepted:** November 26, 2021; **Published:** December 11, 2021

**Abstract:** Infantile hemangiomas are the most common benign vascular tumors in infancy. Their incidence is between 3-10%. They are more frequently observed in females, in preterm babies and in case of perinatal stress. Most of the infantile hemangiomas are benign and do not need systemic treatment, only 12-15% need an oral treatment with Propranolol. The invention of their treatment with oral Propranolol makes a huge revolution in their course. Oral Propranolol (Hemangiol sir) is already well known for accurate dosing and treatment of infantile hemangiomas. The accurate diagnosis and early treatment are very important for a child prognosis and hemangioma evolution. The treatment must be started in the stage of hemangioma progression in order to have a good final response. The treatment can be started in out- patient or in- patient option with good clinical effect and results. Patients must be prepared with laboratory investigations, dermatology and cardiology consultation. The dose is carefully increased from 1mg/kg to 2 mg/kg and 3 mg/kg/day in a week interval. The dose of 3 mg/kg is the therapeutic dose. We present our experience in management and treatment of infantile hemangiomas. In our clinic as an out – patients twenty patients are observed. Our results demonstrate very satisfied results in the involution of treated patients.

**Keywords:** Infantile Hemangiomas, Propranolol, Out-Patient Treatment

## 1. Introduction

Infantile hemangiomas (IH) are the most common benign vascular tumors in infancy and early childhood. Their incidence is between 3% and 10%, more often observed in premature children. [1, 2] Infantile hemangioma is the consequence of both postnatal vasculogenesis and angiogenesis. [3-5] Hypoxia appears to play an important role as a contributory factor. Infantile hemangiomas have variable clinical features: superficial, deep or mixed. They can be localized or segmental involving a large skin area. [6]

A majority of infantile hemangiomas are mild and do not require any treatment. Main indications for treatment are: vital risk (heart failure, respiratory distress), functional risk (amblyopia, swallowing disorders, etc.), painful ulceration and disfigurement. [13]

IH have a proliferative course and are suitable for treatment in early infancy. Dr. Christine Leaute-Labreze's discovery of treatment for infantile hemangiomas with oral Propranolol set up a new era in their treatment and prognosis with very good therapeutic results. [13] Topical Timolol may be used to treat select small, thin, superficial IHs. Surgery and/or laser treatment are most useful for the treatment of residual skin changes after involution and, less commonly, may be considered earlier to treat some IHs.

A small subset of children with IHs have associated congenital anomalies. [14-16] The best-known phenomenon is PHACE syndrome. The acronym “PHACES” is sometimes used instead to include potential ventral midline defects, specifically sternal cleft and/or supraumbilical raphe. Cerebrovascular anomalies, present in more than 90% of patients with PHACE syndrome, are the most common extracutaneous feature of the

syndrome, followed by cardiac anomalies (67%) and structural brain anomalies (52%). The hallmark of PHACE syndrome is a large (often >5 cm in diameter) segmental IH that typically involves the face, scalp, and/or neck. [8] The risk of PHACE syndrome in an infant presenting with a large segmental IH of the head or neck is approximately 30%. Revised consensus criteria for the diagnosis of PHACE syndrome and the care of infants who are affected have recently been published. [7]

LUMBAR syndrome may best be viewed as the “lower half of the body” equivalent of PHACE syndrome. [10-12] IHs in LUMBAR syndrome are almost invariably segmental, involving the lumbosacral or perineal skin and often extending onto 1 leg. Many IHs in LUMBAR syndrome are minimally proliferative morphologically, with telangiectatic vascular stains predominating over bulkier superficial hemangiomas. In such cases, ulceration can be an early clue to the diagnosis. Rarely, undergrowth or overgrowth of an affected limb may be present. Like PHACE syndrome, the cutaneous IH and underlying anomalies in LUMBAR syndrome reveal regional

correlation. Myelopathy, particularly spinal dysraphism, is the most common extracutaneous anomaly.

It is important to know the three stages of hemangiomas: evolution (proliferation)- up to 6 months, plateau (6-18 m) and involution (usually after 18 months to 3-7 years of age) and to treat them in early proliferative phase [Figure 1]. Most infantile haemangiomas involute well, and over half of children have normal skin at the site of the lesion. Residual changes may include scar, redundant skin, anetoderma, fibrofatty residuum, telangiectases, or dyspigmentation. Painful ulceration is the most common complication occurring in 15% of infantile haemangiomas around 4 months of age. [9]

A white change may herald the onset of ulceration while the lesion is still solid. Large segmental, superficial, or mixed lesions in the proliferative phase, and those located on the tip of nose, neck, perineum, or flexural areas are prone to ulceration and scarring. Large ulcerated infantile haemangiomas are at particular risk of profuse bleeding and secondary bacterial infection.

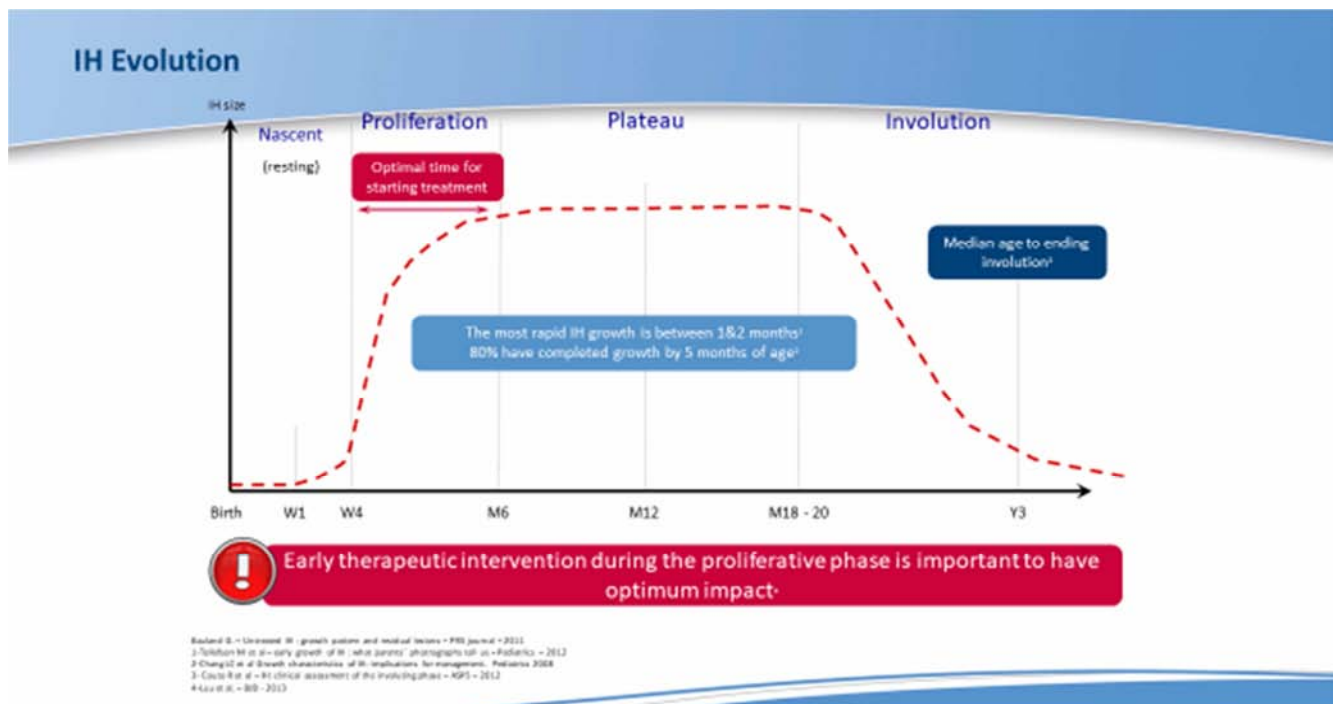


Figure 1. Stages and progression of IH.

## 2. Material and Methods

In the presented clinical observation are included twenty children with a proven diagnosis of infantile haemangioma by a dermatologist. Among these children, treatment is initiated in a daily care out-patient medical center and monitored for a period of 6-9 months, which includes: clinical observation, involution of hemangioma, treatment tolerance and side effects of the therapy.

All children, prior to the initiation of treatment, undertake the following investigations: hematology and biochemical tests, blood glucose, electrocardiogram (ECG) and

cardiology consultation, brain and abdominal ultrasound and also a full clinical examination.

Treatment monitoring include a 2-hour steady-state follow up after the dose administration with clinical examination, blood pressure (BP) measurement, heart rate (HR) and respiratory rate (RR) measurement, oxygen saturation and blood glucose at 0 min and 120 min. The outpatient daily care unit is equipped with all the necessary devices to monitor the treatment and to cope with the side effects of this therapy.

The dose of Propranolol is gradually increased from 1mg/kg/day up to 2-3 mg / kg/day every week, further on the children are followed up for a period of 6 months monthly at a dose of 3 mg / kg /day. [13]. An appropriate photo

documentation and analysis of the results are made.

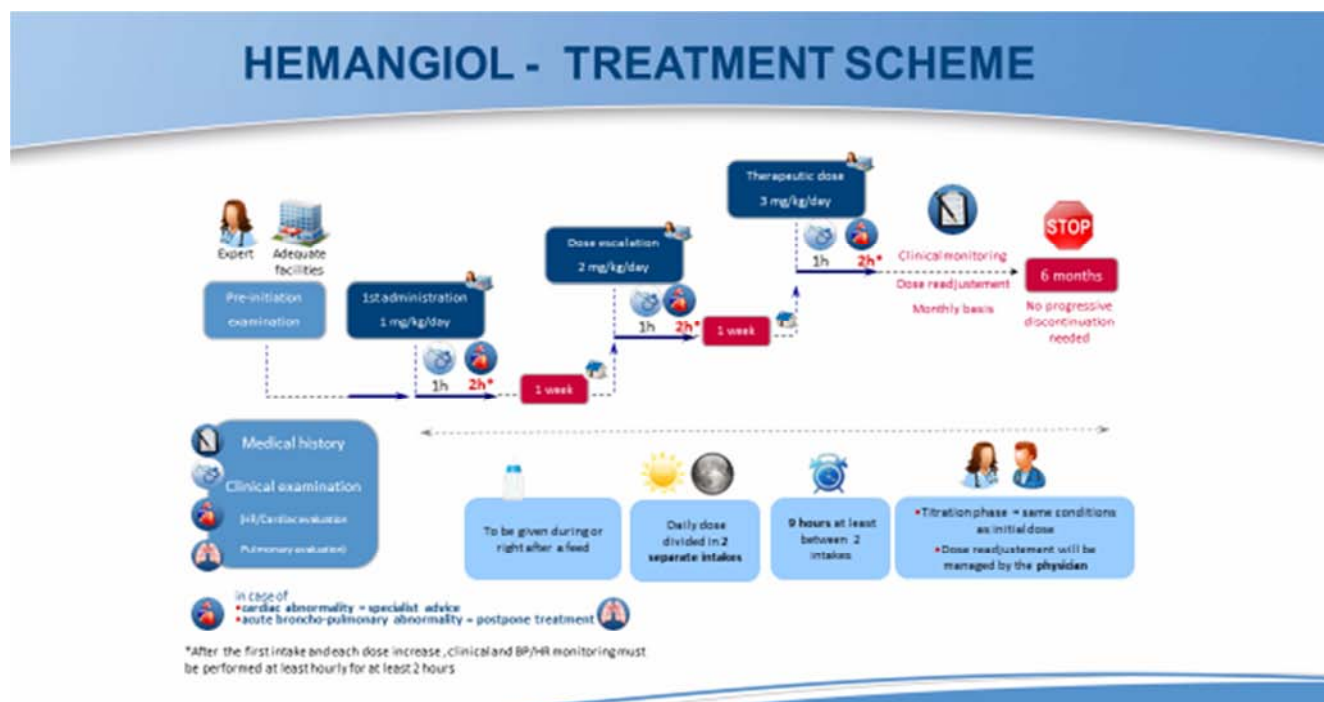


Figure 2. Treatment scheme for Propranolol for IH.

At the First Pediatric Consultative Clinic are observed twenty children for one - year period with a need for systemic therapy (Figure 3).

### 3. Results

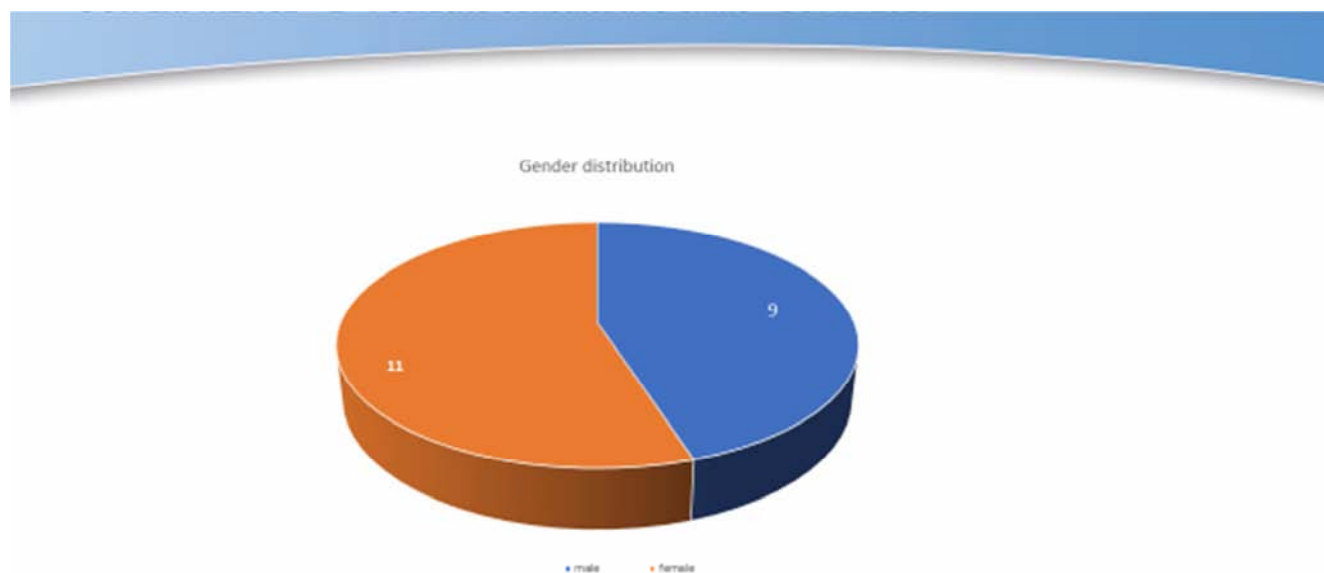
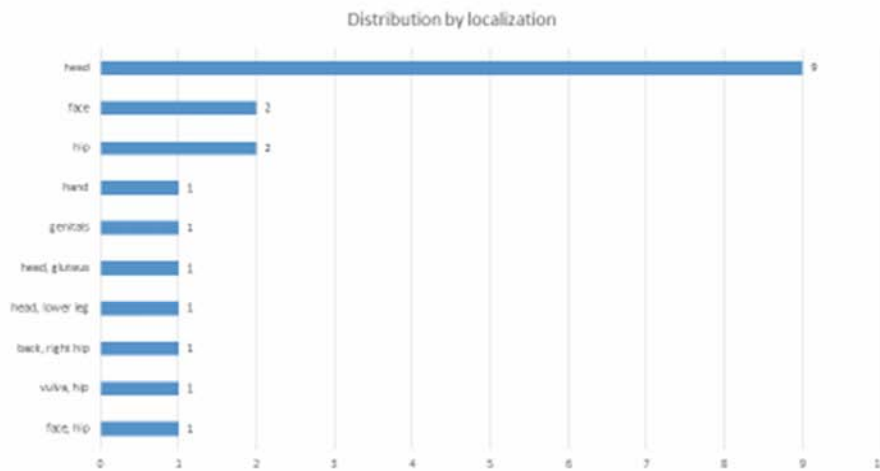


Figure 3. Sex proportion of treated children.

We observe slight domination of the females compared to males in our group. Regarding distribution of hemangiomas most are localized on head and face. Some cases have rare foci: gluteus, vulva etc. (Figure 4).

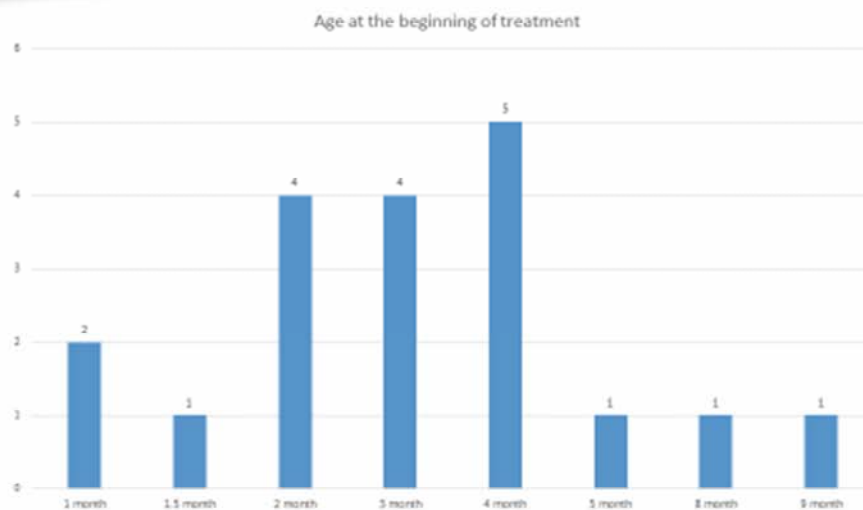
## Distribution by localization



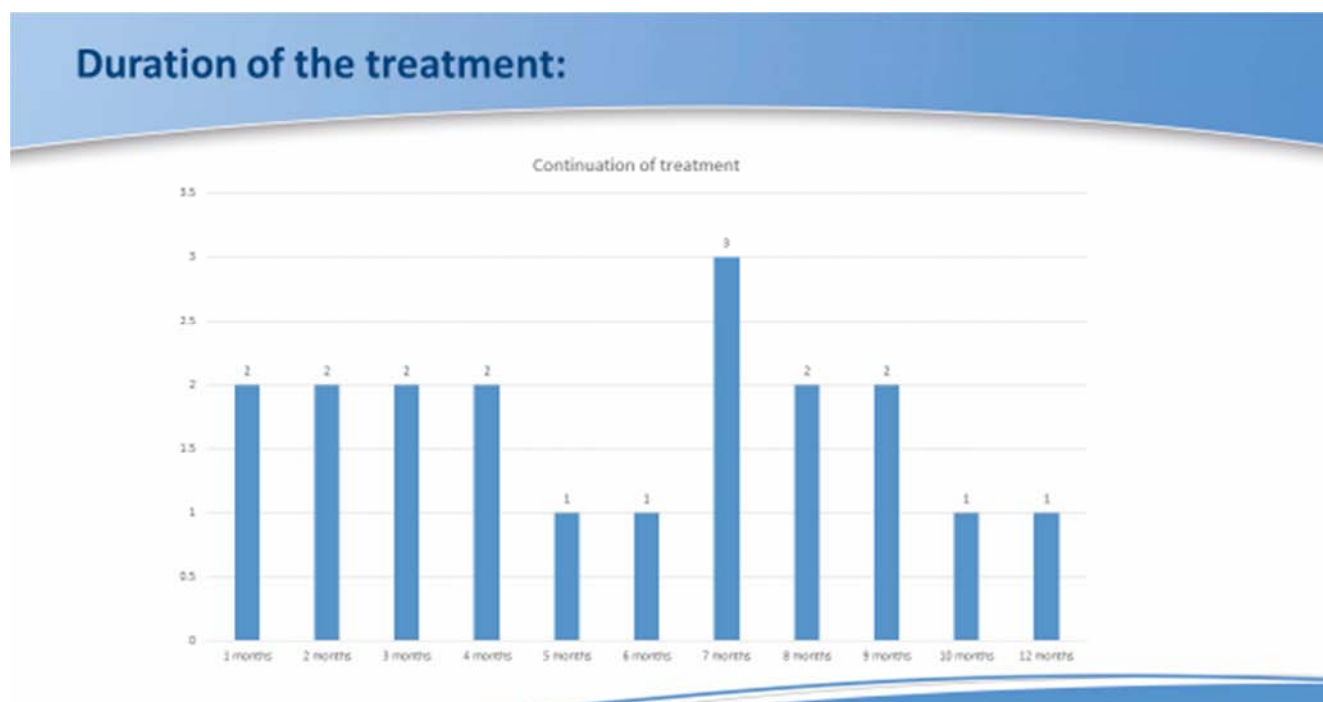
**Figure 4.** Distribution by localization of the IH.

The initial treatment for some patients started from a 5-6 weeks of age, for other – late in the proliferating phase (Figure 5). The duration of the treatment is very variable: between 6-12 months at the dose of 3 mg/kg/day.

## Start of the treatment:



**Figure 5.** Initiation of the treatment.



**Figure 6.** Duration of the treatment.

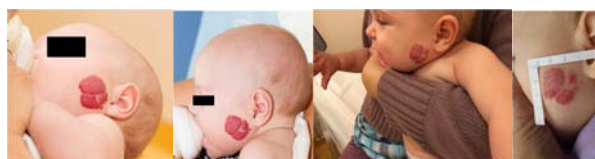We present some of the clinical cases and therapeutic results:

**Clinical case 1:**

A girl at the age of 13 months to date, started therapy at 4 months of age. The child was born from a pathological pregnancy in gestational week 25 with a birth weight of 760g, in depressive condition. Mechanical ventilation was performed for 2 months, surfactant therapy and there was a follow-up clinic of broncho-pulmonary dysplasia (BPD). The child was sent for treatment due to established facial haemangioma with a diameter of 25/30 mm on the left cheek. The patient started therapy with Propranolol 1 mg / kg /day for a weight of 4.66 kg, HR 128 / min, BP 90/60 mmHg, RR 38-40 / min, oxygen saturation 97%. After a week the dose was increased to 2 mg / kg/daily (2x4.8 mg) and after one more week to 3 mg / kg/day at body weight 5.02 kg, HR 126 / min, RR 32 / min, saturation of oxygen 98% and BP 92/60 mmHg.

The haematological parameters of the child, blood sugar at 0 min and 120 min, echocardiography, abdominal echography, ECG did not detect pathological abnormalities. The treatment lasted for 6 months at a dose of 3 mg / kg/day with monthly consultations at the clinic. No side effects of treatment were observed during the indicated period.

After 6 months of treatment, the left cheek haemangioma is almost fused with the skin, faded and flattened (photo-documented).

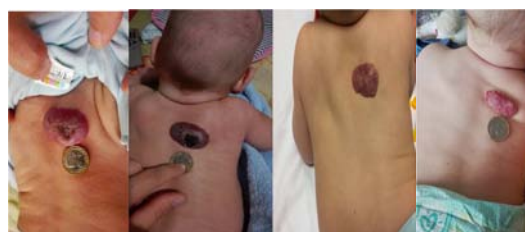

**Figure 7.** Clinical case 1.

**Clinical case 2:**

A boy of 8 months of age to date, who started therapy at 4 months of age. Born from a first pregnancy in gestational week 31 with a BW of 1.9 kg, mechanical ventilation, surfactant therapy. Established haemangioma on the back with size 45/35mm, that is growing and bleeding with superficial necrosis. An additional haemangioma on the right hip. Consulted with a dermatologist and treatment with Propranolol was suggested. The treatment with Propranolol was initiated at a dose of 1 mg / kg/day for body weight 6.3 kg, BP 80/40 mm Hg, HR 132 /min, RR 30 /min, saturation of oxygen 100%, normal haematology results and blood sugar. In a week interval the dose was increased to 2 mg / kg/day and 3 mg / kg/day, which has been adapted monthly to date. No side effects of therapy were seen for the indicated period.

The hemangioma size underwent a significant change in size, surface, discoloration, lack of bleeding and necrosis (photo-documentation is applied).



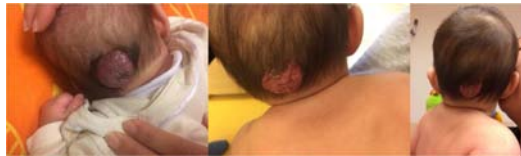**Figure 8.** Clinical case 2.

**Clinical case 3:**

A 7-month-old girl to the current period, who was born with body weight 1.78 kg from the 4-th pathologically pregnancy, born in a depressive condition. After the delivery a hemangioma on the back part of the head was detected by a



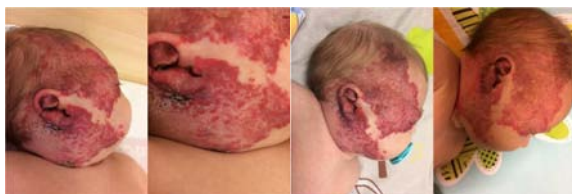dermatologist, who suggested a treatment with Propranolol. Starting therapy at 3 months of age with Propranolol 1 mg / kg/day at body weight 5.5 kg, HR 122 /min, RR 32 /min, BP 80/50 mmHg, 98% oxygen saturation and normal lab results in initialization. The haemangioma was located in the occipital area with 30/30 mm size in diameter and cavernous appearance, with no bleeding. In a week interval the dose was increased to 2 mg / kg/day and 3 mg / kg/daily with excellent tolerance. On the last dose of Propranolol, the child is already in its third month of treatment without any side effects and a good therapeutic response: the hemangioma is smaller in size, flattened and discolored (photo documentation is applied).



**Figure 9.** Clinical case 3.

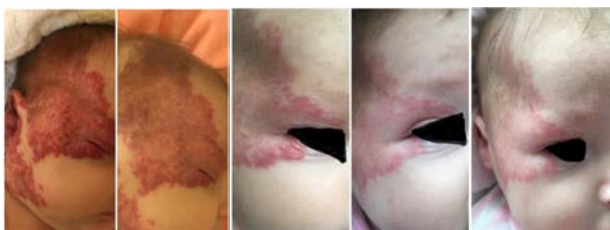#### Clinical case 4:

One of the most difficult cases: giant facial hemangioma with laryngeal stridor and complicated start of the treatment. A 2-month-old girl to the current period, who was born with body weight 2.6 kg from the 1-sh normal pregnancy, born in a depressive condition. After the delivery a hemangioma on the face was detected by a neonatologist. The treatment with Propranolol was suggested. Starting therapy at the age of 2.5 months of age with Propranolol 1 -2-3 mg / kg/day. The child has a giant face hemangioma, necrosis of the right external ear, also laryngeal stridor, which lead to more difficult management of the therapy. The child was treated more than 18 months with a very good result.



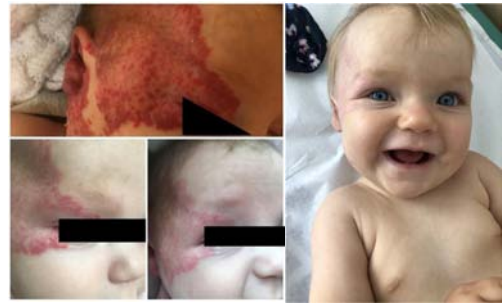**Figure 10.** Case 4- initial treatment.

After the treatment initiation at the dose of 1-2-3 mg/kg/day with excellent effect.



**Figure 11.** Clinical case 4.

Case 4 – recent situation:



**Figure 12.** Clinical case 4.

## 4. Conclusion

Treatment of IH should be individualized, depending upon the size, rate of growth, morphology, number, and location of the lesion, existing or potential complications, benefits and adverse events associated with the treatment, age of the patient, level of parental concern, and the physician's comfort level with the various treatment options. Currently, oral propranolol is the treatment of choice for high-risk and complicated infantile hemangiomas.

We demonstrate an excellent clinical effect of oral Propranolol for the treatment of infantile hemangiomas and the ability to start and monitor this therapy in outpatient clinics with a well-trained team. The collaboration between a pediatrician and dermatologist are extremely important and also a well-trained nurse with a practical experience in management of infantile hemangiomas.

## References

- [1] Metry DW, Hebert AA. Benign Cutaneous vascular tumors of infancy. When to worry, what to do. Arch Dermatol 2000; 136: 905-14.
- [2] Frieden IJ, Eichenfield LF, Esterly NB, Geronemus R, Mallory SB. Guidelines of care for hemangiomas of infancy. J Am Acad Dermatol 1997; 37: 631-7.
- [3] Werner J, Dunne A, Lippert B, Folz B. Optimal treatment of vascular birthmarks. Am J Clin Dermatol 2003; 4: 745-56.
- [4] Garzon MC, Frieden IJ. Hemangiomas: When to worry. Pediatr Ann 2000; 29: 58-67.
- [5] Drolet BA, Esterly NB, Frieden IJ. Hemangiomas in children. N Engl J Med 1999; 341: 173-81.
- [6] Enjolras O, Gelbert F. Superficial hemangiomas: Association and management. Pediatr Dermatol 1997; 14: 173-9.
- [7] Frieden IJ, Reese V, Cohen D. PHACE syndrome. Arch Dermatol 1996; 132: 307-11.
- [8] Metry DW, Dowd CF, Barkovich AJ, Frieden IJ. The many faces of PHACE syndrome. J Pediatr 2001; 139: 117-23.
- [9] Tanner JL, Dechert MP, Frieden IJ. Growing up with a facial hemangioma: parent and child coping and adaptation. Pediatrics 1998; 101: 446-83.

- [10] Enjolras O, Riche MC, Merland JJ, Escande JP. Management of alarming hemangiomas in infancy: a review of 25 cases. *Pediatrics* 1990; 85: 491-8.
- [11] Special symposium. Management of hemangiomas *Pediatr Dermatol* 1997; 14: 57-83.
- [12] Frieden IJ, Haggstrom AN, Drolet BA, Mancini AJ, Friedlander SF, Boon L. Infantile hemangiomas: current knowledge, future directions: Proceedings of a research workshop on infantile hemangiomas, April 7-9, 2005, Bethesda, Maryland, USA. *Pediatr Dermatol* 2005; 22: 383-406.
- [13] Llaüt-Labròze C, Dumas de la Roque E, Hubiche T, Boralevi F, Thambo J B, Taoeb A. Propranolol for severe hemangiomas of infancy. *N Engl J Med* 2008; 358: 2649-2652.
- [14] Fernández Faith E, Shah S, Witman PM, Harfmann K, Bradley F, Blei F, Pope E, Alsumait A, Gupta D, Covelli I, Streicher JL, Cotton C, Tollefson M, Nguyen H, Hunt R, Moore-Clingenpeel M, Frieden IJ - Clinical Features, Prognostic Factors, and Treatment Interventions for Ulceration in Patients With Infantile Hemangioma. *JAMA Dermatol.* 2021 May 1; 157 (5): 566-572. doi: 10.1001/jamadermatol.2021.0469.PMID: 33787840.
- [15] Tiemann L, Hein S. Infantile Hemangioma: A Review of Current Pharmacotherapy Treatment and Practice Pearls. *J Pediatr Pharmacol Ther.* 2020; 25 (7): 586-599. doi: 10.5863/1551-6776-25.7.586.PMID: 33041713.
- [16] Rachel A. Giese, Merit Turner, Mario Cleves, J. Reed Gardner, et al. Propranolol for Treatment of Infantile Hemangioma: Efficacy and Effect on Pediatric Growth and Development, *Int J Pediatr.* 2021; 2021: 6669383. Published online 2021 Apr 7.