

# Hoffmann Syndrome, Manifestation of Hypothyroidism: Case Report

Asmell Ramos Cabrera<sup>1</sup>, Alexis Culay Perez<sup>2</sup>, Yamila Rodriguez Sanchez<sup>2</sup>,  
Alexis Gregori Caballero<sup>2</sup>

<sup>1</sup>Internal Medicine Department, American International University West Africa, Banjul, Gambia

<sup>2</sup>Internal Medicine Department, Manuel Ascunce D teaching Hospital, Camaguey, Cuba

## Email address:

asmellramos@gmail.com (A. R. Cabrera)

## To cite this article:

Asmell Ramos Cabrera, Alexis Culay Perez, Yamila Rodriguez Sanchez, Alexis Gregori Caballero. Hoffmann Syndrome, Manifestation of Hypothyroidism: Case Report. *International Journal of Science, Technology and Society*. Vol. 6, No. 6, 2021, pp. 88-90.  
doi: 10.11648/j.ajlm.20210606.12

**Received:** June 6, 2021; **Accepted:** July 7, 2021; **Published:** November 23, 2021

**Abstract:** Hoffmann syndrome is defined since 1897 as the combination of hypothyroidism with myopathy, mioedema, rigidity, muscle cramps, and hypertrophy. The objective of this publication is to describe a typical case of thyroid disease with clinical, hormonal, and muscular characteristics of a Hoffmann syndrome, as an exceptional manifestation of hypothyroidism. The clinical challenge consisted in linking the apparent ambiguity of the clinical symptoms such as: generalized weakness, fatigue, muscle cramps in a young patient, without personal record of previous disease, apparently healthy and well-nourished with favorable muscle development. Additionally, manifestation of pituitary gland dysfunction was found, such as headache and galactorrhea, bibliography reviewed showed mainly, male patients pater and not any comment concerning hypophysis impairment. all clinical manifestations disappeared after replacement treatment with levothyroxine, including the goiter and pituitary macroadenoma. The management of the case involved a multidisciplinary team and involved internists, cardiologist, endocrinologists, radiologist, and neurosurgeons. This form of thyroid myopathy is rare and usually accompanies adult patients with severe and long-standing hypothyroidism, is different from those that begin in early childhood and are associated with cretinism and muscle hypertrophy.

**Keywords:** Hoffmann Syndrome, Hypothyroidism, Myopathy

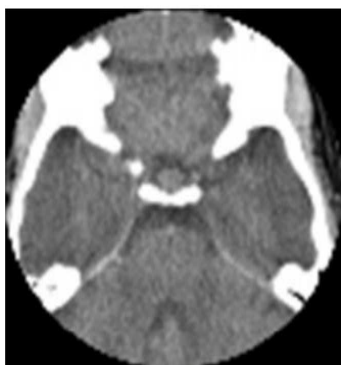## 1. Introduction

Hoffman in 1897, [1] describes a syndrome characterized by pain and muscle spasms associated with mioedema with increased muscle masses in hypothyroid patients, as is also reported in infants with cretinism and large growth of muscle groups known as Hercules children another similar association. [2] Then the Kocher-Debré-Semelaigne syndrome is named, [3-6] maintains as the main differences with respect to Hoffmann the age of debut, the absence of painful spasms and myotonias. Among the multiple clinical manifestations, hypothyroidism is accompanied by muscular symptoms. Myopathy associated with hypothyroidism can be divided into four subtypes: Kocher-Debré-Semelaigne syndrome, Hoffmann syndrome, atrophic form and myasthenic syndrome. [7] The clinical presentation is diverse, from an asymptomatic

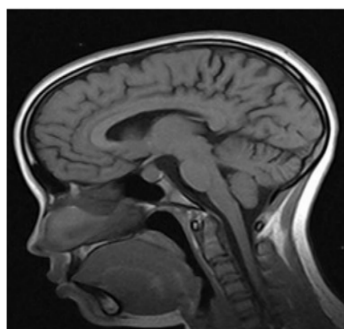
form to a multisystemic compromise such as: cold intolerance, decreased sweating, hoarseness, paresthesia's, constipation, weakness, fatigue, dry and rough skin. [8]

The propose of this presentation is to describe a rare presentation of hypothyroidism. A 16-year-old white female patient with a previous health history, six months before admission she began to present asthenia, increased with exercise, then muscle aches appear in the shoulder and pelvic girdles, becoming more intense in the thighs; sometimes accompanied by intense muscle spasms, which relieved after rest. These episodes increased in severity and frequency until ambulation was prohibited due to the severity of weakness. Admission at the Internal Medicine department of the Dr. Octavio de la Concepción was decided. During the interview mentioned galactorrhea and menstrual irregularities. Physical examination showed good physical constitution and virtuous muscular development as established by the Central

Recruitment Commission of the Cuban army. She presented pale skin and mucosa, diffuse alopecia, and a slight increase in thyroid volume (30-35g) that was seen to be multinodular, according to the endocrinologist's review. Adequate muscle tone and trophism, with inability to squat or stay for more than three minutes in the standing position and achillean tendon hyporeflexia. No other alterations were found on physical examination.



**Figure 1.** Computerized axial tomography (CT) of the skull (simple) described pituitary Macro adenoma.



**Figure 2.** Magnetic resonance imaging No 2755: enlarged sella turcica, occupied by an isointense image of the pituitary gland in T1 and T2, measuring 20 mm in greater diameter; with the appearance of a macro adenoma.

#### Analytical studies:

Hematocrit: 0.27 vol / L. Hemoglobin: 82 g / L. Leukogram:  $10.0 \times 10^9$  / L.

Blood glucose: 3.8 mmol / L.

Creatinine: 113  $\mu$ mol.

Aspartate aminotransferase (ASAT): 128 U / L. Creatine phosphokinase (CPK): 2 456 U / L.

Lactate dehydrogenase (LDH): 918 U / L.

Calcium (blood): 0.93 mmol / L.

Systemic lupus erythematosus (SLE) cells: negative. Erythro sedimentation (ESR): 16 mm / h.

Circulating immune complexes (ICC): 0.06.

Thyrotropin hormone (TSH): 100  $\mu$ IU / L (Vn 0.27-3.75). Free thyroxine (T4): 1.09 nmol / L (Vn 55-155). Free triiodothyronine (T3): 0.38 nmol / l (Vn 1.4-3.27).

Prolactin: 1467 nmol / L. Luteinizing hormone (LH): 0.38 IU / L.

Follicle Stimulating Hormone (FSH): 3.63 IU / L (blood drawn on the third day of the menstrual cycle).

Neurophysiological tests (Pediatric Specialties Polyclinic).

Surface Electromyography (EMG): Normal Spasmophilia test: Normal.

Stress ECC test: Result equivalent to a New York Heart Association (NYHA) Class III – IV Heart Failure Functional Classification with a functional capacity of 42 and myocardial oxygen consumption = 18.

Thyroid ultrasound: nodular tendency irregular echogenicity, 4mm isthmus, 13 x 15 x 35mm right lobe, 15 x 15 x 35mm left lobe with small 2mm calcification.

Thyroid fine needle aspiration cytology (CAAF): Negative of neoplastic cells.

## 2. Discussion

An interesting element is that despite the fact that hypothyroidism is more frequent in females than in males, all the reports found outside and within the country were men, other aspects in which there was no coincidence were in relation to pseudo hypertrophy, since Although the young woman was athletic, it cannot be said that there was pseudo hypertrophy; Apparently one of our findings was the increase in pituitary volume, which returned to normal together with the disappearance of galactorrhea and menstrual irregularities after replacement therapy with thyroid hormones.

Thyroid enlargement and symptoms and signs suggestive of hypothyroidism are verified, which is confirmed after measures of thyrotropin (TSH), thyroxine (T4) and triiodothyronine (T3) values. Hoffmann syndrome is diagnosed and treatment with levothyroxine sodium (0.1 mg tablet daily) started, a total regression of the clinical picture after six months with disappearance of anemia, menstrual disorders, weakness, and manifestations muscle in addition of a normal hormonal pattern. Hypothyroidism, among the multiple clinical manifestations that it presents at different levels of the body, is accompanied by muscle symptoms, characterized by muscle weakness, which becomes a true hypothyroid myopathy mainly at late stages, [9] what is infrequent is that muscle involvement is the form of initial presentation of hypothyroidism and rarer still in a young woman. [10] There are few international reports of them and practically nil in our country, Arpa Gámez A and González Soto longo [11] is the only reference found. In the patient studied, marked asthenia was important clinical elements, which is practically considered a requirement in the diagnosis of decompensated hypothyroidism to the point that more than 90% of hypothyroid people present the clinical characteristics of asthenia due to thyroid hypofunction. [12-14]

Other elements were muscle pain, mostly affecting large proximal groups, achillean osteotendinous areflexia, thyroid enlargement and involuntary muscle contractions in a young patient with an apparent history of health and stigmas of endocrine dysfunction due to anemia, disorders menstrual and galactorrhea. [14, 15] The high increased muscle enzymes, in a patient with suspected muscle disease and goiter, oriented the diagnosis towards a thyroid disease, which was confirmed with alterations in TSH, T4 and T3. Neurophysiology studies are not specific or relevant in these

cases due to the variable results. [14]

A muscle biopsy was not performed as it was not necessary for the diagnosis and had little specificity in these cases, which was consistent with other investigations. [14-16] The pathogenesis of hypothyroid myopathy is not yet fully understood. Thyroxine deficiency has been suggested to lead to abnormal glycogenolysis and metabolic disorders in mitochondrial and lipid oxidative metabolism, impairing muscle function. Muscle biopsies performed show nonspecific changes. Hormone replacement quickly reverses both the symptoms and the enzymatic changes, which is enough to reach the diagnosis without the need for an electromyographic study (usually normal or with a slightly myopathic pattern), or muscle biopsy in most of the patients. [17]

### 3. Conclusions

The approach to a patient with ambiguous symptoms with included encompasses multisystem involvement is a daily challenge for internist and requires a detailed interview, deep medical examination, and appropriate use of clinical method, furthermore engagement a multidisciplinary team to ensure holistic approach with the aim of trying to explain the plethora of symptoms and signs just only through a single disease. The presented case constitutes a typical clinical picture of Hoffmann syndrome presentation as a rare endocrine / muscular disorder secondary due to a primary thyroid hormone deficiency. The spectacular response to thyroid hormone replacement therapy and the complete recovered of the endocrine axis with total restitutio ad integrum of the endocrine axis function was the best achievement.

### References

- [1] Hoffmann J. Weiterer Beitrag zur Lehre von der Tetanie. Dtsch Z Nervenheilk. 1897; 9: 278-90.
- [2] Lee KW, Kim SH, Kim KJ, Kim SH, Kim HY, Kim BJ, et al. A Rare Manifestation of Hypothyroid Myopathy: Hoffmann's Syndrome. Endocrinol Metab [Internet]. 2015 Dec [cited 12 Mar 2019]; 30 (4): [approx. 5 p.]. Available at: <https://www.ncbi.nlm.nih.gov/pmc/articles/PMC4722421/>
- [3] Senanayake HM, Dedigama AD, De Alwis RP, Thirumavalavan K. Hoffmann syndrome: a case report. Int Arch Med [Internet]. 2014 [cited 12 Mar 2019]; 7: [approx. 2 P.]. Available at: <https://www.ncbi.nlm.nih.gov/pmc/articles/PMC3895824/>
- [4] Dudekula A, Fernandes M, Mahale A, Sharma H. Hoffmann Syndrome: An Unusual Cause of Proximal Muscle Hypertrophy. Res J Radiol [Internet]. 2017 [cited 2018 Jul 12]; 4 (1): [approx. 4 p.]. Available at: <https://scialert.net/fulltextmobile/?Doi=rjr.2017.1.4>
- [5] Rábano Gutiérrez del Arroyo J, Gobernado Serrano JM, García Villanueva M, Gimeno Álava A. Hypothyroidism with muscular hypertrophy (Hoffmann syndrome): histochemical, histometric and ultrastructural study of skeletal muscle. Med Clin Barc. 1984; 82 (3): 121-3.
- [6] Domínguez Gasca LG, Arellano Aguilar G, Domínguez Carrillo LG. Hypothyroid pseudohypertrophic myopathy: Hoffmann syndrome. Acta Médica Grupo Ángeles [Internet]. 2015 [cited 2019 Mar 12]; 13 (1): [approx. 4 p.]. Available at: <http://www.medigraphic.com/pdfs/actmed/am-2015/am151e.pdf>
- [7] McKeran RO, Slavin G, Ward P, Paul E, Mair W. Hypothyroid myopathy. A clinical and pathological study. J Pathol. 1980 Sep; 132 (1): 35-54.
- [8] Seclén Santisteban S. Hypothyroidism in the elderly. Diagnosis (Peru) [Internet]. Jul-Ago 2003 [cited 2019 Mar 12]; 42 (4): [approx. 2 p.]. Available at: <http://www.fihudiagnostico.org.pe/revista/numeros/2003/julago03/171-172.html>
- [9] Duyff RF, Van den Bosch J, Laman DM, Van Loon BJ, Linszen WH. Neuromuscular findings in thyroid dysfunction: A prospective clinical and electrodiagnostic study. J Neurol Neurosurg Psychiatry [Internet]. 2000 Jun [cited 12 Mar 2019]; 68 (6): [approx. 6 p.]. Available at: <https://www.ncbi.nlm.nih.gov/pmc/articles/PMC1736982/pdf/v068p00750.pdf>
- [10] Jameson JL, Weetman AP. Thyroid gland disorders. In: Fauci A, Braunwald E, Kasper D, Hauser S, Longo D, Jameson J, editors. Harrison's Principles of Internal Medicine. 18 ed. New York: McGraw-Hill; 2012. p. 2911-2939.
- [11] Arpa Gámez A, González Sotolongo O. Hoffmann's syndrome. Rev Cub Med Mil [Internet]. Dec 2002 [cited 2019 Mar 12]; 31 (4): [approx. 3 p.]. Available at: [http://scielo.sld.cu/scielo.php?script=sci\\_arttext&pid=S0138-65572002000400013&lng=en](http://scielo.sld.cu/scielo.php?script=sci_arttext&pid=S0138-65572002000400013&lng=en)
- [12] Peioxoto Kades MG, Silvano de Aquino ME, Pereira de Souza L. WerdnigHoffman syndrome: pathological aspects and knowledge of the disease. Recien Magazine [Internet]. 2017 [cited 2019 Mar 12]; 7 (20): [approx. 8p.]. Available at: [https://www.recien.com.br/index.php/Recien/article/download/224/pdf\\_1http://revistaamc.sld.cu/](https://www.recien.com.br/index.php/Recien/article/download/224/pdf_1http://revistaamc.sld.cu/)
- [13] Saïd F, Tliba A, Khanfir M, Lamloum M, Habib Houman M. [Hoffmann syndrome about two new cases]. Rev Med Brux. 2018; 39 (3): 172-17.
- [14] Regal Ramos RJ. Fibromyalgia: hypothyroidism or persistent somatoform pain disorder. Med Gen Fam [Internet]. 2016 Oct-Dec [cited 12 Mar 2019]; 5 (4): [approx. 5 p.]. Available at <https://www.sciencedirect.com/science/article/pii/S1889543316000335>
- [15] Angelini C. Endocrinological Myopathies. In: Angelini C, editor. Acquired Neuromuscular Disorders: Pathogenesis, Diagnosis and Treatment. Switzerland: Springer International Publishing; 2016. p. 143-54.
- [16] Chung J, Ahn K-S, Kang CH, Hong S-J, Kim BH. Hoffmann's disease: MR imaging of hypothyroid myopathy. Skeletal Radiology [Internet]. 2015 [cited 2018 Jul 12]; 44 (11): [approx. 10 p.]. Available at: <https://link.springer.com/article/10.1007%2Fs00256-015-2226-1>
- [17] García Sainz-Pardo C, Morales Moreno L, Tardío López M, Sáez Martínez FJ. Hypothyroid myopathy. Med Gen and Fam [Internet]. Mar 2012 [cited 12 Mar 2019]. Available at: [http://www.mgyf.org/wpcontent/uploads/2017/revistas\\_rantes/V1N1/V1N1\\_54\\_56.pdf](http://www.mgyf.org/wpcontent/uploads/2017/revistas_rantes/V1N1/V1N1_54_56.pdf)