

Malignant Peripheral Nerve Sheath Tumour with Heterologous Differentiation: A Case Report

Rasheed Mumini Wemimo^{1,*}, Afolayan Enoch Abiodun², Jatto Hamza Ibrahim³, Adekunle Adebayo Ayoade⁴, Atiku Hafiz⁵, Odetayo Omolara Foluke⁶

¹Department of Anatomic Pathology, Federal Medical Centre, Birnin Kudu, Nigeria

²Department of Pathology, University of Ilorin Teaching Hospital, Ilorin, Nigeria

³Department of Surgery, Federal Medical Centre, Birnin Kudu, Nigeria

⁴Department of Morbid Anatomy and Histopathology, Ladoke Akintola University of Technology, Ogbomosho, Nigeria

⁵Department of Radiology, Federal Medical Centre, Birnin Kudu, Nigeria

⁶Department of Radiology, Olabisi Onabanjo University Teaching Hospital, Sagamu, Nigeria

Email address:

muminirasheed265@gmail.com (R. M. Wemimo)

*Corresponding author

To cite this article:

Rasheed Mumini Wemimo, Afolayan Enoch Abiodun, Jatto Hamza Ibrahim, Adekunle Adebayo Ayoade, Atiku Hafiz, Odetayo Omolara Foluke. Malignant Peripheral Nerve Sheath Tumour with Heterologous Differentiation: A Case Report. *American Journal of Laboratory Medicine*. Vol. 7, No. 2, 2022, pp. 32-36. doi: 10.11648/j.ajlm.20220702.13

Received: March 4, 2022; **Accepted:** March 28, 2022; **Published:** April 20, 2022

Abstract: Malignant peripheral nerve sheath tumour is one of the rare soft tissue tumours in the younger age group. The tumour arises from peripheral nerves with a predominant lesion on the extremities or limbs, head and neck, and trunk. It can arise de novo also known as sporadic or in patients with neurofibromatosis type 1. It is an infiltrative, aggressive tumour with a high rate of recurrence and metastases. The microscopic examination of both NF1 gene-associated and sporadic MPNST are similar but different prognoses aided and abetted by other co-morbid factors or disease conditions. Histologic examination of the surgically resected specimen is the goal standard for diagnosis with an ancillary test comprising immunostaining of the tumour cells. This tumour has the propensity to undergo diverse differentiation towards osseous, chondroblastic, and rhabdomyoblastic cells. The rhabdomyoblastic differentiation is strongly associated with a poor prognosis. Thus, creating a diagnostic challenge for general pathologists and pathologists in the trainee. The specific cause of this tumour is not known but is strongly linked to Neurofibromatosis type 1 in a few groups of patients with multiple cutaneous plexiform neurofibromas which are not concordant with the index case. We, therefore, present a sporadic subcutaneous MPNST with heterologous differentiation comprising rhabdomyoblastic cells, chondroblast, and osseous in a 15-year-old woman.

Keywords: Malignant Peripheral Nerve Sheath Tumour (MPNST), NF: Neurofibromatosis, Haematoxylin, Eosin (H&E)

1. Introduction

Malignant Peripheral Nerve Sheath Tumor is a malignant neoplasm that can arise De novo from a peripheral nerve or in the background of NF1 neurofibroma. The de novo development of the tumour is also known as sporadic Malignant Peripheral Sheath Tumour (MPNST) which could be seen in the age group but most often in the older age bracket. [1].

Patients with NF1 associated MPNST experience the

development of MPNSTs at earlier ages and account for the majority of cases. NF 1 gene is a tumour suppressor gene on chromosome 17 which encodes a protein product called neurofibromin homologous to the GAP protein that influences cell cycling by down-regulating the p21 RAS gene. [2, 3].

The NF1 mutation accounted for Neurofibromatosis type 1 which is otherwise known as Von Recklinghausen disease characterized by at least 2 of the following clinical

manifestation: 6 or more café-au-lait macules > 5 mm (prepubertal) or > 15 mm (post-pubertal), 2 or more neurofibromas or one plexiform type Freckling in the axillary or inguinal regions, Optic glioma 2 or more Lisch nodules (iris hamartomas) Distinctive osseous lesion (e.g sphenoid dysplasia or long-bone cortical thinning with or without pseudarthrosis) and a first-degree relative with neurofibromatosis type 1.[2, 3].

The NF1 associated MPNST usually arises from plexiform neurofibroma. The histological features of this tumour are similar regardless of sporadic origin or NF1 associated which is often characterized by highly infiltrative and invasive growth of tumour cells comprising spindle-shaped cells arranged in fascicles in most cases, increased cellularity, mitotic figures, necrosis, and pleomorphic appearance of the tumour cells. This tumour occasionally demonstrates divergent differentiation towards rhabdomyoblastic cells, chondroblast, lipomatous, and or osseous with designated nomenclature called Malignant Triton Tumour. [2]

MPNST is also known as malignant schwannoma or neurosarcoma, however, the most preferred and widely acceptable nomenclature is Malignant Peripheral Nerve Sheath Tumour.

The geographic distribution of this tumour varies widely around the world in the developed as well as developing countries among different races and regions but is said to have accounted for approximately 5-10% of malignant soft tissue sarcoma with about 8-15% occurring in the head and neck. The exact etiology of this tumour is unknown but genetic and environmental factors play an important role. [4-7].

The affected patients usually present with painless enlarging or painful mass with rapid growth in a preexisting nerve sheath tumor in NF1 patients that might suggest malignant transformation or neurogenic symptoms (e.g., weakness, tingling sensation) in some patients [8]. However, sporadic MPNST usually presents as rapid diffuse subcutaneous mass with infiltrative edges.

Grossly, it is described as a fusiform or globular tumour mass with adherent soft tissue if resected en bloc whereas incisional biopsy will be firm to hard, tan white, and irregularly shaped with spiculated edges. The cross-section is gelatinous to fleshy with areas of necrosis and hemorrhage. Histologically, it is a malignant tumour composed of proliferating spindle-shaped tumour cells in the majority of cases arranged in broad fascicles alternating zones of hypercellular and hypocellular areas reminiscent of a marbled pattern. A few of the tumour cells show an epithelioid appearance. There may be geographic necrosis with perivascular sparing known as (the "peritheliomatous" pattern). Heterologous mesenchymal differentiation of the MPNST has been reported in 10-15% of cases showing rhabdomyoblastic (malignant triton tumor), Osteosarcomatous, chondrosarcomatous, angiosarcomatous, and liposarcomatous. [7].

The spindle-shaped MPNST tumour cells usually show focal immunoreactivity with S100 whereas epithelioid MPNST often demonstrate diffuse positivity for S100

antibody.

The majority of MPNST occurs in the fourth to the fifth decade, NF1 mutated gene neurofibroma in patients with neurofibromatosis, and few reported cases of sporadic MPNST. However, we present a case report of sporadic MPNST with heterologous differentiation in a 15-year-old woman.

2. Case Report

A 15-year old woman presented to our clinic with a 4-month history of left forearm painless swelling that has been progressively increasing in size with no associated itching or discharge. There is no history of trauma or radiation exposure and no mass lesion in any other part of the body. There is no personal history of cutaneous neurofibroma or family history of multiple neurofibromas or plexiform neurofibroma. On examination, a circumferential mass measures 9.8.0cmx8.0cm involving the middle part of the left forearm, firm to hard in consistency with no limitation of joint movement. She had tumour debulking with residual tumour morbidly adherent to the radial artery. X-ray of the mass with lateral view showed soft tissue mass involving the left forearm with periosteal sclerosis and soft tissue swelling. There is no bony lesion seen. The biopsy was sent in 10% neutral buffered formalin for histological analysis with an accompanying request form. The surgeon's diagnosis of neurofibrosarcoma was entertained. The specimen was grossed with the following description details: Received fragmented pieces of soft to firm, irregularly shaped specimens of varying sizes and weighs 150gram. The largest measures 9.2x4.6x1.2cm while the smallest measures 1.0x1.0x0.5cm. The cross-section is solid and grey and white. The specimen was subsequently processed with 10% neutral buffered formalin, the graded concentration of alcohol, xylene, and molten paraffin wax impregnation. The specimen was embedded to generate paraffin-embedded tissue blocks and further subjected to microtomy. The 3 micrometer thin sections were generated during microtomy, folds removed with 10% alcohol, water bath, and further stained with haematoxylin and eosin. H&E: The microscopic examination of the H&E stained section shows malignant mesenchymal neural tumours arranged in solid sheets and peritheliomatous patterns. The cells are large, round to polygonal with marked nuclear pleomorphism, increased nuclear-cytoplasmic ratio, few dispersed chromatin patterns, prominent nucleoli, and scanty cytoplasm. A few of the cells are spindle-shaped with hyperchromatic nuclei and scanty cytoplasm. There are numerous multinucleated and uninucleated tumour giant cells. There are 3 atypical mitoses at 10hpf. There are areas of infiltration of skeletal muscles and subcutaneous adipose tissue. There are areas of heterologous tumour differentiation comprising rhabdomyoblastic, osseous, and cartilaginous differentiation. The histological diagnosis of Malignant Peripheral Nerve Sheath Tumour with heterologous differentiation such as osseous, chondroblastic, and rhabdomyoblastic cells was made.

3. Ethical Issues

This case report was conducted in compliance with the guidelines of the Helsinki declaration on biomedical research in human subjects. Confidentiality of the patient and personal health information was maintained.



Figure 1. X-ray of the mass with lateral view shows soft tissue mass involving the left forearm with periosteal sclerosis and soft tissue swelling. There is no bony lesion seen.

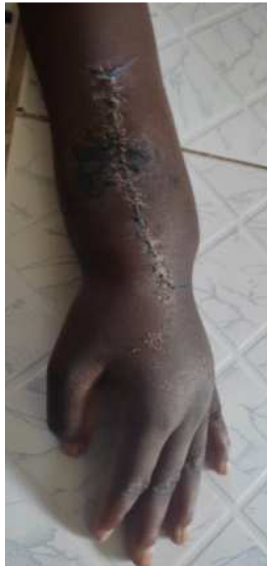

Figure 2. Post-surgical photomicrograph showed longitudinal recent surgical scar with edges well apposed by sutures.



Figure 3. Macroscopic feature of the specimen composed of fragments of tan white, irregular shaped, firm to hard weighs 150g. The largest measures 9.2x4.6x1.2cm while the smallest measures 1.0x1.0x0.5cm. The cross-section is solid and grey white.

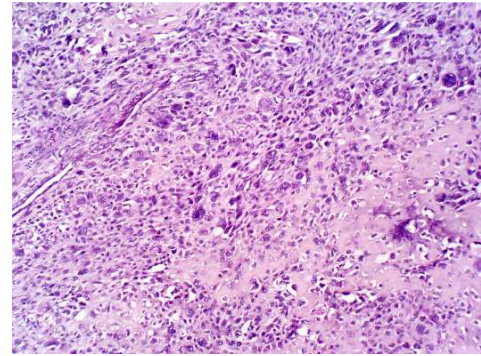


Figure 4. Sections show malignant mesenchymal neural tumours arranged in solid sheets and admixed with uninucleated and multinucleated tumour giant cells. The cells are large, round to polygonal with marked increased nuclear-cytoplasmic ratio, few dispersed chromatin patterns, prominent nucleoli, and scanty cytoplasm.

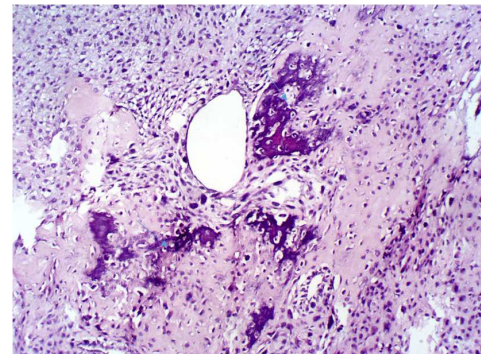


Figure 5. Section of the malignant peripheral nerve sheath tumour with osseous differentiation as depicted by an arrow.

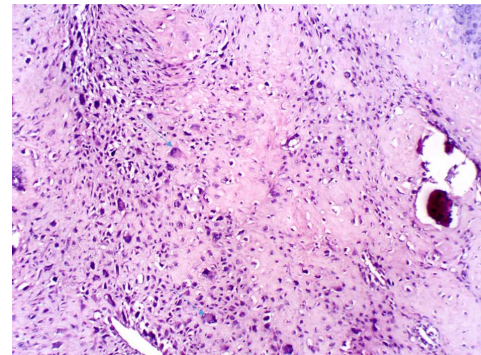


Figure 6. Section of the malignant peripheral nerve sheath tumour with rhabdomyoblastic differentiation as demonstrated with an arrow.

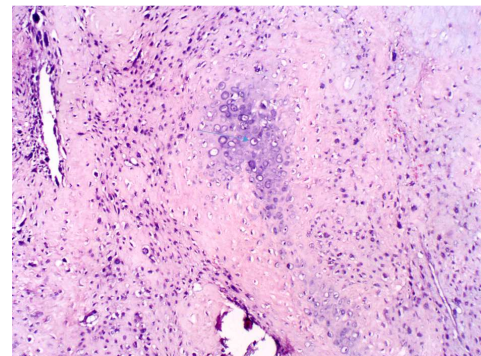


Figure 7. Section of the malignant peripheral nerve sheath tumour with chondroblastic differentiation is shown with an arrow.

4. Discussion

The Malignant Peripheral Nerve Sheath Tumour (MPNST) is a high-grade neoplasm that occurs in a patient with neurofibromatosis type 1 which is often associated with greater morbidity and mortality in comparison with sporadic MPNST. It arises from peripheral nerve or extraneuronal soft tissue with nerve sheath differentiation. The tumour can metastasize to the lymph node, bone, and other organs of the body. The age and site distribution of the MPNST varies widely among different socioeconomic groups and between developing and developed countries. It is rare cancer with an overall incidence of 0.001%. [9]

MPNST may arise at any age with no gender predilection, it tends to present earlier in life in patients with NF1 gene mutation whereas sporadic MPNST occurs between the second decade and six decades years. The NF1-associated MPNST is between 20 and 40 years [10].

Malignant Peripheral Nerve Sheath tumour (MPNST) presents as a rapidly enlarging mass of short duration usually on proximal extremities or any other part of the body without associated multiple cutaneous neurofibromas. [11] This index case of MPNST arises from the forearm as a rapidly growing mass in a young woman without a personal history of multiple cutaneous neurofibromas nor a family history of neurofibromatosis which is concordant with reported cases. [11, 12].

However, a few among the other authors found head and neck to be commonly involved by the MPNST [7, 13].

Grossly, MPNST is a firm to hard tumour mass with infiltrative margin or pseudoencapsulated. The tumour may grow along adjacent nerves or infiltrate nearby soft tissue and the foci of haemorrhage or necrosis may be seen. The ulnar and median nerve was not visualized and the tumour was morbidly adherent to the radial artery and adjacent soft tissue which makes total en bloc impossible. Histologically, it is composed of highly pleomorphic tumour cells arranged in solid sheets and peritheliomatous pattern with uninucleated and multinucleated tumour giant cells. There was heterologous differentiation comprising rhabdomyoblastic cells, chondroblast, and osseous. The rhabdomyoblastic differentiation is strongly associated with a poor prognosis. [14] The patient relation was requested to do an immunohistochemical test for the confirmation of the MPNST but proved abortive because of financial constraints. She was equally referred for radiotherapy at National Hospital Abuja but seems impossible due to financial difficulty and 2 months of pregnancy. The oncologist advised termination of pregnancy because of teratogenic effects of radiation exposure or wait till the postpartum period to assess the therapy. The treatment of MPNSTs is a challenging and multidisciplinary approach comprising the surgeon, oncologist, and pathologist. The surgeon will ensure en bloc resection with tumour free margin while the pathologist must comment on the tumour resection margin because of the risk of recurrence. Oncologists prescribe appropriate doses and number of cycles of radiotherapy. Adjuvant radiotherapy is

recommended whether tumour-free margins can be obtained or not. [13] However, access to functional radiotherapy by our patients is further compounded by limited access to an institution with radiotherapy treatment in Nigeria. There are only 2 centers in the country with functional radiotherapy while other centers reported issues of technical fault developed by the machine which is compounded by a lack of expertise that can institute scheduled inspection preventive maintenance and corrective maintenance. The role of systemic chemotherapy remains controversial. She is two months pregnant which limited her chance of access to radiotherapy. However, an intervention was completely not accessible in this index patient because of financial challenges and a decline in abortion to have radiotherapy in Abuja. The patient was represented with recurrent rapidly enlarging mass with clinical deterioration over the space of 1 month at home and was reported to died at home in August 2021.

5. Conclusion

This article highlight histomorphological features of malignant peripheral nerve sheath tumour with heterologous differentiation composed of osseous, chondroblastic, and rhabdomyoblastic malignant cells in a 15-year-old young woman with multiple challenges militating against access to treatments in the study center.

References

- [1] Masood Hasan Khan, Kausar J Khwaja, Nasir Ahmed Salati, Minhaj Anwar. Malignant Peripheral nerve sheath tumor of the mandible in a young female - A case Report. *Annals of Dental Specialty*. 2014; 2 (4): 155-157.
- [2] Ruay-Sheng Lai, Shong-Ling Lin, Shu-Shong Hsu, Min-Ting Wu. Intrathoracic paraspinal Malignant peripheral nerve sheath tumour. *J Chin Med Assoc*. 2006; 69 (1): 37-41.
- [3] Neurofibromatosis. Conference statement. National Institutes of Health Development Conference. *Archives of Neurology*. 1988; 45 (5): pp. 575-578.
- [4] Guler Berkiten, Muhlis Bal, Yavuz Atar, Ziya Salturk, Onder Dogan, Caglar Cakir. Malignant Peripheral nerve sheath tumor of the neck. *Otolaryngology Online Journal*. 2014; 4 (1): 1-7.
- [5] Ozmen Ozturk, and Alper Tutkun. A Case Report of a Malignant Peripheral Nerve Sheath Tumor of the Oral Cavity in Neurofibromatosis Type 1. *Case Reports in Otolaryngology*. Hindawi Publishing Corporation. 2012. 1-3.
- [6] Shilpa Patel, Jigna Pathak, Kamlesh Dekate, and Neeta Mohanty. Malignant peripheral nerve sheath tumour (MPNST) of the mandible: solving the perplexity. *BMJ Case Rep*. 2015; 2015: bcr2014207790.
- [7] Jude-Kennedy C Emejulu, Okechukwu H Ekwunife, Titus Og Chukwuanukwu, Ikechukwu V Okpalike, Kodilinye O Izuora, Ofodile C Ekweogwu. Malignant Peripheral Nerve Sheath Tumour in a 10-year old. *Journal of Clinical and Applied Neurosciences*. 2017; 2 (1): 36-41.

- [8] W B Laskin, S W Weiss, G L Brattbauer. Epithelioid variant of malignant peripheral nerve sheath tumor (malignant epithelioid schwannoma). *Am J Surg Pathol*. 1991; 15 (12): 1136-45.
- [9] James E Bates, Carl R Peterson, Sughosh Dhakal, Ellen J Giampoli, Louis S Constone Malignant peripheral nerve sheath tumors (MPNST): A SEER Analysis of incidence across the age spectrum and therapeutic interventions in the pediatric population. *Pediatr Blood Cancer* 2014; 61: 1955-1960.
- [10] Widemann BC. Current status of sporadic and neurofibromatosis type 1-associated malignant peripheral nerve sheath tumors. *Curr Oncol Rep*. 2009; 11: 322–328.
- [11] Christopher J Stasik, Ossama Tawfik. Malignant peripheral nerve sheath tumor with rhabdomyosarcomatous differentiation (Malignant Triton Tumor). *Arch Pathol Lab Med*. 2006; 130: 1878-1881.
- [12] Fazil, Marickar, Y. M, Betty Abraham. Malignant peripheral nerve sheath tumour – A long story: A case report. *International Journal of Surgery Case Reports*. 2020; volume 77: 618–623.
- [13] Han-Ju Chen, Huan-Sen Chen, Yen-Liang Chang, Yi-Yiing Wu. Malignant peripheral nerve sheath tumor of the neck: Transformation from a recurrent neurofibroma in a patient without neurofibromatosis. *TZU CHI MED J*; 2010 Dec; Vol 22 (4): 195-199.
- [14] Kamran SC, Howard SA, Shinagare AB, Krajewski KM, Jagannathan JP, Hornick JL et al Malignant peripheral nerve sheath tumors: prognostic impact of rhabdomyoblastic differentiation (malignant triton tumors), neurofibromatosis 1 status and location. *Eur J Surg Oncol*. 2013; 39 (1): 46-52.