



Case Report

Therapeutic Management of Tetanus in a Kamori Male Goat

Ali Gul Soomro¹, Adnan Yousaf^{1, *}, Muhammad Fawad², Sahar Fatima², Mahnoor Khan Jamali²

¹Faculty of Animals Husbandry and Veterinary Sciences, Sindh Agriculture University, Tandojam, Sindh, Pakistan

²Faculty of Veterinary Sciences, University of Veterinary and Animal Sciences, Lahore, Pakistan

Email address:

dr.adnan011@gmail.com (A. Yousaf)

*Corresponding author

To cite this article:

Ali Gul Soomro, Adnan Yousaf, Muhammad Fawad, Sahar Fatima, Mahnoor Khan Jamali. Therapeutic Management of Tetanus in a Kamori Male Goat. *American Journal of Zoology*. Vol. 4, No. 4, 2021, pp. 69-71. doi: 10.11648/j.ajz.20210404.15

Received: September 5, 2021; **Accepted:** September 23, 2021; **Published:** November 5, 2021

Abstract: Tetanus is a prenatal disease caused by the anaerobic, spore-forming bacteria *Clostridium tetani*, which is Gram-positive and anaerobic. With complains of hunger, uneven gait, and gradual loss of body condition, a two-year-old Kamori buck weighing around 60 kg was brought to the outdoor clinics of the Department of Veterinary Surgery and Obstetrics, Sindh Agriculture University Tandojam. According to history, the animal was castrated 10 days prior by a local quack using a regular shaving blade. On the day of the assessment, visual examination revealed that the wound had not fully healed. The fore and hind leg muscles were rigid, the nictitating membrane was prolapsed, and there was hyperesthesia on physical examination. It was diagnosed with tetanus due to the existence of a contaminated wound and clinical indications. The Graham's staining of the fresh smear revealed gram +ve rod shape bacteria that appeared like drumsticks. Furthermore, the *Clostridium tetani* was cultured and isolated from the deep necrotic tissue of the wound. Procaine penicillin (44,000 IU/kg IM) and diazepam (0.1 mg/kg IM) were given to the animal. The treatment was supposed to last five days. The wound was debrided and hydrogen peroxide was used to clean it. Trismus was minimized and the animal's gait improved on the third day of treatment. Overall, tetanus was found in goats, and treatment resulted in improved health outcomes.

Keywords: Tetnus, Kamori Buck, *Clostridium Tetani*, Hyperesthesia, Tandojam

1. Introduction

Unlike Tetanus is a contagious, sometimes lethal neuromuscular disease that affects both animals and humans [9]. *Clostridium tetani*, a spore-forming Gram-positive anaerobic bacterium, is to blame [11]. Spores are found all over the world and are resistant to destruction [8]. The stomach of mammals is another spore reservoir [1, 2]. Tetanus causes two types of toxins, tetanolysin and tetanospasmin, which are produced by the causative bacterium (*C.tetani*) [10]. Tetanospasmin induces clinical signs, while tetanolysin (necrotizing toxins) creates favorable conditions [8]. Tetanus has a varied incubation period [7]. However, it is dependent on the location of the wound/injury and the distance between the wound and the CNS [3, 2]. Prolapse of the third eyelid, hyperesthesia, stiff gait trismus (lock jaw), and generalized stiffness of the body, including the head and neck, are all symptoms of the condition [12, 13]. The tail is likewise strong

and resembles a pump handle. Due to the involvement of the pharyngeal and laryngeal muscles, the diseased animal is unable to swallow at an advanced stage [21]. Other symptoms of tetanus include saliva dribbling, bloat, and aspiration pneumonia [3]. The disease affects a variety of animals, including goats and sheep [4]. Hearing, pierced wounds, dehorning, disbudding, dystocia, tattooing, parturition, hoof clipping, and castration are all risk factors for tetanus in small ruminants [5, 20]. Tetanus can be transmitted to lambs through wounds caused by castration and docking in contaminated yards [6, 19]. Tetanus is found all around the world, however there are very few instances of it in Pakistani goats.

2. Descriptions of Case

A 2 years old Kamori buck weighing around 60 kg was brought to the outdoor clinics of the Sindh Agriculture University Tandojam, Department of Veterinary Surgery and Obstetrics, with complaints of starvation, irregular gait, and

gradual deterioration of body condition. This buck was castrated with a regular shaving blade by a neighborhood quack around 10 days ago. On the day of the assessment, visual examination revealed that the wound had not fully healed (Figure 1).

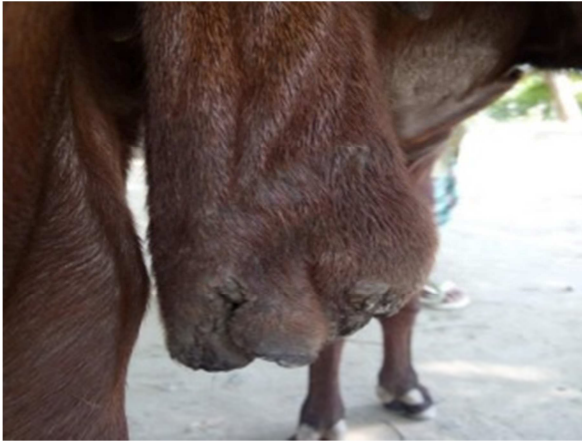


Figure 1. Wound on Scrotum after surgically removal of testes.

The buck's tail was tight and upright ("pump handle tail"). Muscle stiffness in the fore and rear limbs was discovered during a physical examination. Trismus (jaw muscle spasm), nictitating membrane prolapse, and hyperesthesia were also observed (Figure 2).

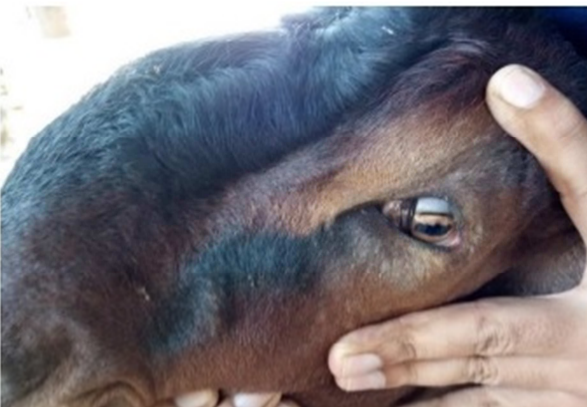

Figure 2. Prolaps of 3rd eye lid of tetanus affected buck.

Salivation and nasal flaring were also reported as a result of aspiration pneumonia. Rectal temperature (103 degrees Fahrenheit), pulse rate (71 beats per minute), and breathing rate (39 breaths per minute) were all within acceptable limits. Tetanus was detected in buck due to the above-mentioned clinical picture.

3. Treatment

Buck was given procaine penicillin at a dose of 44,000 IU/kg IM and diazepam at a dose of 0.1mg/kg IM. The treatment was supposed to last five days. The wound was cleaned with hydrogen peroxide and debrided. Trismus was minimized and the animal's gait improved on the third day of treatment.

4. Discussion

Clostridium tetani (Gram's positive bacteria) causes tetanus, a bacterial disease. It produces toxemia by anaerobically generating particular neurotoxins in the tissue. Bacteria transform into spores in poor conditions [17], which are found in soil all over the world. All mammals are susceptible to infection; however, horses and lambs are more susceptible to tetanus infection than other animals. Goats, on the other hand, are extremely sensitive to tetanus [1, 14]. Shearing, puncture wounds, castration, and surgical treatments are all predisposing factors for tetanus infection [15]. In this case report, a 16-month-old Beetal buck was castrated surgically with a standard blade while preserving aseptic conditions. The animal developed stiffness of the body muscles, a lock jaw, and a prolapse of the third eyelid when the wound became polluted [16]. Buck was diagnosed with tetanus due to the existence of a contaminated wound and clinical indications [18].

5. Conclusion

Clostridium tetani causes tetanus, a bacterial disease in all animals. Generally it produces toxemia by anaerobically generating particular neurotoxins in the tissue. Bacteria transform into spores in poor conditions, which are found in soil all over the world. Shearing, puncture wounds, castration, and surgical treatments are predisposing factors for tetanus infection. Prolapse of the third eyelid, hyperesthesia, stiff gait trismus (lock jaw), and generalized stiffness of the body, including the head and neck, are all symptoms of the condition.

References

- [1] Aitken, I. D. Diseases of Sheep. (2007). 4th Ed. Blackwell Publishing, London, UK, 165-166.
- [2] Atkinson W, Hamborsky J and Wolf S (2012). Epidemiology and Prevention of Vaccine-Preventable Diseases. 12th edition. Public Health Foundation. pp. 291-300.
- [3] Bhikane AU, Yadav GU, Karpe AG and Ambore BN (2005). Tetanus in a deoni calf-A case report. *Intas Polivet*. 6: 42-43.
- [4] Boora AK, Yadav S, Jain VK, Rana N, Singh KP and Balhara AK (2013) Puerperal Tetanus in Water Buffalo – A Case Report. *Journal of Buffalo Science*, 2: 53-55.
- [5] Coetzer JAW and Tustin RC (2004). Infectious Diseases of Livestock. 2nd Edition. Oxford University Press (SA), Cape Vol. 3. p. 2159.
- [6] Connor, B., Leavitt, S., and Parker, K. (1993). Tetanus in feeder calves associated with elastic castration. *Canadian Veterinary Journal*, 34, 311-312.
- [7] Congera AD and Lucile MF (2009). A Quick-Freeze Method for Making Smear Slides Permanent. *Stain Technology*, 28 (6): 281-283.
- [8] Das AK, Kumar B and Kumar N (2011). Tetanus in a Buffalo calf and its Therapeutic management. *Intas Polivet*, 12 (11): 383-384.

- [9] Guilfoile, P., and Babcock, H. (2008). *Deadly Diseases and Epidemics: 2008. Tetanus*, Chelsea House, 18.
- [10] Lewis R (2015). Risk of tetanus in cattle increasing. <http://www.grainews.ca/2015/11/10/risk-of-tetanus-in-cattleincreasing-2/>.
- [11] Lombar R and Zadnik T (2013). Tetanus-three cases in calves. XII Middle European Buiatrics Congress, Belgrade, Serbia, 5-8 June. Faculty of Veterinary Medicine, University of Belgrade and Servian Buiatrics Association. Pp 35-45.
- [12] Mathur P (2015). Tetanus and gas gangrene: things of the past? *Journal of Patient Safety & Infection Control*, 3: 25–26.
- [13] Naqvi, A. N., and Fatima, K. (2012). Incidence of livestock diseases in Nomal and Naltar Valleys Gilgit, Pakistan. *Pakistan Journal of Agricultural Sciences*, 25, 69-75.
- [14] Pugh, D. G., and Baird, A. N. (2012). *Sheep and Goat Medicine*. Elsevier, London, 398-399.
- [15] Radostits OM, Gay CC, Hinchcliff KW and Constable PD (2007). *A Text Book of the Diseases of Cattle, Horses, Sheep, Pigs and Goats*. 10th Edition Book power, Pp. 25-35.
- [16] Radostits, O. M., Gay, C. C., Hinchcliff, K. W., and Constable, P. D. (2007). *Veterinary Medicine: A Textbook of the Diseases of Cattle, Sheep, Pigs, Goats and Horses*. 10th Edi. Saunders-Elsevier, London, 822–824.
- [17] Upadhyay SR, Hussain K and Singh R (2013). Bovine Neonatal Tetanus: A Case Report. *Buffalo Bulletin*, 32 (1): 18-20.
- [18] Singh SK, Dimri U and Kumar A (2009). Therapeutic management of tetanus in Buffalo calves. *Intas Polivet*, 10 (2): 286-88.
- [19] Smith, M. C., and Sherman, D. M. (2009). *Goat Medicine*, Willey-Blackwell, 207-208.
- [20] Tina M and John ST (2010). Characteristics of *Clostridium Tetani*. *Diseases and Conditions*. *Livestrong.com*. 15 March 2014.
- [21] Yousaf A, Abbas M, Laghari RA, Kachiwal AB, Jamil T, Abbas U. (2016). Therapeutical management of tetanus in Kundhi buffalo calf at Hyderabad, Sindh. *Online J. Anim. Feed Res.*, 6 (5): 103-106.