



# Outcome of Sentinel Lymph Node Biopsy with Methylene Blue Dye in Early-stage Breast Cancer

Khandakar A. B. M. Abdullah Al Hasan<sup>1,\*</sup>, A. F. M. Anowar Hossain<sup>1</sup>,  
Md Ashiqur Rahman<sup>1</sup>, Sabiha Sultana<sup>2</sup>

<sup>1</sup>Department of Surgical Oncology, National Institute of Cancer Research and Hospital, Mohakhali, Dhaka, Bangladesh

<sup>2</sup>Department of Department of Reproductive Endocrinology and Infertility, Bangabandhu Sheikh Mujib Medical University (BSMMU), Dhaka, Bangladesh

## Email address:

kabmahasan@gmail.com (K. A. B. M. A. Al Hasan)

\*Corresponding author

## To cite this article:

Khandakar A. B. M. Abdullah Al Hasan, A. F. M. Anowar Hossain, Md Ashiqur Rahman, Sabiha Sultana. Outcome of Sentinel Lymph Node Biopsy with Methylene Blue Dye in Early-stage Breast Cancer. *Cancer Research Journal*. Vol. 9, No. 2, 2021, pp. 98-105.

doi: 10.11648/j.crj.20210902.13

Received: April 3, 2021; Accepted: April 21, 2021; Published: May 14, 2021

---

**Abstract:** *Background:* Axillary staging is the standard of care for all breast cancers amenable to curative treatment. Sentinel lymph node biopsy (SLNB) has been established as the gold standard for axillary staging and has supplanted axillary lymph node dissection (ALND) as a means of regional nodal staging in clinically node-negative breast cancer. Different blue dyes like isosulfan blue dye, patent blue, sulfan blue, radio labeled substances, and methylene blue dye (MBD) have been evaluated for the sentinel node procedure. *Aim of the study:* The aim of this study was to assess the efficacy of sentinel lymph node biopsy with methylene blue dye in clinically axillary node negative early-stage breast carcinoma as well as to observe the early postoperative outcome of SLN procedure. *Method:* Between November 2015 to October 2017, a total of 18 female patients of 18 years and above, with diagnosis of early-stage (T1/T2) breast carcinoma with clinically negative ipsilateral axillary lymph nodes were studied in the department of surgical oncology, NICRH. Written informed consents were obtained from all patients. *Results:* In this study, the highest population was in 31-50 years age group with a mean age of 46(SD 12). Out of 18 cases, SLN(s) was identified in 15 cases by using MBD. The identification rate was 83.3%. In frozen section biopsy all SLNs were found positive for malignant cells. Two or more SLNs were positive in 12(66.6%) cases where SLNB was extended to ALND. The sensitivity, specificity, positive predictive value (PPV), and negative predictive value (NPV) were 100, 50, 80 and 100, respectively. Postoperative morbidity was significantly high in ALND group. *Conclusion:* This study showed that SLNB is a safe procedure and efficacy of this procedure was very significant. It lowers the unnecessary extended surgery (ALND) which has troublesome postoperative complications. Multicenter studies are required to extract more relevant information in this regard.

**Keywords:** Breast Cancer, MRM, Lumpectomy, BCS

---

## 1. Introduction

Breast cancer is a major health problem and was among the top three most common malignancies globally in 2012 as well as it is the most common cancer in women, with an estimated 1.67 million new cases diagnosed in 2012. [1] The AJCC staging system evaluates tumor size and extent of tumor invasion, the presence and location of lymph node metastasis, and distant organ metastasis, and correlates these

characteristics with survival data to produce a prognostic staging category for the patient. [2] In addition, data by prognostic stage on the efficacy of surgery, radiation, hormonal and chemotherapy to improve survival. When breast cancer patients present with palpable axillary lymph nodes that are suspicious for cancer metastases, these patients are staged and treated surgically by Axillary Lymph Node

Dissection (ALND). Nevertheless, axillary dissection is a major operation, requires general anesthesia, and produces long-term morbidity in a small, but significant, minority of patients. [3] ALND, as a means for achieving local disease control, carries an indisputable and often unacceptable risk of complications such as seroma, infection, and lymphedema, painful neuroma, neuropathies and axillary web syndrome. [4] Elective regional lymph node dissections became controversial because of overtreatment of the many patients without lymph node metastases. These patients suffer from associated morbidity without survival benefit. With the introduction of the sentinel node concept, a minimally invasive procedure became available for detection of occult lymph node metastasis. [5] The concept of sentinel lymph node biopsy is based on two basic principles: the existence of an orderly and predictable pattern of lymphatic drainage to a regional lymph node basin, and the functioning of a first lymph node as an effective filter for tumor cells. [6] With the widespread use of sentinel node biopsy, sufficient data was provided to prove that sequential lymphatic dissemination and entrapment of tumor cells in first draining lymph nodes occur. [3] The function of lymph nodes in the spread of cancer was investigated by injection of small particles into afferent lymphatics of animal models. Observations from these experiments contradicted both the “filter function” postulated by Virchow and the Halstedian model of contiguous cancer spread, giving rise to new understandings and differing hypotheses of SLN function. [7] Fisher and Fisher observed that the node was not a “filter” that prevented dissemination of tumor cells but that metastatic disease in the lymph node was a “marker” for the presence of systemic disease [8] By the 1990’s, the SLNB had become a valid technique in staging malignant tumors of the skin and breast. [9] Over the last few decades, clinical trials comparing the effectiveness of SLNB and ALND have randomized over 9000 patients with early breast cancer. [10-14] They have demonstrated that SLNB reduces the risk of arm morbidity and lymphoedema, and shortens the postoperative hospital stay without significantly increasing locoregional recurrence or survival, with two trials reporting data at mean follow-up times of approximately 8 years. [14, 15] One main pitfall is the failure to visualize the SLN, resulting in incorrect tumor staging, leading to suboptimal treatment or axillary recurrence. [16] To reduce the false negative rate of the SLN procedure, the use of a combined method (technetium and blue dye) is recommended. [17] Different blue dyes, isosulfan blue dye (IBD), patent blue (PB), sulfan blue, sulphane blue, patent blue violet, patent pure blue, and methylene blue dye (MBD) have been evaluated for the SLN procedure. [18] MBD was less satisfactory in defining lymphatic drainage patterns because of poor uptake in the lymphatics and because of tissue staining. As a result, IBD and its isomer PB were adopted for use in the SLN procedure. [19] However, it rapidly appeared that IBD and PB were associated with a significant number of allergic reactions (0.1-3%), some of which were life-threatening. Moreover, an international shortage of IBD led

to a search for alternative dyes for SLN mapping in breast cancer. The first published study of MBD injection for the SLN procedure in breast cancer and described localization rates of 90%, which was unexpectedly comparable to IBD and PB. Moreover, these dyes are costly and not frequently available. MBD has been shown in numerous other studies to be equally effective in SLN identification in comparison with other blue, it was proposed as an alternative technique for the SLN procedure [17] MBD is more economical than isosulfan blue, does not cause hypersensitivity reactions or any other significant complications and, most importantly, is as good as, and possibly better than, isosulfan blue at SLN mapping. Thus, MBD as a single agent is well suited to surgeons in developing countries to offer the important technique of SLN biopsy without significantly compromising the quality of the test.[20] The SLNB can be done using either technique or doing both at the same time with a similar accuracy. Now SLNB is established as the standard of care in breast cancer with clinically node negative axilla on presentation [17], Bangladesh is facing a high burden of breast cancer disease. It is the leading cause of cancer death in female and incidence of breast cancer in Bangladesh is 21.4%. [21] Hospital-based cancer registry has been started at National Institute of Cancer research Hospital (NICRH) and Oncology Department of Bangabandhu Sheikh Mujib Medical University (BSMMU). Late presentation with advanced stage is the common feature of breast cancer patients of Bangladesh. It is easily understandable that breast cancer incidence is increasing at a faster rate. Therefore, in Bangladesh, estimate of an annual new breast cancer case burden of 30,000 women. [22] A prior study showed that majority of breast cancer patients presenting with a large tumor were associated with regional adenopathy, chest wall changes and distant metastases. [23] But the scenario is changing gradually. Early-stage breast carcinoma is being detected frequently in our National Institute of Cancer Research & Hospital (NICRH) and other tertiary care hospitals. Almost all early breast cancer cases are detected clinically and can be detected at earlier stages by simple self-examination of the breasts and thorough breast screening program. As there are no nationally applicable standard protocols or guidelines for managing breast cancer in Bangladesh, the quality of treatment varies widely. Most of the surgeons prefer modified radical mastectomy which includes axillary level II nodal clearance irrespective of actual nodal status. In our NICRH, Breast conservation surgery is adopted for early-staged carcinoma of breast. But there is no documentation or study found in Bangladesh in favor of sentinel lymph biopsy in clinically node negative early-stage breast cancer. Though our economy is growing up but there are very negligible health facilities for domestic population. As there is no facility of lymphatic scintigraphy in our institution so in our study, we used only Methylene Blue Dye (MBD) to identify the sentinel node preoperatively. Our aim of this study to assess the efficacy of sentinel node biopsy with MBD in clinically node negative early-stage breast cancer as well as the early postoperative outcome of

this procedure.

## 2. Objectives

General objective: To assess the efficacy of sentinel node biopsy in early-stage breast cancer.

Specific objectives:

- 1) To assess feasibility of SNB in early-stage breast cancer.
- 2) To evaluate the complications of SNB procedure.
- 3) To observe the surgical outcome of SNB.

## 3. Material and Methods

This study was conducted to evaluate the early post-operative outcomes of breast cancer surgery. It was an Observational study. Histologically or cytologically proven patients with breast cancer admitted in the department of Surgical Oncology of National Institute of Cancer Research Hospital, Dhaka were considered as study population. The study period was from October 2016 to August 2017. Purposive sampling technique was used. Patients were selected from the department of surgical oncology on the basis of inclusion and exclusion criteria.

### Inclusion Criteria

Invasive Duct cell carcinoma with clinically negative axillary lymph nodes where tumor size is 5cm or below, admitted in National Institute of Cancer Research and Hospital, Dhaka.

### Exclusion criteria

- 1) T<sub>3</sub>, T<sub>4</sub> lesion (Tumor size more than 5 cm)
- 2) Inflammatory breast cancer.
- 3) Multicentric breast cancer.

## 4. Results

In our study, the range of the age was between 30-65 (Figure 1). The mean age was 46.1(SD12) and median age was 45. In Table 1, most of the cases were housewife (77.7%) and office staff and teacher were as same (11.1%). among the patients only 11.1% of cases had their first child after the age of 30 and most of them (83.3%) feed their babies with breast feeding. Table 2 shows most of the patient had menarche at or above 12 years (77.8%) and 22.2% had using of hormonal contraception. Among the patients, tobacco user and positive family history were found in 33.3% and 16.7%. Most of the patient (55.6%) was found with menopause. Table 3 shows both mammogram and ultrasonogram detects 100% Tumor mass in breast but in case of axillary lymph nodes 38.8% cases had axillary lymph nodes. Table 4 shows most (50%) of the FNAC result found duct cell carcinoma others were suggestive of duct cell carcinoma (16.7%) and positive for malignant cell. Table 5 shows Postoperative follow up results in pain is the only

(27.8%) residual complication after surgery and most of the patients are satisfied (77.8%) with their outcome. Table 6 shows age between 20-30, there are equal number (5.5%) SNB positive and negative whereas most of the (50%) patient in the 31-50 years age group is SNB positive and only (5.5%) are negative SNB in 51-70 years age group. However, no significance in p value was seen. 55.5% of patients were SNB positive found in 2-6 months duration group, (22.2%) patients from 7-12 months duration group were SNB positive and there were no 0% SNB negative in over 12 months group. P value was not significant. In the relationship between T staging and SNB procedure, the early-stage (T1) is more SNB negative (22.2%) than T2 stage (5.5%). Most of the patients in T2 stage (72.2%) were SNB positive. Here p value is 0.005 which is significant. Tumors in left breast are (44.4%) mostly SNB positive and rest 11.1% are SNB negative. In right breast (38.8%) patients were SNB positive. In the relation between Tumor location and SNB procedure (11.1%) patients were SNB negative in Upper Lateral (UL) group whereas (72.2%) patients were SNB positive in the same group. There is no significance between location of Tumor and SNB where the P values were 1.00 and 0.554 respectively. Table 7 shows the efficacy of Methylene blue dye where 83.3% cases dye were taken or drained by lymph nodes. 16.7% cases only single lymph nodes were stained and second third and fourth sentinel lymph nodes were stained respectively 44.4%, 22.2% 0% cases. Only in 3 cases dye were not taken. Frozen section results show almost 83.3% cases were positive in frozen section and rests were negative. 66.7% cases were undergoing for ALND where as other 33.3% were SNB. Table 8 shows the postoperative outcome of both subgroup SNB and ALND. Where 6 out of 12 cases had developed postoperative complications in ALND sub group in which wound infection (5.5%), seroma formation (11.1%), Haematoma (5.5%), paresthesia in arm (11.1%). And discolouration to skin was seen in only in 1 case (5.5%) but no flap necrosis, early arm oedema, axillary web syndrome, immediate reaction to the dye were not found.

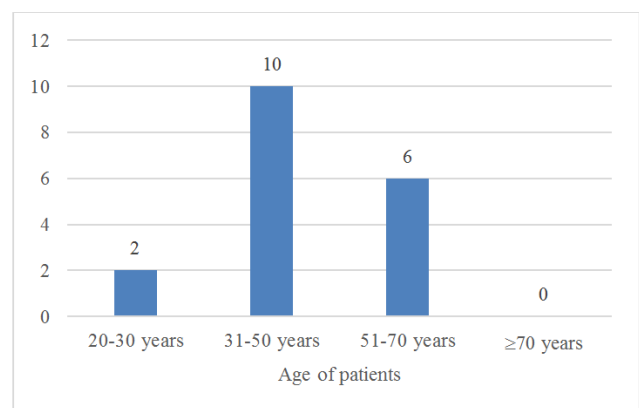


Figure 1. Age distribution of the patients (n=18).

**Table 1.** Distribution of patients by occupation, maternity and breast Feeding (n=18).

Variable		n	%
Occupation	Housewife	14	77.7
	Office staff	2	11.1
	Teacher	2	11.1
	NGO staff	1	0.05
	Health staff	0	0
Age of 1st child	<30 years	16	88.9
	>30 years	2	11.1
Breast Feeding	Yes	15	83.3
	No	3	16.7

**Table 2.** Distribution of patients by risk factors(n=18).

Variable		n	%
Onset of menarche	<12 years	14	77.8
	>12 years	4	22.2
Hormonal contraceptive use	Yes	4	22.2
	No	14	77.8
Menopause	Yes	8	44.4
	No	10	55.6
Tobacco consumption	Yes	6	33.3
	No	12	66.7
Family History	Yes	3	16.7
	No	15	83.3

**Table 3.** Distribution of tumor by imaging study (n=18).

Variable			n	%
Mammogram	Mass	Present	18	100.0
		Absent	0	0.0
	Lymph node	Present	6	33.3
		Absent	12	66.7
USG	Mass	Present	18	100.0
		Absent	0	0.0
	Lymph node	Present	7	38.9
		Absent	11	61.1

**Table 4.** Distribution of tumor by FNAC (n=18).

Variables	n	%
Positive for Malignant cell	3	16.7
Suggestive of duct cell carcinoma	3	16.7
Atypical cell	3	16.7
Duct cell carcinoma	9	50.0

**Table 5.** Distribution of post-operative follow up outcome (n=18).

Variable		n	%
Pain	Present	5	27.8
	Absent	13	72.2
Lymphoedema	Present	0	0
	Absent	18	100
Patients satisfaction	Present	14	77.8
	Absent	4	22.2

**Table 6.** Cross tabulation of SNB (n=18).

Variable		Positive		Negative		Total (%)	P-value
		n	%	n	%		
Age	20-30	1	5.5	1	5.5	11.1	.383 <sup>NS</sup>
	31-50	9	50.1	1	5.5	55.6	
	51-70	5	27.7	1	5.5	33.3	
	<2 months	1	5.6	0	0	5.6	
Tumor Duration	2-6 months	8	55.5	3	5.5	61.1	.596 <sup>NS</sup>
	7-12 months	6	22.2	0	0	33.3	
	≥12 months	0	0	0	0	0	

Variable		Positive		Negative		Total (%)	P-value
		n	%	n	%		
T stage	T 1	1	5.5	3	16.7	22.2	.005 <sup>S</sup>
	T 2	14	77.8	0	0	77.8	
Site	Right	7	38.9	2	11.1	50	1.00 <sup>NS</sup>
	Left	8	44.4	1	5.6	50	
Position	UM	1	5.5	1	5.5	11.1	.554 <sup>NS</sup>
	UL	12	66.7	2	11.1	77.8	
	LM	2	11.1	0	0	11.1	
	LL	0	0	0	0	0	

Table 7. The result of sentinel Lymph node biopsy in Frozen section Biopsy (n=18).

Variables	Sentinel Lymph Node	n	%
No of positive Lymph node	0	3	16.7
	1	3	16.7
	2	8	44.4
	3	4	22.2
	4	0	0
Frozen section	Positive	15	83.3
	Negative	3	16.7
ALND performed	Yes	12	66.7
	No	6	33.3

Table 8. Cross tabulation between complications and performed procedure (n=18).

Variables		SNB alone		SNB+ALND		Total (%)	P value
		n	%	n	%		
Wound Infection	Yes	0	0	1	5.5	5.5	1.00 <sup>NS</sup>
	No	6	33.3	11	61.1	94.5	
Seroma	Yes	1	5.5	1	11.1	16.7	.205 <sup>NS</sup>
	No	5	27.5	10	55.5	83.3	
Haematoma	Yes	0	0	1	5.5	5.5	.620 <sup>NS</sup>
	No	6	33.3	11	61.1	94.5	
Flap necrosis	Yes	0	0	0	0	0	NA
	No	6	33.3	12	66.7	100	
Early arm oedema	Yes	0	0	0	0	0	NA
	No	6	33.3	12	66.7	100	
Paresthesia	Yes	0	0	2	11.1	22.2	.558 <sup>NS</sup>
	No	6	33.3	10	55.5	78.8	
Axillary web syndrome	Yes	0	0	0	0	0	NA
	No	6	33.3	12	66.7	100	
Immediate reaction to dye	Yes	0	0	0	0	0	NA
	No	6	33.3	12	66.7	100	
Discolouration of skin	Yes	0	0	1	5.5	5.5	.125 <sup>NS</sup>
	No	6	33.3	11	61.1	94.5	

## 5. Discussion

In the current study most of the patients (56%) were from 31-50 years age group followed by (33%) in 51-70 years age group. The mean age of this study population was 46.1 years with SD 12 where the median age was 45. A study by Hossain M. S., [24] conducted in Bangladesh where Mean age of sample size were 41.8 years. In GLOBOCON study the mean age in India was 45. Both of the results were similar to this study. Most of the case 77.7% were house wife and only 11.1% were office staff and teaching profession. In another study conducted by Ozsoy et al., [25] showed 56% of early breast cancer patients were office worker but in Bangladesh, the socioeconomic perspective is different. Most of the women in Bangladesh are housewife. Our study showed that 89% of cases had their first child birth below the age of 30 and most of them 83.3% fed their babies from both

breasts. Palmer JR et al., [26] showed that longer duration of breast feeding has been associated with a greater reduction in breast cancer risk. This present study showed that most of the patient had menarche at or below 12 years of age (77.8%) and only 22.2% had H/O using hormonal contraception. Alwan NAS. [27] showed in his study that 74.5% cases with early breast cancer were history of early menarche which is just similar to our study. Among the patients, tobacco user and positive family history were found in 33.3% and 16.7% consecutively. In our study 100% sonographic and mammographic positive evaluation was found that in all cases breast lump were present and only in 6 & 7 cases lymph nodes were identified in ultrasonogram and mammogram respectively. Ultrasound is an effective diagnostic tool for identification of lymph nodes in the axillary region. In the study of Nowikiewicz et al., [28] shows that 21.9% of preoperative axillary sonogram lymph nodes were found as metastatic sentinel lymph nodes. A large

portion of the FNAC reports revealed Duct Cell Carcinoma (50%) and other were suggestive of Duct cell carcinoma (16.7%) and positive for malignancy (16.7%). In all cases true-cut biopsy were done to confirm tissue diagnosis. Mathelin et al. [29] study also shows the frequency of duct cell carcinoma was 83% which is similar to our study. Regarding age and sentinel lymph node biopsy procedure, our study population has no significance (p value.383) by Chi square test. In case of duration of the Tumor also showed no significance in between SNB procedure and Tumor duration where value is.596. In relation to T1 /T2 staging and sentinel lymph node biopsy procedure there is significant relation where p value is <.005. There are several studies which showed a close relation between breast Tumor size and axillary lymph node involvement. A study was conducted in India by Asthurkar AV., [30] showed there was no relation between age and Tumor size. Georgette S. W., et al., [31] the greater the T stage, the higher the incidence of Level I and level II involvement (4.4% in T1 and 36.35% in T2) which is just similar to our study. In the maximum study there were no relation in between Tumor site, location and sentinel lymph node biopsy procedure. In our study site and position has  $p=1.00$  and  $p=.554$  respectively which correlates the previous study. SLNB is a safe and an accurate method of screening the axillary lymph nodes in women with breast cancer. Furthermore, a negative SLNB can spare the patient from the morbidity that accompanies a complete ALND. Furthermore, should the patient require a subsequent AD, an intraoperative SLNB has the potential of avoiding the risks associated with a second surgery and anesthesia exposure, which are not trivial. In our study, the rate SNB positive were 83.3%. We found only 3 cases of no intraoperative axillary lymph node staining as well as frozen section was also negative. 16.7% cases there were single lymph node was positive during frozen section but further no lymph nodes were involved. So, in these cases we haven't performed further ALND. In most cases 44.4%, two lymph nodes were positive in FSB was found and in 22.2% cases 3 lymph nodes were positive. In Ratchawarapong K et al., [32] study showed 16 % cases were SNB negative and 1, 2 and 3 lymph nodes were positive in 40%, 28%, 13% case respectively. In that study SLN positive was 55% which near to our study. The need for intraoperative SLNB assessment in situations where additional ALND is unlikely to be performed even if a metastasis is detected in the sentinel lymph node. The ACOSOG Z0011 study showed no difference in local or regional recurrence between patients with single positive sentinel lymph nodes who were randomized or either SLNB only or SLNB and ALND. Alberitini et al., [31] showed combined dye directed and probe directed mapping in 62 patients with primary early breast carcinoma, the detection rate was higher (92%) in combined group than dye (73%) only group. The current study showed in ALND sub group, wound infection rate was 5.5% and the seroma formation in axilla was only in 3 cases (16.7%) and paresthesia in arm found in 11.1% of cases. There were no cases of early arm oedema, Flap necrosis, Axillary web syndrome, immediate reaction to blue dye but

in 11.1% of cases we found partial blue discolouration of axillary skin which was managed conservatively. In a study by Lucci et al., [33] the wound infection rate was 8% followed by 14% cases developed seroma. About 40% cases experienced axillary paresthesia in arm in axillary dissection group which reflects the extensive surgical morbidity of ALND. In our study there were no surgical complication in the SNB only group. In all subgroup of postoperative complications showed no significant relation in between them. In the study of Lucci et al., [33] also showed wound infection, axillary seroma, paresthesia was significantly less in SLND group. ALND was designed to maximize survival and the regional control and to determine the nodal classification with substantial side effects where as SLND was designed to minimize side effects of lymph node surgery but still offer outcomes equivalent to axillary node dissection. Our results show that this simplified technique of identifying the sentinel node (s) by using peri Tumoral methylene blue has sufficiently high technical success rate (83%) and Positive predictive value (PPV) (80%) and a Negative predictive value (NPV) (100%) to allow its useful application in women with invasive breast cancer and clinically negative axilla. We propose that patients with histologically negative SN(s) can be spared complete axillary clearance with its potential morbidity, namely seroma, neuralgia, paraesthesia and lymphoedema.

#### *Limitations of the Study*

The study had a too small sample size. The study was conducted in a single center which doesn't reflect the original scenario of Bangladesh. So here need a large multi scale, multi center countrywide study for authentic outcome. Lack of facilities of lymphoscintigraphy and Gamma Camera by which the study can get more perfect result in SNB. Only early postoperative outcomes were noticed here but long-term outcome was recorded so that no recurrence rate was mentioned.

## **6. Conclusion and Recommendations**

The effectiveness of sentinel node identification using Methylene Blue dye in early breast cancer at National Institute of Cancer Research & Hospital (NICRH), Mohakhali Dhaka. In our study the rate of identification of sentinel lymph nodes were high with methylene blue dye where sensitivity, specificity, NPV and PPV were very much significant. One third of patients with clinically node negative axilla were not undergone for axillary lymph node dissection but they have a very little or no post-operative complications. The outcome of sentinel node biopsy was with less postoperative complications and less morbidity than axillary lymph node dissection. With minimal risk of complications SLND can accurately distinguish patients who would not benefit from ALND. We recommend that patients with clinically no early-stage breast carcinoma should be selected for sentinel lymph node biopsy. MBD could be used as dye because it has an effective role in SNB procedure with minimal complications. It is cost effective also. Frozen

section facilities should be available in government hospital and it would help profoundly to the early-stage breast cancer patient to detect the SLN and reduce the length of surgery as well as morbidity of the patient. Patient education and extensive breast cancer screening program should be adopted all over the country to find the early-stage breast cancer.

## Funding

No funding sources

## Conflict of Interest

None declared

## References

- [1] Zahoor s., Altaf H., Battoo A., Qurieshi M., Wahid M., Shah M., 2017. Sentinel Lymph node Biopsy in Breast Cancer: A clinical review and update. *Journal of breast cancer*. September; 20 (3): 217-227. Available at: <http://doi.org/10.4048/jbc.2017.20.3.217>.
- [2] Rashid O. M., Takabe K., 2012. Sentinel lymph node biopsy for breast cancer: our technique and future directions in lymph node staging, *Journal of Nuclear Medicine & radiation therapy*. S2; 1-4.
- [3] Cody HS. Sentinel lymph node mapping in breast cancer. *Breast cancer*. 1999 Jan 1; 6 (1): 13-22.
- [4] Bernstein V., Hayes M., Kingston G., Poole B., Turner L., Cuddington G., 2003. Provincial guidelines for lymphatic mapping and sentinel lymph node biopsy for breast cancer. *British Columbia surgical oncology network*. November 21; 1-7.
- [5] Moghimi m., Ghoddosi I., Rahimabadi A. E., Sheikhvatan M., 2009. Accuracy of sentinel node biopsy in breast cancer patients with high prevalence of axillary metastasis. *Scandinavian journal of surgery*, 98; 30-33.
- [6] Cox C. E., Pendas S., Cox J. M., Joseph E., Shons R. A., Yeatman T., 1998. Guidelines for sentinel node biopsy and lymphatic mapping of patiens with breast cancer. *Annals of surgery*, 227 (5), -653.
- [7] Somasundaram s. k., chicken D. W., Keshtgar M. R. S. 2007. Detection of sentinel lymph node in breast cancer. *British Medical bulletin*; 84: 117-131.
- [8] Rosso K. J., Nathansom S. D., 2015. Techniques that accurately identify the sentinel lymph node in cancer. *World journal of surgical procedures*. March 28; 5 (1): 14-26. [online]. Available at: <http://www.wjgnet/2219-2831/full/v5/i1/14>.
- [9] Morton DL, Wen DR, Wong JH et al. 1992. Technical details of intraoperative lymphatic mapping for early-stage melanoma. *Arch Surgery*; 127, 392–399.
- [10] Mansel RE, Fallowfield L, Kissin M., 2006. Randomized multicenter trial of sentinel node biopsy versus standard axillary treatment in operable breast cancer: The Almanac Trial. *J Natl Cancer Inst*; 98: 599-609.
- [11] Veronesi U, Paganelli G, Viale G, Luini A, Zurrida S, Galimberti V, Intra M, Veronesi P, Maisonneuve P, Gatti G, Mazzarol G, De CC, Manfredi G, Fernandez JR., 2006. Sentinel-lymph-node biopsy as a staging procedure in breast cancer: update of a randomised controlled study. *Lancet Oncol* 7 (12): 983 – 990.
- [12] Canavese G. et al (2008). Sentinel node biopsy compared with complete axillary dissection for staging early breast cancer with clinically negative lymph nodes: results of randomized trial. *Annals of oncology*, 20: 1001-1009.
- [13] Gill G., et al., 2009. Sentinel-lymph-node-based management or routine axillary clearance? One-year outcomes of sentinel node biopsy versus axillary clearance (SNAC): a randomized controlled surgical trial. *Ann Surg Oncol* 16 (2): 266 – 275.
- [14] Krag D. N., Anderson S. J., Jullian T. B., Brown A. M., Harlow S. P., wolkmark N., 2010. Sentinel-lymph-node resection compared with conventional axillary-lymph-node dissection in clinically node-negative patients with breast cancer: overall survival findings from the NSABP B-32 randomised phase 3 trial. *Lancet oncology journal*. 11 (10), 927-933.
- [15] Veronesi U, Paganelli G, Galimberti V, et al., 1997. Sentinel-node biopsy to avoid axillary dissection in breast cancer with clinically negative lymph nodes. *Lancet*; 349 (9069): 1864–7.
- [16] Giuliano A. E., Kirgan D. M., Guenther J. M., Morton D. L., 1994. Lymphatic mapping and sentinel lymphadenectomy for breast cancer. *Annals of surgery*. 220 (3), 391-401.
- [17] Mathelin C, Croce s., Brasse D., Gairard B., Gharbi M., Andriamisanratsoa N., Bekeart V., et al., 2009. Methylene blue dye, an accurate dye for sentinel lymph node identification in early breast cancer. *Anticancer research*. 29:4119-4126.
- [18] Tsopeles C., Sutton R., 2002. Why certain dyes are useful for localizing the sentinel lymph node. *Journal of nuclear medicine*. 43 (10), 1377-1381.
- [19] Simmons R. M., Smith S. M. and Osborne M. P., 2001. Methylene blue dye as an alternative to isosulfan blue dye for sentinel lymph node localization. *The Breast Journal*. 7, 181-183.
- [20] Mukherjee A, Kharkwal S, Charak KS. Assessment of the efficacy and safety of methylene blue dye for sentinel lymph node mapping in early breast cancer with clinically negative axilla. *Archives of International Surgery*. 2014 Jan 1; 4 (1): 6.
- [21] Hussain SA, Sullivan R. Cancer control in Bangladesh. *Japanese journal of clinical oncology*. 2013 Dec 1; 43 (12): 1159-69.
- [22] Rahman M., Ahsan A., Begum F., Rahman K., 2015. Epidemiology, Risk factor and tumour profiles of Breast cancer in Bangladeshi underprivileged women. *The Gulf journal of oncology*. ISSN. 2078-2101.
- [23] Pervin M. M., Nath H. D., Bahar M. M., Alam A., Bhowmic J., 2014. Study on clinical presentation of breast carcinoma of 50 cases. *Chattagram Maa-o-Shishu Hospital Medical College Journal*. 13 (2), 8-11.
- [24] Hossain M S., Ferdous S., Karim Kos H E. (2014). Breast cancer in South Asia: A Bangladeshi Prtspective. *The International Journal of of cancer epidemiology, Detection and prevention*. [ONLINE] available at: <http://www.dx.doi.org/10.1016/j.canep.2014.08.004>.

- [25] Ozsoy A., et al., (2017). The relationship between breast cancer and risk factors: a single centre study. *Eur. Journal of Breast Health*. 13: 145-149.
- [26] Palmer JR, Wise LA, Hatch EE, Troisi R, Titus-Ernstoff L, Stohsnyder W, Kaufman R, Herbst AL, Noller KL, Hyer M, Hoover RN. Prenatal diethylstilbestrol exposure and risk of breast cancer. *Cancer Epidemiology and Prevention Biomarkers*. 2006 Aug 1; 15 (8): 1509-14.
- [27] Alwan NA. Breast cancer: demographic characteristics and clinico-pathological presentation of patients in Iraq. *EMHJ-Eastern Mediterranean Health Journal*, 16 (11), 1159-1164, 2010. 2010.
- [28] Nowikiewicz T. et al., (2015). Diagnostic value of preoperative axillary lymph node ultrasound assessment in patients with breast cancer qualified for sentinel lymph node biopsy. *Videosurgery Miniinv*; 10 (2): 170-172.
- [29] Ashturkar AV, Pathak GS, Deshmukh SD, Pandave HT. Factors Predicting the Axillary Lymph Node Metastasis in Breast Cancer: Is Axillary Node Clearance Indicated in Every Breast Cancer Patient? *Indian Journal of Surgery*. 2011 Oct 1; 73 (5): 331-5.
- [30] Georgette SW et al. (2004). Correlation between breast tumour size and level of the axillary lymphnode involvement. *Asian journal of surgery*. 28 (2): 97-99.
- [31] Ratchawarapong K et al., (2014). Rate of sentinel lymphnode identification using isosulphan blue dye in breast cancer patients at Charoenkrung Pracharak Hospital, Thailand. *Journal of Asian Biomedicine*, 8 (4): 517-524.
- [32] Albertini JJ, Lyman GH, Cox C, Yeatman T, Balducci L, Ku N, Shivers S, Berman C, Wells K, Rapaport D, Shons A. Lymphatic mapping and sentinel node biopsy in the patient with breast cancer. *Jama*. 1996 Dec 11; 276 (22): 1818-22.
- [33] Lucci A. et al., (2007). Surgical complications associated with sentinel lymphnode dissection (SLND) plus axillary lymphnode dissection compared with SLND alone in the American College of Surgeons oncology group trial Z0011. *Journal of cli.onco.*, 25 (24): 3657-3663.