

# Neuroendocrine Tumours of Gastrointestinal Tract: Our Experience

Paul Eduardo Lada<sup>1,\*</sup>, Casares Gonzalo<sup>2</sup>, Mariot Daniela<sup>2</sup>, Janikow Christian<sup>2</sup>, Saliba Jorge<sup>2</sup>, Martínez Julián<sup>3</sup>, Santiago Carrizo<sup>3</sup>, Abril Giménez<sup>3</sup>, Francisco Flórez<sup>4</sup>

<sup>1</sup>Servicio de Cirugía General "Pablo Luis Mirizzi" del Hospital Nacional de Clínicas, Facultad de Ciencias Médicas, Universidad Nacional de Córdoba, Córdoba, Argentina

<sup>2</sup>Servicio de Guardia Central del Hospital Nacional de Clínicas, Facultad de Ciencias Médicas, Universidad Nacional de Córdoba, Córdoba, Argentina

<sup>3</sup>Residente de Cirugía General del Hospital Nacional de Clínicas, Facultad de Ciencias Médicas, Universidad Nacional de Córdoba, Córdoba, Argentina

<sup>4</sup>Servicio de Cirugía General, Clínica Privada Caraffa, Córdoba, Argentina

## Email address:

pauleduardolada@yahoo.es (P. E. Lada)

\*Corresponding author

## To cite this article:

Paul Eduardo Lada, Casares Gonzalo, Mariot Daniela, Janikow Christian, Saliba Jorge, Martínez Julián, Santiago Carrizo, Abril Giménez, Francisco Flórez. Neuroendocrine Tumours of Gastrointestinal Tract: Our experience. *Cancer Research Journal*.

Vol. 9, No. 4, 2021, pp. 196-201. doi: 10.11648/j.crj.20210904.13

**Received:** January 10, 2021; **Accepted:** January 18, 2021; **Published:** December 24, 2021

---

**Abstract:** *Background:* TNE-GEPs are rare and originate in the endocrine system located in the gastrointestinal tract (carcinoids) and in the pancreas (island tumours) with a variety of clinical presentations. *Design:* Cooperative, retrospective. *Method:* Between January 2005 and December 2018, a cooperative work in the Central Guard Service of the HNC, General Surgery Service "Pablo Luis Mirizzi" of the HNC and Caraffa Private Clinic, 24 patients with TNE-GEP were surgically intervened. Of the total, 14 belonged to the female sex (58.3%) and the remaining 10 men (41.6%), with an age range between 20 and 82 years of age with an average of 55.3 years. *Results:* The locations were 4 stomachs (16.6%), 14 in the intestine (58.3%) and finally 6 in the head of the pancreas (25%). In relation to the stomach in the 4 patients a total gastrectomy was performed and the pathological anatomy in three demonstrated low-grade neuroendocrine carcinoma and the fourth high degree, the latter dying. 5 patients with clinical presentations of acute appendicitis. The pathological anatomy was further acute appendicitis, a low-grade neuroendocrine carcinoma. In ileum-cecal region, four of it performed right colectomy. In three were low-grade living and fourth high-grade carcinoma with liver mts who died. In three of the ileum all were occlusive, carrying out intestinal resections, in two low- and last-grade moderate-grade carcinomas with living liver mts. The colon tumours were, one ascending with hepatic mts and right colectomy more liver resections, with pathological anatomy being high-grade carcinoma and another a low-grade descending colon. The 6 pancreas lesions, 3 were non-functioning and three other functioning. All patients were operated of CPD. *Conclusion:* TNE-GEP is a rare pathology but whose frequency is constant onset. With improved imaging methods, we are faced with an increase in preoperative presumption and in the face of its best oncological possibilities, a pathology that every surgeon must know and think about.

**Keywords:** TNE-GEPs Are Rare, Endocrine System Located in the Gastrointestinal Tract, Surgical Treatment

---

## 1. Introduction

Neuroendocrine tumours of the gastro-enteric-pancreatic system (NETs-GSP) are rare and originate in the endocrine system located in the gastrointestinal tract (carcinoids) and

pancreas (insular tumours) with a wide variety of clinical presentations [1, 2].

The WHO in 2010 divided NETs-GEP into pure and non-pure tumours [3, 4]. The first are those located in the pancreas and gastrointestinal tract, which were divided into two groups:

NETs well-differentiated and NETs Carcinomas poorly differentiated. Well differentiated TNEs are separated in G1 (carcinoids) and G2. G1s are well differentiated TNEs tumours because they have a mitotic count rate of less than 2 and a ki 67 per cent proliferation rate of 2%. G2s are tumours as defined neuroendocrine carcinomas well differentiated, but have a mitotic count rate between 2 and 20 and a proliferation rate Ki 67 between 3 and 20%. Carcinomas are poorly differentiated neuroendocrine tumours are called G3 [5].

## 2. Materials and Methods

Between January 2005 and December 2018, a cooperative work in the Central Guard Service of the HNC, General Surgery Service "Pablo Luis Mirizzi" of the HNC and Caraffa Private Clinic, 24 patients with TNEs-GEP were surgically intervened. Of the total, 14 belonged to the female sex (58.3%) and the remaining 10 men (41.6%), with an age range between 20 and 82 years of age with an average of 55.3 years (Figure 1). Characteristics evaluated for tumours were age, sex, histological grade, and location in the digestive system.

The most common location of these lesions was 4 stomach

(16.6%), 14 patients in the intestine (58.3%), of which five were located in the cecal appendix, four in the ileo-cecal region, three in ileum, one in the ascending colon, and descending colon. Finally, 6 in the head of the pancreas (25 %) (Figure 2).

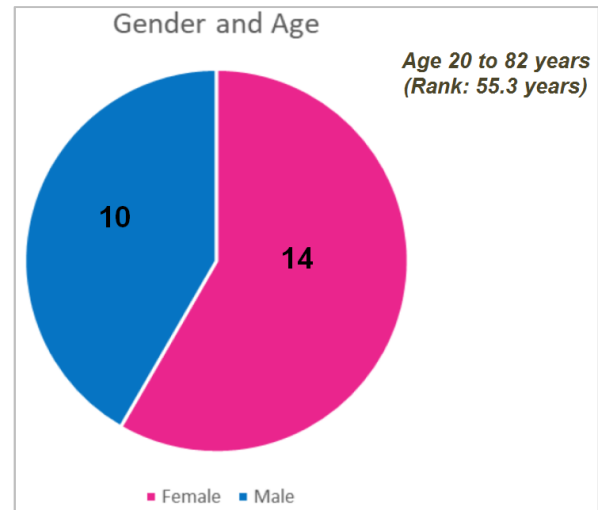


Figure 1. Gender and Age.

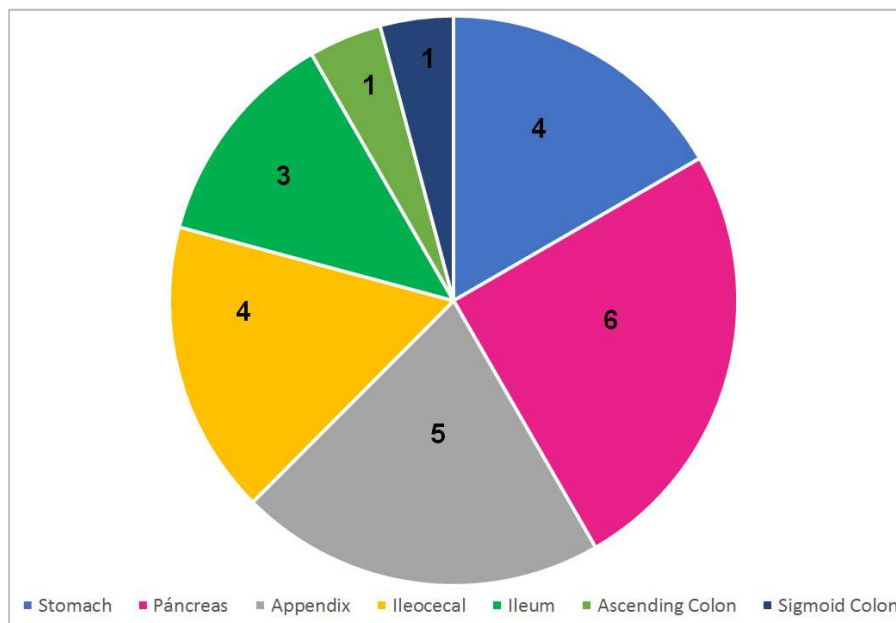


Figure 2. Location of lesions.

## 3. Results

With regard to lesion of stomach showed two of the male and two female. His clinical presentation was: anaemia, melena, and hematemesis. Endoscopy, Rx. of oesophagus, stomach and duodenum were performed. Abdominal CT. Centellogram with octreotid.

In both male and female patients in endoscopies, stoned images were shown due to polyps on the fundus and cardial region, where biopsies demonstrated: in one of them

proliferation of neoplastic cells of likely neuroendocrine and diffuse chronic gastritis. Immuo histochemical tests of Chromogranin (+) and Sipnatofysine (+) are performed, where a low-grade neuroendocrine tumour is suspected, in the same way as female females (GI type). In the other male, multiple polyps in the gastric body, extracting the largest with cold ansa with a biopsy indicating carcinoid tumour suggestive, Immuo histochemistry: Chromogranin (+), Ki 67 (+) was performed in 2%. Diagnosis is defined as well differentiated low-grade neuroendocrine carcinoma of the stomach (GI type). In all three, a total gastrectomy with

oesophageal-yeyunal anastomosis with mechanical suture and Roux's Y-foot anastomosis was performed with negative intraoperative biopsies of the edge of the oesophagus. The pathological anatomy of the surgical piece demonstrated in two of them, a low-grade neuroendocrine tumour. pT2 N0 and in the other demonstrated a well differentiated neuroendocrine carcinoma of low degree of aggression, multicentre with sub mucosa invasive and metastatic commitment in a minor omentum nodes. Staging: pT1, pN1.

In the fourth 82-year-old patient with a digestive haemorrhage, a endoscopy: demonstrates in the ceiling and antrum friable vegetating lesion with signs of necrosis and

traces of clots, where biopsies are performed. The pathological anatomy report reveals a neuroendocrine tumour. It is decided to perform a total gastrectomy with splenopancreatectomy. Oesophageal edge freezing biopsy that demonstrates neuroendocrine neoplasm focuses, dries again, and biopsy again being negative. The report on pathological anatomy: High-grade neuroendocrine carcinoma, measuring 10.5 x 9.3 x 1.5 cm. Metastasis in 1 ganglion. Mechanical suture anastomosis rings without lesions. The pathological anatomy showed pT3, N1. Finally according to the classification, the first three would be subtypes of gastric carcinoids or Type G 1 NETs and the remaining type G 3 (*Table 1*).

**Table 1.** Carcinoma Neuroendocrine Stomach tumours.

AGE	SEX	SYMPTOMS	REGION	TREATMENT	PATHOLOGY	EVOLUTION
56	M	Gastritis	Multiple polyps in Cardial and Stomach Fundus	Total Gastrectomy	Low-grade neuroendocrine tumour. (pT1 N0 M0)	Good. Live (7 years).
64	M	Gastritis	Multiple polyps in the stomach body	Total Gastrectomy	Low-grade multifocal neuroendocrine carcinoma. (pT1 N0 M0)	Good Live (3 years).
63	F	Pain epigastric	Polyps in Cardial and Fundus	Total Gastrectomy	Low-grade neuroendocrine carcinoma. 1 nodes (+) (pT2 N1 M0)	Good. Live (4 years)
82	F	Upper gastrointestinal bleeding	Tumour occupying the body and antral stomach	Total Gastrectomy	High-grade neuroendocrine carcinoma. Nodes metastases. (pT3 N1 M0)	Death.

In relation to bowel injuries, 8 belonged to the female sex and the remaining 6 to the male. In all these patients they were under-operated in urgency in the Central Guard Service. In the first location entered was for a painful right iliac pit syndrome on five occasions, there were four sub-occlusive tables whose preoperative studies revealed organic stenosis and in one added palpable tumour, in two cases by an acute intestinal occlusive picture. Finally, last one patient who had low digestive bleeding. In all cases the diagnosis of neuroendocrine tumour was made in the postoperative period through pathological anatomy as happened in most cases.

The 5 lesions of appendicular origin were all less than 1 cm, where an appendectomy was performed. The

pathological anatomy of the five appendectomy was further acute appendicitis, a low-grade neuroendocrine carcinoma (pT1 N0 M0) (Type G1). All five patients live (*Table 2*).

In lesions in the ileum- cecal region, in one of them the size of the tumour was 3 cm. infiltrating only to the muscle, it had no metastasis nodes, but in the right ovary. He performed right colectomy. Pathological anatomy showed low-grade neuroendocrine carcinoma, with metastases in the right ovary (pT2 N1 M0) (Type G1). This patient was re-operated at 10 years by abdominal hernia in which the omentum was found, being positive in the anatomy pathological report for metastasis of low-grade neuroendocrine carcinoma. Currently lives.

**Table 2.** Carcinoma Neuroendocrine of appendages.

AGE	SEX	SYMPTOMS	REGION	TREATMENT	PATHOLOGY	EVOLUCION
20	M	Pain in RLQ	Cecal Appendix	Appendectomy	Acute App. Suppurated + Low-grade Neuroendocrine Carcinoma. (pT1 N0 M0)	Good. Live
22	F	Pain in RLQ	Cecal Appendix	Appendectomy	Acute App. + Low-grade Neuroendocrine carcinoma. (pT1 N0 M0)	Good. Live
80	F	Pain in RLQ	Cecal Appendix	Appendectomy	Acute App. Suppurated * Low-grade Neuroendocrine carcinoma. (pT1 N0 M0)	Good. He died at age 3 (Stroke)
43	F	Pain in RLQ	Cecal Appendix	Appendectomy	Acute App. Suppurated + Low-grade microscopic neuroendocrine carcinoma (pT1 N0 M0)	Good. Live
33	M	Pain in RLQ	Cecal Appendix	Appendectomy	Acute App. + Low-grade Neuroendocrine carcinoma (pT1 N0 M0)	Good. Live

In the second case the size of the tumour was 4 cm. and possessed three liver metastases a right colectomy was performed and 3 sections of hepatic. The pathological specimen showed Mts High-grade neuroendocrine carcinoma, which died at 11 months (pT3 N1 M1) (Type G3). In the third, the surgical piece had 2 tumours lesions one 1 cm. and the other 0.5 cm well differentiated low grade with 7 nodes

metastases and the omentum compromised by neoplasm. A right colectomy was performed. Pathological anatomy showed low-grade neuroendocrine carcinoma (pT2 N1 M0) (Type G2) and living. The fourth cecal ileus tumour was also performed a right colectomy. Pathological anatomy demonstrated low-grade neuroendocrine carcinoma with 4 metastatic nodes (pT1 N1 M0) (Type G1) and has good evolution (*Table 3*).

**Table 3.** Carcinoma Neuroendocrine of the small intestine.

AGE	SEX	SYMPTOMS	REGION	TREATMENT	PATHOLOGY	EVOLUTION
82	F	Occlusive Syndrome	Íleocecal region	Right Colectomy + Resection of 3 hepatic Mts.	High-grade Neuroendocrine carcinoma with liver metastases. (pT3 N1 M1)	He died at 11 months
58	M	Sub Occlusive Syndrome	Íleocecal region	Right Colectomy with resection 15 cm of Ileum + mesenteric nodes.	Carcinoma Neuroendocrino de bajo grado con 7 ganglios metastásicos. (pT2 N1 M0)	Good. Live
75	F	Sub Occlusive Syndrome	Íleocecal region	Right Colectomy	Low-grade Neuroendocrine carcinoma with 4 nodes (+). (pT1 N1 M0)	Good. Live
27	F	Sub Occlusive Syndrome	Íleon	Intestinal resection with nodes mesenteric.	Low-grade Neuroendocrine carcinoma with 5 nodes (+) (pT2 N1 M0)	Good. Live.
57	M	Occlusive Syndrome	Íleon	Tumour at 60 cm of cecal valve. Bowel resection.	Low-grade Neuroendocrine carcinoma. (pT2 N0 M0)	Good. Live
68	F	Sub Occlusive Syndrome	Íleon	Tumour at 50 cm of ileus-cecal valve. More intraluminal lesions up to 1.20 cm.	Moderate-grade Neuroendocrine carcinoma with mesenteric nodes (+). Liver Mts. (pT2 N1 M1)	Good. Live

In the ileum lesions, one of them was at 50 cm. from the ileum-cecal valve and had nodes in mesentery, an ileum resection of 15 cm plus the resection of the nodes was performed. Pathological anatomy showed low-grade neuroendocrine carcinoma with 5 metastatic nodes (pT2 N1 M0) (Type G1), and currently living. In two other cases, intestinal occlusion, one performed an intestinal resection due to intra luminal tumour at 60 cm of ileum-cecal valve, performing anastomosis of the small bowel. Pathological anatomy showed low-grade neuroendocrine carcinoma (pT1 N0 M0) (Type G1) and live. Finally the other patient also with occlusive was found tumour at 50 cm of ileus-cecal valve, but in addition other intraluminal lesions were look and 1.20 cm thin with nodes in the mesentery that were resected, with liver metastases were met Moderately

concurrent neuroendocrine carcinoma currently alive. (pT2 N1 M1) (Type G2) (Table 3).

The ascending colon tumour was externalized, with node metastases and liver metastases in both lobes. A right colectomy was performed, with resection of 10 nodes in mesentery and liver metastases. High-grade neuroendocrine carcinoma (pT3 N1 M1) (Type G3), died at 5 months. Finally in the left colon injury was a finding in a surgical piece of subtotal colectomy by low digestive haemorrhage. a subtotal colectomy was performed for bilateral diverticulosis. Pathological anatomy showed a low-grade neuroendocrine carcinoma (pT1 N0 M0) (Type G1). He died at age 5 from an ACV. In all these cases because of the presentation of acute posts, the diagnosis of neuroendocrine tumour was postoperative through pathological anatomy. (Table 4).

**Table 4.** Carcinoma Neuroendocrine of the large intestine.

AGE	SEX	SYMPTOMS	REGION	TREATMENT	PATHOLOGY	EVOLUTION
48	M	Sub occlusive syndrome. Palpable tumour on right flank.	Ascending colon tumour	Right Colectomy. Nodes mesenteric and liver metastases.	High-grade neuroendocrine carcinoma. Mts in nodes and liver. (pT3 N1 M1)	He died at 5 months.
69	M	Low digestive haemorrhage and colon diverticulosis	Sigmoid colon	Subtotal Colectomy	Neuroendocrine carcinoma of low degree of left colon (pT1 N0 M0)	Good. He died at the age of 5. (Stroke)

**Table 5.** Carcinoma Neuroendocrine pancreatic tumours.

AGE	SEX	SYMPTOMS	REGION	TREATMENT	PATHOLOGY	EVOLUTION
27	F	Hypoglycaemia.	Pancreatic head	CPD	Benign Insulinoma	Good evolution. He died at the age of 8 from stroke.
60	M	Gastric ulcer with upper gastrointestinal bleeding	Pancreatic head	CPD	Benign gastrinoma	Good evolution. He died at the age of 5. Diabetes
79	F	Gastritis. High digestive haemorrhage.	Pancreatic head	CPD	Benign gastrinoma	Good evolution. He died at the age of 6. Stroke.
48	M	Jaundice. Weight loss.	Pancreatic head	CPD	Non-functioning low-grade neuroendocrine carcinoma. (pT1 N0 M0)	Good Evolution. He died at the age of 8. Diabetes.
56	F	Jaundice. Weight loss. Pruritus.	Pancreatic head	CPD with venous resection	Non-functioning low-grade neuroendocrine carcinoma. nodes (+) (pT1 N1 M0)	Good Evolution. He died at the age of 4. Diabetes. myocardial infarction
62	F	Weight Loss. Abdominal pain	Pancreatic head	CPD	Non-functioning low-grade neuroendocrine carcinoma. Nodes (+) (pT1 N1 M0)	Good Evolution. He died at the age of 5. Diabetes. myocardial infarction

The pancreatic lesions, 4 female and two male sex. Clinically this group, 3 patients had stroke, coluria, weight loss. The remaining three 2 had a digestive haemorrhage

picture and a hypoglycaemia picture. All were studied with endoscopy, abdominal ultrasound, abdomen CT and MNR.

In functioning neuroendocrine tumours there was 2 a

gastrinoma, and in another an Insulinoma. In the remaining three were non-functioning NETs, all were given a cephalic pancreateo-duodenectomy (CPD), which in one of them had a venous resection. Of non-functioning TNE, pathological anatomy demonstrated low-grade neuroendocrine carcinoma (pT1 N0 M0) (Type G1) and two neuroendocrine carcinomas with nodes. (pT1 N1 M0) (Type G1) (Table 5).

In functioning tumours of the pancreas, in the two gastrinomas and the Insulinoma died between 60 months and 96 months (average: 80 months) in two A.C.V. and another from diabetes and its complications. For non-functioning tumours, all 3 patients died between 48 and 96 months (average: 64 months), in one of them had neuroendocrine carcinoma that had partial venous resection and died of an I.A.M. the other two from a TEPA and an I.A.M. Respectively (Table 5).

## 4. Discussion

The NETs-GSP is rare and originates from the endocrine system located in the gastrointestinal tract (carcinoids) and in the pancreas (insular tumours) with a variety of clinical presentations [6]. In the past, these tumours were classified according to embryological origin [7] into three distinct groups A) Carcinoids derived from the upper digestive tract (foregut), located in the stomach, proximal duodenum, biliary and pancreatic tract, related to the celiac tripod. B) Carcinoids of the middle digestive tract (midgut) located in the terminal duodenum, small intestine, appendix and right colon, related to the upper mesenteric artery. C) Carcinoids of the distal intestine (hindgut) located in descending colon, sigmoid and rectum, dependent on the lower mesenteric artery.

The recent WHO classification [8] has allowed to categorize all NETs-GSP on the basis of anatomy-pathological criteria that are as follows: 1. Well differentiated endocrine tumours, benign (G1). 2. Endocrine carcinomas well differentiated, with a low degree malignancy (G2). 3. Poorly differentiated endocrine carcinoma, with a high degree of malignancy (G3). Each category can include functioning and non-functioning tumours. On the other hand, a TNM classification has been developed for neuroendocrine tumours [9].

Gastro-enteric-pancreatic endocrine neoplasms are a group of rare but possible tumours, the distribution of which is uneven within the gastrointestinal tract. According to Kloppel in 2007 [1] the most frequent location of the same occurs in stomach, ampulla region, appendix, terminal ileum and pancreas, in accordance with what we found in our own cases, although there is no exact typical pattern of age distribution location that can be applied to all countries equally.

The average age in our case series was slightly lower, compared to some European countries (France, Spain, Germany), with 55.3 years versus around 56 [4]. As for the location, we find a similarity in the high frequency of appearance in pancreas, which in our series reached 25%,

similar to the group of Lebanon [2], but less to Germany, France [4] and China [1]. In the latter it reached 40% and the appearance of large tumours was also detailed. It is worth noting the high frequency of appearance in the region Oil cecal and appendicular, which together would reach 37% in our series.

As for the solitary appendix, we got a presentation close to 21%, but higher than the rest of the countries [10, 11]. The percentages found in small bowel resembled those in Germany, although not all groups measured the impact in that area [4, 12-13]. We found similarities to world literature also in large intestine with a presentation close to 8%, although we had no cases in rectum, detailed in several studies [14, 15]. In the Chinese study, the percentage of large intestine involvement was much higher, reaching 40% [1].

As for the degree of differentiation most tumours were a type G1. In ileum-cecal region lesions we were able to find 3 tumours that corresponded to a G2, which shows a high percentage of these, although the cases limited to the appendix were all G1 lesions. With respect to the G3 classification, only two patients had this type of differentiation, one in the stomach and one in the ascending colon. Pancreatic tumours were treated G1.

In relation to remote metastases and node tissue involvement, the study group in China found a logical negative relationship between the onset of these factors and the survival of patients. In our series of cases and differentiated by location, in the stomach there was no metastasis at a distance, but two of the patients had N1, in which one of them remained long survived. In the gut we found 3 patients with nodes involvement who kept on battery out, and 3 patients with metastases, two in liver (deceased) and one in right ovary that currently lives. There was no nodes affectation or metastasis in appendix lesions.

In pancreatic lesions, of the 6 patients two had nodes involvement and the remote survival was an average of 7 years for the functioning, and 5 years for non- functioning. It should be noted that, in order to make an objective comparison of survivals and affectations our patient N should increase and unify criteria.

## 5. Conclusion

NETs-GSP are a relatively rare pathology, but it has begun to increase frequency, in the last decade, due to the appearance and improvement in imaging methods, allowing an increase in the preoperative presumption that will surely involve further resections of such tumours. This will make the surgeon should know them and keep them within their diagnostic thinking. Likewise, the surgeon, in the urgency, should know that knowing this pathology and especially those located in both the small intestine and the large intestine, to adopt a correct therapeutic behaviour in accordance with WHO guidelines. On the other hand, neither minimizes this pathology and keeps it always present in different situations not only in the urgency.

---

## References

- [1] Klöppel G, Rindi G, Anlauf M, et al (2007): Site-specific biology and pathology of gastroenteropancreatic neuroendocrine tumors. *Virchows Arch.* 451: 9-27.
- [2] Kourie HR, Ghorra C, Rassy M, et al (2016): Digestive Neuroendocrine Tumour Distribution and Characteristics According to the 2010 WHO Classification: a Single Institution Experience in Lebanon. *Asian. Pac. J. Cancer. Prev.* 17 (5): 2679-2681.
- [3] Rindi G (2010): The ENETS guidelines: the new TNM classification system. *Tumori.* 96: 806-809.
- [4] Scoazec JY, Couvelard A (2011): The new WHO classification of digestive neuroendocrine tumors. *Ann Pathol.* 31: 88-92.
- [5] Kloppel G. (2011): Classification and pathology of gastroenteropancreatic neuroendocrine neoplasms. *Endocr. Relat. Cancer.* 18: 1-16.
- [6] Massironi S, Sciola V, Peracchi M, et al (2008): Neuroendocrine tumors of the gastro-entero-pancreatic system. *World. J. Gastroenterol.* 14 (35): 5377-5384.
- [7] Williams ED, Sandler M (1963): The classification of carcinoid tumor's. *Lancet.* 1: 238-239.
- [8] Klimstra DS, Modlin IR, Coppola D, et al (2010): The pathologic classification of neuroendocrine tumors: a review of nomenclature, grading, and staging Systems. *Pancreas.* 39 (6): 707-712.
- [9] Solcia E, Klöppel G, Sobin LH (2000). *Histological Typing of Endocrine Tumors. WHO International Histological Classification of Tumors.* 2nd ed. Berlin: Springer: 56-70.
- [10] Brighi N, La Rosa S, Rossi G, Grillo F, Pusceddu S, Rinzivillo M, et al (2020): Morphological Factors Related to Nodal Metastases in Neuroendocrine Tumors of the Appendix: A Multicentric Retrospective Study. *Ann. Surg.* 271 (3): 527-533.
- [11] Mullen JT, Savarese DMF.: Carcinoid tumors of the appendix: a populationbased study. *J. Surg. Oncol.* 2011. 104: 41-44.
- [12] Wu L, Fu J, Wan L, Pan J, Lai S, Zhong J, et al (2017): Survival outcomes and surgical intervention of small intestinal neuroendocrine tumors: a population based retrospective study. *Oncotarget.* Vol. 8 (3): 4935-4947.
- [13] Bösch F, Bruewer K, D'Anastasi M, Guba M, Werner J, Angele MK, et al (2018): Neuroendocrine tumours of the small intestine causing a desmoplastic reaction of the mesentery are a more aggressive cohort. *Surgery* 164 (5): 1093-1099.
- [14] Northrop JA, Lee JH (2007): Large Bowel Carcinoid Tumours. *Curr. Opin. Gastroenterol.* 23 (1): 74-78.
- [15] Calvo Hernán F, Ortiz Bellver v, Berenguer Lapuerta J (2002): Tumor y síndrome carcinoide. *Revis Gastroenterol.* 4: 219 – 226.