



A Critical and Systematic Review of *Lymphatic filariasis* (Elephantiasis): A Neglected Tropical Disease (NTD) That Affects Negatively Agricultural Activities Across the World

Kubkomawa Hayatu Ibrahim^{1,*}, Kenneth-Chukwu Oluchi Margret², Iyiola Vivian Ogechi³, Anyanwu Vivian Chinenye⁴

¹Department of Fisheries Technology, Federal Polytechnic, Mubi, Nigeria

²Department of Veterinary Biochemistry and Animal Production, College of Veterinary Medicine, Micheal Okpara University of Agriculture, Umudike, Nigeria

³Department of Animal Production and Health, Federal University, Wukari, Nigeria

⁴Department of Animal Science and Technology, Federal University of Technology, Owerri, Nigeria

Email address:

kubkomawa@yahoo.com (K. H. Ibrahim)

*Corresponding author

To cite this article:

Kubkomawa Hayatu Ibrahim, Kenneth-Chukwu Oluchi Margret, Iyiola Vivian Ogechi, Anyanwu Vivian Chinenye. A Critical and Systematic Review of *Lymphatic filariasis* (Elephantiasis): A Neglected Tropical Disease (NTD) That Affects Negatively Agricultural Activities Across the World. *International Journal of Biomedical Materials Research*. Vol. 9, No. 2, 2021, pp. 13-17. doi: 10.11648/j.ijbmr.20210902.11

Received: June 20, 2021; Accepted: June 30, 2021; Published: July 9, 2021

Abstract: The objective of the study is to carry out a critical and systematic review of *Lymphatic filariasis* (elephantiasis) as one of the neglected tropical diseases (NTD) that affects negatively agricultural activities in the world. It is also to remind people of existence of the disease, create awareness for its prevention and elimination. This effort could go a long way to averting unnecessary suffering, save production work force and aid in poverty alleviation in the tropics. *Lymphatic filariasis* happens when infested mosquito bites humans to transmit filarial parasites. The parasites cause blockages in the lymphatic system that stops or inhibits the return of fluids to the circulatory system. This results in fluid accumulation in the tissues (legs, hands (arms), breast and scrotums), causing swellings and periodic fevers with frequent fungal and bacterial infections. *Lymphatic filariasis* is one of the leading causes of permanent and long-term disability in tropical countries of the world. It affects all classes of people irrespective of age, gender, race, educational and economic status. This disease reduces the production capacities of infected individuals especially in the area of agro-allied businesses worldwide. The time and resources wasted for the treatment and management of the infection affect food production negatively. There are about 1.1 billion people in 80 countries at risk of contracting this disease while 120 million people are infected globally. The disease is a serious life threatening with negative consequence on drivers of the economy. The patients are not only physically disabled, but also suffer psychological, social and financial crisis in addition to trauma from stigma and poverty. It is worthy to note that, the local cure of *Lymphatic filariasis* has been found and now available at Kwargashe Village, Lala District, Gombi Local Government Area of Adamawa State, Nigeria.

Keywords: *Lymphatic filariasis*, Neglected Tropical Disease, Prevention, Elimination, Agriculture

1. Introduction

Lymphatic filariasis (elephantiasis) is one of the neglected tropical diseases which occur when filarial parasites are transmitted to humans through mosquito bites [3, 5, 16, 23]. Infected mosquito deposits microscopic larvae while biting a

victim [3, 4]. The larvae migrate to the human lymphatic system and mature into adult worms [2, 4, 10]. These worms cause blockages in the lymphatic system that prevents the return of fluids to the circulatory system [2, 4, 10]. The initial symptom of lymphatic dysfunction is a mild edema, that is fluid accumulation in the tissues mostly the legs and hands (arms), which may gradually progress to elephantiasis if not

treated with periodic fevers, fungal and bacterial infections [3, 1, 8].

Lymphatic filariasis also affects the male and female external genital organs [8]. In a male, it involves enlargement of the scrotum and the penis retracted under skin which becomes thickened, nonelastic, hot and painful. The spermatic cords get thicken and the affected individuals experience pains and burning sensations [6, 8]. The external parts of the female genital organs (vulva) can also be infected by elephantiasis. A tumorous mass covered by thickened and ulcerated skin may develop between the thighs and may be accompanied by enlarged lymph nodes (lymphadenopathy) of the legs. In some women the enlargement of the breasts are also common [6, 8].

The disease is common in tropical and sub-tropical countries of the world for examples, Africa, India, South America and Southeast Asia [6, 9]. In the year 2019, approximately 859 million people in 50 countries were living in areas that require preventive chemotherapy to stop the spread of infection [5, 12]. The global estimate of people affected by *Lymphatic filariasis* was 25 million men with hydrocele (scrotal swellings) and over 15 million people with lymphedema or tissue enlargement [3, 5, 12].

The objective of the study is to carry out a critical and systematic review of *Lymphatic filariasis* (elephantiasis) as one of the neglected tropical diseases (NTD) that affects negatively agricultural activities in the world. It is also to remind people of existence of the disease, create awareness for its prevention and elimination. This effort could go a long way to averting unnecessary suffering, save food production work force and aid in poverty alleviation in the tropics.

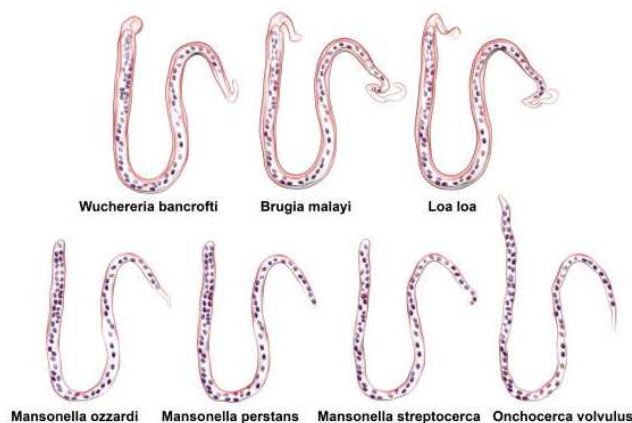
2. Causes and Transmission of *Lymphatic filariasis*

Lymphatic filariasis is caused by infection with parasites known as nematodes (roundworms) belonging to the family of Filariodidea [3, 5, 20]. The three types of these thread-like filarial worms include: *Wuchereria bancrofti* which is responsible for 90% of the infections while *Brugia malayi* and *Brugia timori* caused 10% of the disease as shown in figure 1 [2, 5, 18].

The adult worms dwell in the lymphatic vessels and disrupt the normal function of the lymphatic system [2, 4]. The lymph system maintains fluid balance in the body and fights infections. These worms can live for almost about 6–8 years and, during their life time, produce millions of microfilariae (immature larvae) that circulate in the blood [3, 5, 11].

Mosquitoes can be infected with microfilariae through ingestion of blood when biting an infected host [2, 7]. Microfilariae mature into infectious larvae within the mosquitoes. When the infected mosquitoes bite people, the mature parasite larvae are deposited on the skin from where they can enter the body [2, 4, 7]. The larvae then migrate to the lymphatic vessels where they develop into adult worms,

therefore continue a cycle of transmission as shown in figure 1 [3, 5, 7]. *Lymphatic filariasis* is transmitted by different types of mosquitoes for example by the *Culex* mosquito, widespread across urban and semi-urban areas, *Anopheles*, mainly found in rural areas, and *Aedes*, mainly in endemic islands in the Pacific [2, 3, 7] as shown in figure 2. *Lymphatic filariasis* can spread from person to person by mosquitoes.



(Source: gettyimages.com)

Figure 1. Nematodes (roundworms) that cause *Lymphatic filariasis* (elephantiasis).

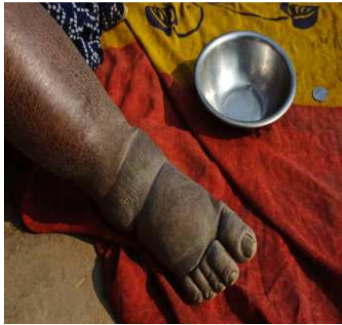

(Source: gettyimages.com)

Figure 2. Mosquito the vector of *Lymphatic filariasis*.

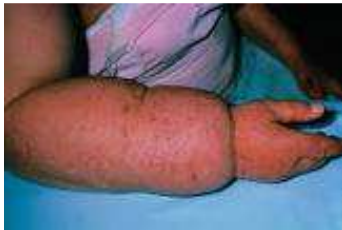3. Symptoms of *Lymphatic filariasis*

Lymphatic filariasis infection involves asymptomatic, acute and chronic conditions with most of them showing no external signs but transmission of the parasites goes on [3, 17]. These asymptomatic infections still cause damage to the lymphatic system, the kidneys and alter the body immune system [4, 5, 7]. The lymphatic system is one responsible for the removal of waste and toxins [9]. When becomes blocked, does not perform its functions properly [9]. This leads to a backup of lymphatic fluid, which causes swelling of the legs, hands (arms), breast, genital organs and scrotum (hydrocele) accompanied by frequent fever. The skin is also affected and may be dry, thick, ulcerated, darkened and pitted (hyperkeratosis) as shown in figures 3, 4, 5 and 6 [2, 6, 9].



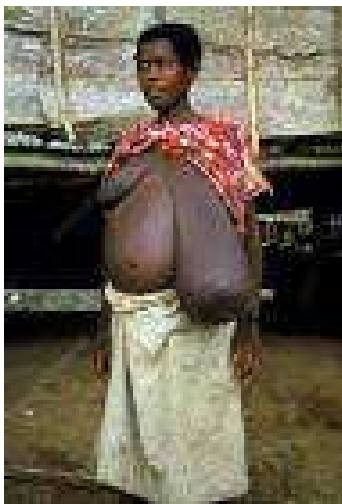(Source: gettyimages.com)

Figure 3. *Lymphoedema (swollen leg).*




(Source: Facebookdoctor.wordpress.com)

Figure 4. *Lymphoedema (swollen hand).*



(Source: www.sciencephoto.com)

Figure 5. *Lymphoedema (swollen breast).*



(Source: gettyimages.com)

Figure 6. *Lymphoedema (swollen scrotum).*

When the condition persists unattended to, gets severe resulting to elephantiasis (thickening of the skin/tissue). The acute infections are debilitating, may last for months and years [3, 5]. The severe inflammation of skin, lymph nodes and lymphatic vessels often accompany chronic lymphoedema or elephantiasis [2, 7]. Few of these conditions are caused by the body's immune response to the parasite. These are the result of secondary fungal and bacterial infections of the skin where normal defenses have been lost due to lymphatic damage [3, 4, 5, 7].

4. Negative Impact of *Lymphatic filariasis* in Agricultural Activities

Health is wealth and agribusiness involves the use of physical and mental energy to cultivate crops and rear farm animals for useful purposes. Wealth creation can never be achieved when there is no sound physical and mental health because a sick person may lose appetite, passion and interest for food and almost all kind of investments in life. The manifestation of *Lymphatic filariasis* results in accumulation of fluid in the tissues especially the legs, hands (arms), breasts and scrotums. This causes the affected parts to swell-up making them bulky and lumpy with stiff, tough skin, accompanied with pains, periodic fevers, frequent fungal and bacterial infections [3, 1].

Furthermore, body deformities because of the infection makes the affected parts heavy, difficult to move and farm work becomes a nightmare. Affected individuals are unable to work because of their disabilities and this clamps down on the economy of their families and communities. The patients are not only physically disabled, but also suffer psychological and social stigma [3, 5, 13, 19, 22]. These bring about primary causes of lost income (employment opportunities) and increased medical expenses for patients and their families [2, 4, 7]. The money supposed to be meant for family upkeep and or invested in agriculture and other profitable occupations is used for the treatment and management of the disease causing socio-economic burdens and poverty [5]. The crop produce and livestock harnessed by the infected patients may be sold at a giveaway price just for the management of the infection. The entire community may shun and reject people disfigured by this disease.

Most patients are often infected from childhood with consequential hidden damage to the lymphatic system [4, 5]. This protracted illness causes painful and overwhelmingly disfiguring elephantiasis (lymphoedema and scrotal swelling) occurs later in life and leads to permanent disability [4, 5, 7]. This situation puts the infected individuals into serious precarious predicament that hinders them from concentration in their daily agricultural activities and other economic ventures.

Research has shown that, about 36 million people live with these chronic disease manifestations for years, if not for live irrespective of the treatment and management strategies which in turn affect negatively the agricultural sector in the world [2, 7]. Recent study also shows that, there are about

1.1 billion people in 80 countries at risk of contracting this disease while 120 million people are already infected globally [3, 1, 10]. This called for serious sense of concern by the immediate authorities to save the production work force to ensure food security across tropical countries of the world.

5. Treatment (Preventive Chemotherapy) of *Lymphatic filariasis*

Treatment and elimination of *Lymphatic filariasis* is possible when diagnosis is carried out early with correct use of conventional and traditional medicines (plant parts). The conventional therapy appears to have no much effect on the disease especially when complications have set in or it has become elephantiasis [5].

Preventive chemotherapy for *Lymphatic filariasis* elimination is also possible thorough mass drug administration, MDA [2, 4, 7]. This involves administration of medicines to the entire at-risk population annually for 4 to 6 years [3, 4, 7]. The medicines have a limited effect on adult parasites but effectively reduce the density of microfilariae in the bloodstream and prevent the spread of parasites to mosquitoes [5, 14].

The following MDA regimens are recommended: albendazole (400 mg) alone twice per year for areas co-endemic with loiasis, ivermectin (200 mcg/kg) with albendazole (400 mg) in countries with onchocerciasis, diethylcarbamazine citrate (DEC) (6 mg/kg) and albendazole (400 mg) in countries without onchocerciasis [3, 5, 7]. Recent study indicates that, the combination of all three medicines can safely clear almost all microfilariae from the blood of infected people within weeks, as opposed to years using the routine two-medicine combination [5, 7]. Other treatment measures include using good hygiene to clean the affected areas, elevating the affected areas, caring for wounds in the affected areas, exercising based on a doctor's directions, surgery in extreme cases, which may include reconstructive surgery for the affected areas or surgery to remove affected lymphatic tissue and emotional and psychological support [6, 9].

Research has shown that, seventeen countries namely, the Cambodia, Cook Islands, Egypt, Kiribati, Maldives, Malawi, Marshall Islands, Niue, Palau, Sri Lanka, Thailand, Togo, Tonga, Vanuatu, Viet Nam, Wallis and Futuna, and Yemen) are on their way to achieving elimination of *Lymphatic filariasis* [3, 5, 12].

6. Morbidity Management of *Lymphatic filariasis*

The disease management and disability prevention are very vital to improving public health and are essential services that should be provided by the health care delivery to ensure sustainability [3, 7]. Most cases of hydrocele (scrotal swelling) can be managed through surgery. Clinical severity and progression of the disease, including acute

inflammatory cases, can be reduced and prevented with simple measures of hygiene, skin care, exercises and elevation of affected limbs [2, 11]. People with lymphoedema must have access to continuing care throughout their lives, both to manage the disease and to prevent progression to more advanced stages [5, 11].

7. Vector Control of *Lymphatic filariasis*

Control of mosquito is the cheapest way to reduce *Lymphatic filariasis* transmission and other mosquito-borne infections [3, 4]. Control measures such as insecticide-treated nets, indoor residual spraying may help protect people from infection [4, 5, 15, 21]

8. Conclusion and Recommendations

Lymphatic filariasis is one of the leading causes of permanent and long-term disability in tropical and sub-tropical countries (Africa, India, South America and Southeast Asia). It is a stubborn and resistant disease caused by parasites transmitted through infected mosquitoes. The disease causes damage to the lymphatic system, the kidneys and alters the body immune system leading to lymphoedema (tissue swelling or enlargement). The body deformities often result to severe pains, social stigma and mental health, anxiety, depression, which are the primary causes of lost income (earning opportunities in agricultural production, manufacturing and other businesses) and increased medical expenses for patients and their caretakers. Treatment and elimination of *Lymphatic filariasis* is possible when early diagnosis is carried out. Preventive chemotherapy for *Lymphatic filariasis* elimination is also possible thorough mass drug administration (MDA).

Management of *Lymphatic filariasis* is really difficult especially when the condition has become elephantiasis (thickening of tissues and skin). It is interesting to note that, the research team has discovered the local cure of *Lymphatic filariasis* at Kwargashe Village, Lala District, Gombi Local Government Area of Adamawa State, Nigeria. This involves oral administration of traditional medicine (plant parts) and robbing same on the affected parts after draining the damage fluid and black blood through the use of razor blade. Proper vector control should be employed to reduce *Lymphatic filariasis* transmission and other mosquito-borne infections.

References

- [1] CC (2012). The Carter Center. *Lymphatic Filariasis* Elimination Program.
- [2] CDC (2018). Centers for Disease Control and Prevention. CDC twenty four seven. Saving Lives, Protecting People. U.S. Department of Health & Human Services.
- [3] Murrell, D. (2018). Medically reviewed by Daniel Murrell, M.D. — Written by Jayne Leonard on May 14, 2018.

- [4] WebMD (2020). WebMD Medical Reference. Reviewed by Carol DerSarkissian, MD on June 14, 2020.
- [5] WHO (2021). World Health Organization publishes materials that aim to provide high-quality care to people affected by *lymphatic filariasis*, 5 March, 2021.
- [6] William, M. (2019). Medically reviewed by William Morrison, M.D. Written by Lana Bandoim. Updated on April 16, 2019.
- [7] Gloviczki, P. (1995). The management of Lymphatic disorders. In Rutherford RB (ed.). Vascular surgery (4th ed.). Philadelphia: WB Saunders. pp. 1883–1945.
- [8] Pfarr, K. M., Debrah, A. Y., Specht, S., & Hoerauf, A. (2009). *Filariasis and lymphoedema*. Parasite Immunology. 31 (11), 664–72.
- [9] WHO (2010). World Health Organization. Progress report 2000-2009 and strategic plan 2010-2020 of the global programme to eliminate *Lymphatic filariasis*: halfway towards eliminating *Lymphatic filariasis*.
- [10] WHO (2020). World Health Organization. *Lymphatic filariasis*: reporting continued progress towards elimination as a public health problem.
- [11] Ottesen, E. A., Hooper, P. J., Bradley, M., & Biswas, G. (2008). The global programme to eliminate *Lymphatic filariasis*: health impact after 8 years. PLOS Neglected Tropical Diseases. 2 (10), 317.
- [12] WHO (2017). World Health Organization. Congratulations, Tonga! Pacific island state eliminates *Lymphatic filariasis* as a public health problem.
- [13] CDC (2013). Centers for Disease Control and Prevention. Parasites -*Lymphatic Filariasis* Diagnosis, 14 June 2013.
- [14] CDC (2010). Centers for Disease Control and Prevention. *Lymphatic Filariasis*.
- [15] CDC (2008). Centers for Disease Control and Prevention. *Lymphatic Filariasis*.
- [16] WHO (2014). World Health Organization. *Lymphatic filariasis* Fact sheet Number 102 March 2014.
- [17] CDC (2016). Centers for Disease Control and Prevention. *Lymphatic Filariasis*.
- [18] CC (2008). The Carter Center. *Lymphatic Filariasis* Elimination Program.
- [19] WHO (2021). World Health Organization. *Lymphatic filariasis*.
- [20] WHO (2016). World Health Organization. *Lymphatic filariasis*.
- [21] BBC (2010). BBC News. End in sight for elephantiasis, 8 October 2008.
- [22] GBD (2015). Global Burden of Disease. Disease and Injury Incidence and Prevalence Collaborators. Lancet. 388 (10053), 1545–1602.
- [23] Carlson, E. (2013). Taking the 'Bite' Out of Vector-Borne Diseases - Inside Life Science Series - National Institute of General Medical Sciences.