



# Cutaneous Mastocytosis in an 8-year-old Child: Case Report and Review of the Literature

Tsveta Kalinova<sup>1</sup>, Valentina Broshtilova<sup>2</sup>, Yoanna Velevska-Vatova<sup>1</sup>, Sonya Marina<sup>3,\*</sup>

<sup>1</sup>Department of Infectious Diseases, Parasitology and Dermatovenereology, Faculty of Medicine, Medical University of Varna, Varna, Bulgaria

<sup>2</sup>Department of Skin and Venereal Diseases, Military Medical Academy, Sofia, Bulgaria

<sup>3</sup>Medical Institute, Ministry of Internal Affairs, Sofia, Bulgaria

## Email address:

soniamarina1@yahoo.com (Sonya Marina)

\*Corresponding author

## To cite this article:

Tsveta Kalinova, Valentina Broshtilova, Yoanna Velevska-Vatova, Sonya Marina. Cutaneous Mastocytosis in an 8-year-old Child: Case Report and Review of the Literature. *International Journal of Clinical Dermatology*. Vol. 5, No. 1, 2022, pp. 1-5.

doi: 10.11648/j.ijcd.20220501.11

Received: August 10, 2022; Accepted: August 30, 2022; Published: September 14, 2022

**Abstract:** *Background:* Mastocytosis is a clinical condition occurring from birth to adulthood. It mainly involves the skin solely or in association with other organs such as the liver, bone marrow, spleen and lymph nodes. A bimodal distribution presenting in children from birth to 2 years of age and in patients older than 15 is commonly described. *Case Information:* An eight-year-old male patient presented with macules and papules on the trunk and limbs for 6 months. The rash worsened after bathing and physical activity. *Results:* The symptoms were compatible with cutaneous mastocytosis and confirmed histologically. *Conclusion:* Patients with mastocytosis may be asymptomatic or have symptoms due to mast cells degranulation – itch, flush, headache, syncope, gastrointestinal complaints of abdominal pain and diarrhea. Diagnosis of cutaneous mastocytosis is based on clinical morphology of skin lesions, positive Darier's sign and histological skin lesions stained for tryptase and/or CD117. Therapeutic management involves avoiding triggers, H1-/H2- receptor blockers and symptomatic medications. All patients with cutaneous mastocytosis require regular follow-up examinations.

**Keywords:** Mastocytosis, Child, Urticaria Pigmentosa, Cutaneous Mastocytosis

## 1. Introduction

Mastocytosis is a rare occurring heterogenous group of clinical conditions due to abnormal mast cells accumulation in the skin and other organs (liver, spleen, bone marrow, bones and gastrointestinal tract). Some authors described it as a neoplastic disease involving mast cells and their progenitors CD34+ [1]. Mastocytosis is a relatively rare disease with annual incidence 1:1 000-8000 to 10-13:100 000 and 2:300 000 in France [2, 3] and has a bimodal distribution according to the affected age – from birth to 2 years of age and in patients over 15 [4].

It is thought that alteration in KIT-structure and activity is responsible for the mastocytosis pathogenesis. The most common genetic abnormality in patients with sporadic mastocytosis is a somatic mutation involving codon 816 of the c-KIT gene that leads to a substitution of the amino acid

aspartic acid with valine or another amino acid. The given mutations are activating mutations that activate ligand-independent receptors [5, 6].

Many children and adults have few, if any, symptoms. In symptomatic patients the symptoms are variable due to the multiple physiological effects of mast cells and their mediators. The complaints may range from itch, flushing, dizziness, palpitation and syncope to abdominal pain and diarrhea. Interesting fact is the absence of pulmonary symptoms in mastocytosis. Nonspecific but important symptoms are fever, general malaise, weight loss, night sweats, bone pain, epigastric distress and cognitive alteration signaling extracutaneous involvement of the disease. Exitus letalis is a relatively rare complication but it is described in both children and adults due to extensive mast cell mediator release [5].

Symptoms of mastocytosis are exacerbated by physical activity, heat or hot shower and local traumatism to skin

lesions. It is established that alcohol and some drugs are implicated in precipitating the symptoms (narcotics, salicylates, NSAIDs, polymyxin B and anticholinergic drugs) [5].

Management of mastocytosis is based on avoidance of triggers and treatment with H1- and H2 – antihistamines [3]. All children with mastocytosis require follow-up examinations.

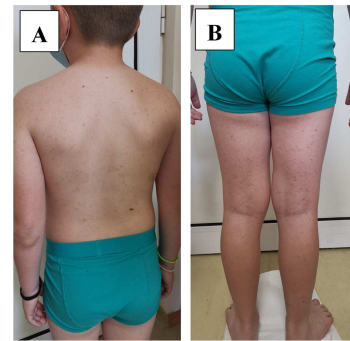
## 2. Case Report

A 8-year-old male patient reported to the outpatient department of Dermatology and Venereology with a chief complaint of itchy disseminated bumps and spots on the trunk and limbs for the past 6 months. The rash aggravated on bathing and physical activity. The patient and the parents denied any systemic complaints as well as edema of the eyelids, lips or tongue. His past medical and family history were not significant, and his parents did not give any history of long-term drug intake, nutritional supplements and local medications. No known history of drug allergy.

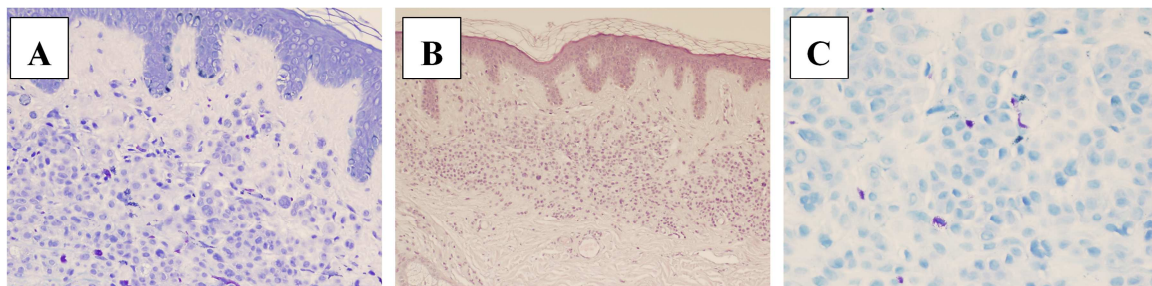
On physical examination symmetrical, disseminated yellow-tan to red-brownish macules and papules were established on the trunk and distal extremities. There was no

mucosal or soft tissue involvement (figure 1 - A, B).

An informed consent was obtained from patient's parents for further investigations. The complete blood tests showed normal values. The histopathological examination revealed orthokeratosis with horizontal alternating parakeratosis, uneven acanthosis, hypermelanosis in lower epidermal segment, moderate interstitial and perivascular round cell infiltrate in upper dermis with large kidney-like cells, stained with toluidine blue (figure 2 – A, B, C).



**Figure 1.** (A, B) Skin lesions are presented with symmetrical, disseminated yellow-tan to red-brownish macules and papules were established on back and upper limbs and trunk (A), lower limbs (B).



**Figure 2.** (A, B and C) Histopathological sections at 10x (A) and 40x (B) magnification shows orthokeratosis with horizontal alternating parakeratosis, uneven acanthosis, hypermelanosis in lower epidermal segment, moderate interstitial and perivascular round cell infiltrate in upper dermis with large kidney-like cells, stained with toluidine blue (C).

## 3. Discussion

Cutaneous mastocytosis (urticaria pigmentosa) is described for the first time by E. Nettleship and W. Tay in 1869 [7]. In 1877, P. Ehrlich discovered mast cells and in 1878 and A. Sangster suggested the name “urticaria pigmentosa”. It is thought that R. Unna was the first scientist who demonstrated that mast cells are responsible for the cutaneous findings in patients with mastocytosis. The first report of mastocytosis after childhood is described by Living in 1881. In 1936, french authors firstly described a systemic involvement in mastocytosis [7, 8].

Mastocytosis in children easily can be mistaken for a variety of common cutaneous conditions typical for paediatrics.

According to the World Health Organization (WHO) classification of mastocytosis (2016), the spectrum of mastocytosis includes the following categories: cutaneous mastocytosis (CM), systemic mastocytosis (SM), and mast

cell sarcoma (MCS) [9, 10, 11].

The present article is focused mostly on cutaneous mastocytosis in children.

There exist three main types of cutaneous mastocytosis – urticaria pigmentosa (UP), diffuse cutaneous mastocytosis (DCM) and solitary mastocytoma. When mast cells degranulate extracutaneously the condition is classified as systemic mastocytosis [3, 4, 6, 12].

In CM mast cells mostly accumulate in the skin and in SM – extracutaneous organs and bone marrow are involved (11).

The most common type of mastocytosis in children is cutaneous mastocytosis characterized with cutaneous mast-cell hyperplasia. In 55% of cases, it affects children from birth to 2 years of age, in 10% in children younger than 15 years old and in 35% - over 15 years of age [6, 12]. Most of the times, the disease regresses around puberty [3, 12]. However, in some patients, mastocytosis can persist into adulthood and may occur with systemic involvement. In children with mastocytosis mast cell mediator-related symptoms are possible. In patients with extensive skin

lesions and blistering severe hypersensitivity reactions are described [3].

### 3.1. Pathogenesis

Pediatric mastocytosis occurs as a result of clonal proliferation due to somatic gain-of-function mutations in the gene KIT. Consequently, stem cell factor-independent activation and phosphorylation of KIT occur resulting in mast cells differentiation, enhanced survival and their subsequent accumulation in various organs [9, 10, 11, 13]. Generally, mastocytosis is not an inherited disease [3, 14].

### 3.2. Clinical Types

The general classification of CM shows three main types of cutaneous mastocytosis: maculopapular CM (MPCM), diffuse cutaneous mastocytosis (DCM) and mastocytoma of the skin [15, 16].

Maculopapular cutaneous mastocytosis (MPCM) is the most common type in any age [17]. In children it occurs within the first 6 months of life. Children may present with monomorphic or polymorphic variant of the disease [18, 19].

Monomorphic variant of MPCM presents with small, round, mostly flat, brown or red maculopapular lesions, which typically show a central, symmetrical distribution on the body and classically spare the central face, palms, and soles [20, 21].

Polymorphic variant of MPCM presents with large, brown to dusky red skin lesions with variable size and asymmetrical distribution. A very typical feature of polymorphic variant is the involvement of the head, lateral parts of the forehead, neck and extremities [20, 21].

It is established that the skin lesions in children regress around puberty [3]. Patients with polymorphic variant are more prone to spontaneous regression while in monomorphic variant, mastocytosis may persist into adulthood.

The second type of CM is mastocytoma. This type occurs mostly in infants. It is manifested with a single tan- to brown, dusky red or yellow macule or nodule on the trunk, sharply demarcated from the surrounding area, with size 1-10 cm in diameter [15, 18]. Similar to other types of CM, mastocytoma also shows Darier's sign after rubbing and blistering due to mechanical irritation [3]. Mastocytomas are benign lesions with spontaneous regress before puberty.

According to the latest recommendations, the term cutaneous mastocytoma may be used in the presence of up to three lesions. When four or more lesions of this nature are found, MPCM is diagnosed [15].

The third type of CM is DCM. It is rare and severe form of CM, associated with mast cells infiltration of the entire skin. It is 5% to 13% of all childhood CM forms. DCM presents with erythroderma and generalized pachydermia (thickened skin) (21). Less frequently, DCM manifests with generalized erythema with pseudoxanthomatous or large, tumor-like lesions [3].

Clinical symptoms in CM are result from mast cell-mediators release. The main symptoms are itch, erythema

and edema of the lesions, flushing, blistering and dermographism. Once dermal mast cells are activated, skin lesions become erythematous, edematous and pruritic, sometimes also followed by the emergence of vesicles as well as serous or hemorrhagic blisters, particularly within the first 12–24 months from disease onset [3]. Flushing is caused by increased blood flow through the skin as a result of vasoactive substances release. The presence of flushing is not just a cutaneous sign but also a marker for a systemic vascular response to mast cells mediators and can lead to hypotension and syncope [20]. Thus, flushing in a child with CM should be a warning sign indicating close watchfulness of the patient [3].

Clinical symptoms in CM result from mast-cell mediator release, tissue infiltration of mast cells or both [1].

Mast cell mediators responsible for the clinical manifestations are histamine, cysLT, PGD<sub>2</sub>, PAF, TGF- $\beta$ , IL-5,6, chemokines, heparin, TPA,  $\beta$ -tryptase, SCF, endothelin, tryptase, carboxypeptidase, chymase, and many lysosomal enzymes [1, 21].

According to National Institutes of Health, 83% of children present with pruritus, 65% - flushing, 53% - vesicles, 41% - abdominal pain, 18% - bone pain and headache in 12%. High level of histamine may increase gastric-acid secretion resulting in bleeding and peptic ulcers [12].

There exist multiple triggering factors that can provoke or worsen CM.

Potential Triggers of Mast Cell Degranulation Are [2, 3]:

1. Physical – physical activity, pressure, rubbing, friction, cold, heat;
2. Nutritional – histamine-rich foods, caffeine, hot spices, alcohol, histamine-liberators (alcohol, eggs, chocolate, strawberries, pineapples, exotic fruits, sea food);
3. Infectious – some viral infections;
4. Teething.
5. Emotional stress.
6. Allergens – Hymenoptera allergens and venoms, pollens, dust mite, animal dander, molds, food;
7. Drugs – NSAIDs, opioids, muscle relaxants, cough medications, contrast media, Quinolones;
8. Vaccinations.

### 3.3. Diagnosis

According to the EU/US consensus group, the patient is diagnosed with cutaneous mastocytosis when [15, 22]:

1. No signs or criteria of SM.
2. There are typical skin lesions of mastocytosis.
3. There is positive Darier's sign.
4. One or two of the following minor criteria are presented: increased number of mast cells in biopsy section and activating KIT-mutation in lesional skin.

A major CM criterion is the presence of Darier's sign – reddening and swelling of the lesion after physical irritation [15].

A patient is diagnosed with mastocytosis based on skin lesions morphology, positive Darier's sign and histology assessment of skin lesions for tryptase and/or CD117 [18, 22].

Presence of the KIT D816V-mutation in lesional skin confirms the diagnosis of CM [3].

### 3.4. Treatment

As mentioned above, CM is a condition affecting mainly the skin. Thus, the effective treatment involves avoidance of triggering factors and/ or treatment of mast cell mediators – related symptoms.

For every acute, life-threatening reaction in CM an “Epi-Pen” is highly recommended. Its usage is based on symptoms, course and subtype of CM. Current recommendations suggest to provide it to children suspected for CM presenting with extensive skin lesions, a history of severe systemic symptoms or anaphylaxis and highly elevated tryptase levels [3].

CM is managed mostly by symptomatic treatment. In most children with CM no intensive treatment is required. The main purpose in these patients is to put under control the main symptoms. Major treatment options are subdivided into first-line drugs and alternative drugs.

In patients with itch, flushing and blistering, first-line drugs are antihistamines (H1-antagonists). As an alternative H2-antihistamines, short course of corticosteroids, topical corticosteroids, leucotrien antagonists, Pimecrolimus cream, Topical sodium cromolyn are recommended. In addition, excision of mastocytomas and NB-UVB/ PUVA are described [3].

Gastrointestinal manifestations of mastocytosis (abdominal pain, diarrhea, reflux, ulceration) are managed with H2-antihistamines. As an alternative - proton pump inhibitors, oral sodium cromolyn and oral corticosteroids are used [3].

In case of neuro-psychiatric symptoms (cognitive impairment, headache, loss of concentration) it is recommended to use H1- and H2-antihistamines. In addition, a specific treatment for the individual patients is required [3].

Syncope and hypotonia are managed with H1- and H2-antihistamines. Second line of choice are corticosteroids and epinephrine [3].

Some, rarer clinical findings such as osteopenia and osteoporosis are treated with calcium and Vit. D3 [3].

Anaphylaxis is a life-threatening manifestation of mastocytosis. In acute patients H1- and H2-antihistamines, oral corticosteroids, fluids are used. In order to prevent anaphylaxis – patients are advised to be provided with Epinephrine auto-injector. Prevention of anaphylaxis also include H1-antihistamines, allergen specific immunotherapy and Omalizumab [3].

Local treatment of CM plays a key role in recovery and maintenance of skin integrity and functions. Emollients soothe the skin, rehydrate stratum corneum and reduce the itch and hypersensitivity [23, 24]. Topical corticosteroids prevent mast cell degranulation in cases with extensive cutaneous lesions and recurrent blistering [25, 26]. They should be used for short-term period because of the risk of skin atrophy and adrenal suppression [25]. Local antibiotics are recommended in order to avoid bacterial infections [26]. Solitary mastocytoma is treated with high – potency corticosteroid under occlusion [27]. In case of mastocytoma

accompanying of flushing and hypotension due to mechanical irritation resistant to systemic therapy, a surgical excision should be considered [28].

Z. Husain *et al.* (2017) demonstrate that NB-UVB and PUVA induce relief of the pruritus and reduce the skin that is affected by lesions [29, 30]. Its effectiveness is still debatable of the spontaneous regression of the lesions around puberty and the unclear long-term side effects and safety of UV-therapy. Some authors comment the effectiveness of local calcineurin inhibitors (Pimecrolimus) in severely symptomatic children [3].

## 4. Conclusion

Pediatric mastocytosis is a benign condition with a favourable prognosis. In rare cases, CM may progress to SM. CM has the tendency to regress spontaneously around puberty. Children with CM present with few symptoms and they have fewer triggers of mast cell mediators compared with adult patients. Thus, the treatment is mostly symptomatic. Children with DCM are at risk of more severe symptoms and anaphylaxis and require appropriate treatment. The risk of unforeseeable reactions due to presence of triggering factors is unpredictable, so the most important action to prevent any major complications is to provide the patients with Epi-pen and to inform all medical professional in contact with the child. Although the diagnosis of mastocytosis is not difficult, many patients are wrongly diagnosed because of the variable clinical manifestation of the disease. That is why, in children with itchy polymorphic rash cutaneous mastocytosis should be considered.

## Abbreviations Used

CD34+ - cluster of differentiation 34+  
 CM – cutaneous mastocytosis  
 CysLT – cysteinyl leucotriene  
 DCM – diffuse cutaneous mastocytosis  
 H1-/ H2 – histamine1/2  
 IL-5,6 – interleukin 5,6  
 MPCM – maculopapular cutaneous mastocytosis  
 NB-UVB – narrow-band – Ultraviolet B  
 NSAIDs - Non-steroidal anti-inflammatory drugs  
 PAF – platelet activating factor  
 PGD2 – prostaglandin D2  
 PUVA – psoralen Ultraviolet A  
 SCF – stem cell factor  
 SM – systemic mastocytosis  
 TGF-β – transforming growth factor- β  
 TPA – tissue plasminogen activator

## References

- [1] Silva I, Carvalho S, Pinto P, Machado S, Rosado J. Mastocytosis: a rare case of anaphylaxis in paediatric age and literature review. *Allergologia et Immunopathologia*. 2008. 36; (3): 154-163. DOI: 10.1016/S0301-0546(08)72541-2.

- [2] Barete S. Les mastocytoses. *Annales de dermatologie et de vénéréologie*. 2014; (141): 698-714.
- [3] Lange M, Hartmann K, Carter M, Siebenhaar F, Alvarez-Twose I et al. Molecular Background, Clinical Features and Management of Pediatric Mastocytosis: *Int. J. Mol. Sci.* 2021; 22: 2586. <https://doi.org/10.3390/ijms22052586>.
- [4] Frieri M, Quershi M. Pediatric Mastocytosis: A Review of the Literature. *Pediatr Allergy Immunol Pulmonol*. 2013; 26 (4): 175-180. doi: 10.1089/ped.2013.0275.
- [5] Bologna J, Jorizzo J, Schaffer J. *Dermatology. Neoplasms of the skin. Mastocytosis*. 2012. 3-rd edition. Elsevier. 1994-1998.
- [6] Guleva D, Mateev G. Mastocytosis in childhood. *Practical Pediatrics*. 2017. 1. (in Bulgarian).
- [7] Sagher F, Even-Paz Z. Mastocytosis and the Mast Cell. Basel, Karger, 1967. 4-7. DOI: 10.1159/000390594.
- [8] Yungareva I, Dimitrova J, Ivanova B, Popchristova E, Koleva N, Yordanov T, Kalinova Ts, Tchupetlovska M, Temelkova I, Marina S. Urticaria pigmentosa. A clinical case and review of the literature. *MedInfo*. 2020.8. (In Bulgarian).
- [9] Valent P, Akin C, Metcalfe D. Mastocytosis: 2016 updated WHO classification and novel emerging treatment concepts. *Blood*. 2017; (129): 1420–1427. doi.org/10.1182/blood-2016-09-731893.
- [10] Valent P, Horny H, Escribano L, Longley B, Li C, Schwartz L, et al. Diagnostic criteria and classification of mastocytosis: A consensus proposal. *Leuk. Res.* 2001; 25: 603–625. DOI: 10.1016/s0145-2126(01)00038-8.
- [11] Valent P, Akin C, Gleixner K, Sperr W, Reiter A, et al. Multidisciplinary challenges in mastocytosis and how to address with personalized medicine approaches. *Int. J. Mol. Sci.* 2019; 20: 1–17. DOI: 10.3390/ijms20122976.
- [12] Kettelhut B, Metcalfe D. Mastocytosis. *J Invest Dermatol* 1991; 96: 115–118. doi.org/10.1111/1523-1747.ep12468942.
- [13] Komi DEA, Rambasek T, Wöhr S. Mastocytosis: From a Molecular Point of View. *Clin. Rev. Allergy Immunol*. 2018; 54: 397–411. DOI: 10.1007/s12016-017-8619-2.
- [14] Wasag B, Niedoszytko M, Piskorz A, Lange M, Renke J, Jassem E, et al. Novel, activating KIT-N822I mutation in familial cutaneous mastocytosis. *Exp. Hematol*. 2011. 39, 859–865. doi.org/10.1016/j.exphem.2011.05.009.
- [15] Hartmann K, Escribano L, Grattan C, Brockow K, Carter M, et al. Cutaneous manifestations in patients with mastocytosis: Consensus report of the European Competence Network on Mastocytosis; the American Academy of Allergy, Asthma & Immunology; and the European Academy of Allergology and Clinical Immunology. *J. Allergy Clin. Immunol*. 2016, 137, 35–45. doi: 10.1016/j.jaci.2015.08.034.
- [16] Hartmann K, Valent P, Horny H. Cutaneous mastocytosis. In *World Health Organization (WHO) Classification of Skin Tumours*, 4th ed. Elder D, Massi D, Scolyer R, Willemze R, International Agency for Research on Cancer: Lyon, France. 2018: 275–278.
- [17] Castells M, Metcalfe D, Escribano L. Diagnosis and treatment of cutaneous mastocytosis in children: Practical recommendations. *Am. J. Clin. Dermatol*. 2011, 12, 259–270. doi: 10.2165/11588890-000000000-00000.
- [18] Matito A, Azaña J, Torrelo A, Alvarez-Twose I. Cutaneous Mastocytosis in Adults and Children: New Classification and Prognostic Factors. *Immunol. Allergy Clin. N. Am*. 2018; 38: 351–363. doi: 10.1016/j.iac.2018.04.001.
- [19] Brockow K, Akin C, Huber M, Metcalfe D. Assessment of the extent of cutaneous involvement in children and adults with mastocytosis: Relationship to symptomatology, tryptase levels, and bone marrow pathology. *J. Am. Acad. Dermatol*. 2003; 48: 508–516. doi: 10.1067/mj.2003.98.
- [20] Alvarez-Twose I, Vañó-Galván S, Sánchez-Muñoz L, Morgado J, Matito A, et al. Increased serum baseline tryptase levels and extensive skin involvement are predictors for the severity of mast cell activation episodes in children with mastocytosis. *Allergy*. 2012; 67: 813–818. doi: 10.1111/j.1398-9995.2012.02812.x.
- [21] Valent P, Akin C, Hartmann K, Nilsson G, Reiter A, et al. Mast cells as a unique hematopoietic lineage and cell system: From Paul Ehrlich's visions to precision medicine concepts. *Theranostics*. 2020; 10: 10743–10768. doi: 10.7150/thno.46719.
- [22] Lange M, Ługowska-Umer H, Niedoszytko M, Wasag B, Limon J, et al. Diagnosis of Mastocytosis in Children and Adults in Daily Clinical Practice. *Acta Dermato-Venereol*. 2016, 96, 292–297.
- [23] Broesby-Olsen S, Carter M, Kjaer H, Mortz C, Møller M et al. Pediatric Expression of Mast Cell Activation Disorders. *Immunol. Allergy Clin. N. Am*. 2018; 38: 365–377. doi: 10.1016/j.iac.2018.04.009.
- [24] Brockow K, Ring J, Alvarez-Twose I, Orfao A, Escribano L. Extensive blistering is a predictor for severe complications in children with mastocytosis. *Allergy* 2012; 67: 1323–1324. doi: 10.1111/all.12013.
- [25] Castells M, Butterfield J. Mast cell activation syndrome and mastocytosis: Initial treatment options and long-term management. *J. Allergy Clin. Immunol. Pract*. 2019; 7: 1097–1106. doi: 10.1016/j.jaip.2019.02.002.
- [26] Jenkinson H, Lundgren A, Carter M, Diaz L, Levy M. Management of neonate with diffuse cutaneous mastocytosis: Case report and literature review. *Pediatr. Dermatol*. 2019; 36: 486–489. DOI: 10.1111/pde.13801.
- [27] Matito A, Carter M. Cutaneous and systemic mastocytosis in children: A risk factor for anaphylaxis? *Curr Allergy Asthma Rep*. 2015; 15: 22. doi: 10.1007/s11882-015-0525-1.
- [28] Barnes M, Van L, De Long L, Lawley L. Severity of cutaneous findings predict the presence of systemic symptoms in pediatric maculopapular cutaneous mastocytosis. *Pediatr. Dermatol*. 2014; 31: 271–275. doi: 10.1111/pde.12291.
- [29] Leung AKC, Lam J, Leong K. Childhood Solitary Cutaneous Mastocytoma: Clinical Manifestations, Diagnosis, Evaluation, and Management. *Curr. Pediatr. Rev*. 2019; 15: 42–46. doi: 10.2174/1573396315666181120163952.
- [30] Husain Z, Waterman D, Ellison K, DeSimone J. Management of poorly controlled indolent systemic mastocytosis using narrowband UVB phototherapy. *Cutis* 2017; 99: 30–33. PMID: 28632811.