

Fournier's Gangrene - A Case Report with a Review of the Literature

Hristo Mangarov¹, Valentina Broshtilova², Atanas Batashki³, Svetlana Bezhanova⁴,
Yoanna Velevska⁵, Petar Vatov⁶, Irina Yungareva¹, Sonya Marina¹

¹Department of Dermatology and Venereology, Medical Institute of the Ministry of Internal Affairs, Sofia, Bulgaria

²Department of Dermatology and Venereology, Eurohealth Clinic, Sofia, Bulgaria

³Department of Special Surgery, Medical University, Plovdiv, Bulgaria

⁴Department of Gastroenterology, Medical Institute of the Ministry of Internal Affairs, Sofia, Bulgaria

⁵Department of Infectious Diseases, Parasitology and Dermatovenereology, Medical University, Varna, Bulgaria

⁶Department of Surgical Diseases, Unit of Urology, Medical University, Varna, Bulgaria

Email address:

soniamarina1@yahoo.com (Sonya Marina)

To cite this article:

Hristo Mangarov, Valentina Broshtilova, Atanas Batashki, Svetlana Bezhanova, Yoanna Velevska, Petar Vatov, Irina Yungareva, Sonya Marina. Fournier's Gangrene - A Case Report with a Review of the Literature. *International Journal of Clinical Dermatology*. Vol. 6, No. 2, 2023, pp. 18-23. doi: 10.11648/j.ijcd.20230602.12

Received: August 14, 2023; **Accepted:** September 4, 2023; **Published:** September 13, 2023

Abstract: Fournier's gangrene is a rare form of necrotizing fasciitis, also known as "flesh-eating disease." It cause extensive necrosis of skin, fascia, and subcutaneous of the external genitalia, perineal and perianal areas. The etiology is usually polymicrobial. Initial dermatological symptoms may be missing or mimicking erysipelas, cellulite or abscess. The disease is life-threatening with fulminant onset and prominent intoxication symptoms. Early diagnosis, complex treatment and urgent surgical debridement are crucial in reducing lethal outcome. We describe a case of a 38-year-old man with fever, erythema, edema and severe pain in his testicles and perineum 4 days before hospitalization. He was with poor general condition. The patient had a history of recent Covid-19 infection that worsened his metabolic syndrome and chronic pulmonary obstructive disease. Blood tests showed leukocytosis and extremely elevated C-reactive protein, and microbiological plating - beta streptococci and Staphylococcus aureus. Broad-spectrum antibiotics, aggressive debridement, adequate resuscitation and local treatment of the wound provided fast recovery and favourable outcome. An overview of the epidemiology, risk factors, etiological microorganisms, clinical picture, systemic and local complications, psychological problems, laboratory and imaging diagnostic methods of Fournier's gangrene is presented. Fournier's gangrene and necrotizing fasciitis clinical risk assessment systems are also highlighted. Most appropriate therapeutic modalities are comprehensively discussed.

Keywords: Fournier's Gangrene, Life-Threatening Condition, Fasciotomy

1. Introduction

Fournier's gangrene (FG) was first described by Baurienne in 1764, and named after the French dermatovenerologist Jean-Alfred Fournier [1-3], who in 1883 observed a fulminant gangrene of the genitalia in a young man, verifying infectious etiology [4]. To date, FG is considered a variant of necrotizing soft tissue infections (NSTIs) [5-10]. The disease is usually polymicrobial, causing extensive necrosis of skin, fascia, and subcutaneous of the external genitalia, perineal and perianal areas. Initial dermatological symptoms may be

missing or mimicking erysipelas, cellulite or abscess, which create great diagnostic challenge [11-21]. FG is life-threatening with fulminant onset and prominent intoxication symptoms, including sepsis and/or septic shock [5, 15, 22]. Early diagnosis and complex treatment are of utmost importance. Urgent surgical debridement is crucial in reducing lethal outcome [7, 10, 11, 17, 19-21, 23].

2. Clinical Case

A 38-year-old man was admitted to our department with fever, erythema, edema, and severe pain in his testicles and

perineum with a 4-day duration. The patient's general condition was poor. He had a history of recent Covid-19 infection, which complicated concurrent metabolic syndrome and exacerbated chronic pulmonary obstructive disease. His laboratory findings showed leukocytosis (WBC 31 per mm³) and extremely elevated C-reactive protein (289 mg/l). The microbiological swab proved positive for Gram (+) group beta streptococci and *Staphylococcus aureus*. No anaerobic microorganisms were detected. An intravenous antibiotic therapy with Clindamycin 600 mg 3 times a day in combination with low-molecule direct anticoagulant prophylaxis were introduced, however, his general state continued to deteriorate. The body temperature raised to 39.5°C. The patient became tachycardic (110 / min) and the erythemo-infiltrative plaques spread towards the hypogastric region. Large surgical debridement evacuated extensive purulent exudate on the second hospitalization day (Figure 1).

The wound was treated with oxygenated water. A gauze tamponade with brown salt and a sterile dressing were made. Water-salt rehydration was performed. On the 8th postoperative day, the patient was dehospitalized in good general condition with guidelines for daily cleaning of the wound by a surgeon until its full epithelization.

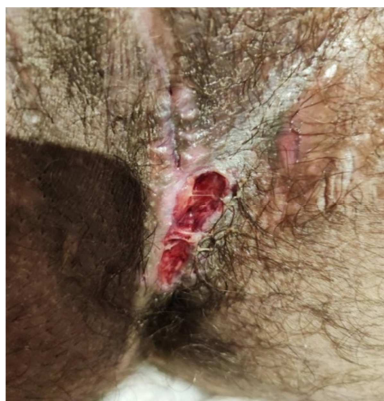


Figure 1. Condition after skin and subcutaneous tissue incision, and fasciotomy of the perineum.

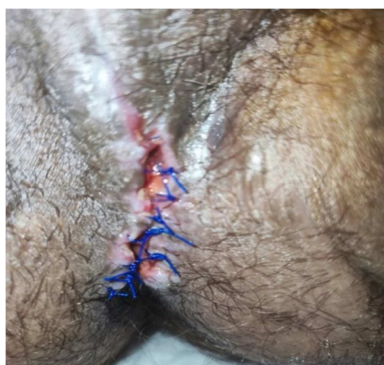

Figure 2. Revision of the wound from the previous operation before 1 month, excision of the lesion along the middle line of the scrotum and adaptation of the skin edges.

After a month, the patient re-appeared at the department with painful edema and redness of the scrotum. He had a blood pressure of 135/95 mmHg, heart rate of 74 /min, and

body temperature of 37.6°C. A deep ulcer was found along the middle line of the scrotum, reaching the sheaths of the testicles, covered with fresh granulations, moderate sero-fibrinous exudation and postoperative cicatrix along the midline of the perineum to the base of the scrotum. The laboratory findings were in normal ranges. Microbiological examination found a microaerophilic hemolytic streptococcus. Surgical excision of the residual lesion along the middle scrotal line and adaptation of the skin edges was performed (Figure 2). Broad spectrum intravenous antibiotic therapy with amino penicillin and ciprofloxacin was done with a good clinical outcome.

3. Discussion

FG is a rare infection that accounts for <0.02% of all hospital admissions. It may be seen at any age and in both sex, however, the sixth and seventh decade men are most commonly affected [18, 20]. Higher numbers of cases are reported in the US and Canada, followed by Africa and Europe. It still unclear whether any environmental trigger factors exists [19]. The southeastern United States has the highest GF morbidity (1.9 cases per 100,000 people) [23]. Women are less likely affected, but clinical manifestations are more severe, have longer hospitalization, and a higher mortality rate than men [24-26]. Single cases of FG in children have also been described [27]. Seasonal fluctuations and endemic regions were not observed.

The most common risk factors are male sex (90% of cases), diabetes mellitus (20% to 70% of cases) and chronic alcohol abuse (25% to 50% of cases) [8, 11, 22, 25]. Advanced age, atherosclerosis, chemotherapy, chronic corticosteroid use, drug abuse (especially injecting directly into the inguinal veins or penis) [28-30], HIV infection [50], immunosuppression, inflammatory bowel disease, perianal, perirectal or ischiorectal abscess, rectal or anal fistula, anal fissure, colon perforation, carcinoma of the colon, prostate or other malignancy, liver failure or cirrhosis [1, 6, 15], neurogenic bladder, iatrogenic damage due to manipulation, recent trauma or surgery (prostate biopsy, catheterization, cystoscopy), injury or stricture of the urethra, infection of the bulbourethral glands or lower urinary tract, epididymitis, orchitis, renal failure [1, 6, 8, 16, 17], peripheral vascular disease, serious heart disease, spinal cord injury, leukemia, obesity or malnutrition, systemic lupus erythematosus, hidradenitis suppurativa, trauma and the presence of foreign bodies, iatrogenic immunosuppression [22, 31-34], administration of sodium-glucose co-transporter 2 inhibitors (glycoric drugs used in diabetic patients) [35] are also described. Patients with multiple comorbidities have a poorer prognosis [36]. In about 25% of cases, the source of the infection is not found [36].

FG results primarily from polymicrobial aerobic and anaerobic synergistic infection of fascia and hypodermis. Most commonly, Gram-positive bacteria, such as group A streptococci and *Staphylococcus aureus* and Gram-negative bacteria, such as *Escherichia coli* and *Pseudomonas*

aeruginosa [37] are isolated.

FG, as a form of necrotizing fasciitis, belongs to type I of NSTI (please, delete classification) according to Giuliano et al. classification, which defines it as a classic polymicrobial mixture of aerobic and anaerobic organisms [33]. Gram-positive cocci (*Staphylococcus aureus*, *Streptococcus pyogenes*, *Enterococcus species*, *Corynebacterium*), Gram-negative sticks (*Escherichia coli*, *Pseudomonas aeruginosa*, *Acinetobacter baumannii*, and anaerobes (*Bacteroides species* and *Clostridium species*) are usually isolated.

Infection begins in the hypodermis. The microorganisms in FG act synergistically by producing tissue-destructive enzymes, collagenases and toxins. Obliterating endarteritis followed with microthrombi in the subcutaneous vessels. Tissue hypoxia and necrosis are intensified. Ischaemic gangrene of the structures involved, "grinding" of fascial barriers and rapid spread of infection to adjacent tissues and along the planes of fascia occurs [34]. The location of the front door and the anatomical location of fascias determine the FG extension [6, 20, 25]. The superficial perineal fascia - the fascia of Colles - continues in the fascia of Buck and Dartos on the penis and scrotum and in the fascia of Scarpa on the anterior abdominal wall. The Colles fascia is attached to the perineum and urogenital diaphragm at the back and to the branches of the pubic bone on the sides, and so limiting progression in these directions [23, 29]. Testicular involvement is rare because testicular arteries originate directly from the aorta and have an autonomic blood supply separate from the affected area [27, 35, 36]. Fournier's advanced or fulminant gangrene can spread from the fascial sheath of the genitals throughout the perineum to the torso or to the hips. The rate of fascial destruction can reach up to 2-3 cm/h [11, 15].

Clinical picture

The earliest signs of FG are genital discomfort, itching, localized sensitivity, diffuse oedema and spotted erythema, without clear demarcation margins and sporadic bullae on the skin of the perineum, perianal or genital areas [2, 8, 12-16, 19]. The pain is extremely severe and spread beyond the erythematous borders of the lesion [6, 17-21, 23, 24]. In patients with diabetic neuropathy, pain may range, from intense to less severe or absent/anesthesia. Pain may also be absent as gangrene advances due to necrosis of nerve tissue. As infection progresses, crepitation, purpura, bullae, greyish-black darkening of the skin, and subsequently patchy discoloration [13, 20] evolve. Subcutaneous gas, crepitation and added putrid fetor point to gas-forming anaerobic microorganisms such as clostridia. The infection can spread along the fascial planes to the anterior abdominal wall [37] and in severe cases to the clavicles [29]. The testicles, structures of the spermatic cord, urethra and cavernous bodies are usually spared due to their autonomic circulation, unless they are the primary source of infection [11]. Systemic symptoms are chills, malaise, nausea, vomiting and urinary retention [8, 15, 16, 22, 23]. Sepsis symptoms include hypotension, tachycardia, fever and rapid progression to multiorgan failure [12, 20, 25, 26]. Mortality is around 40%

and depends on delay of diagnosis and treatment, and the associated diseases. Duly surgical excision and radical debridement is crucial for the favorable outcome [10, 31, 32].

The diagnosis is clinical and assisted by laboratory and imaging diagnostic methods. Leukocytosis, hyponatremia or metabolic acidosis, as well as simultaneous renal failure may be detected. Serum lactate, C-reactive protein and procalcitonin point to bacteremia and sepsis. Arterial blood-gas analysis evaluated oxygenation and acidbase status, while blood and wound microbiological cultures directed antibiotic treatment [7, 18-22, 32, 36]. Ultrasound sonography visualizes subcutaneous gas or emphysema in soft tissues and may be used to differentiate scrotal lesions. The presence of gas in the scrotum is considered to be a pathognomonic sign of Fournier's gangrene [38]. It can also be used to assess the edema, the thickness of the affected soft tissue, the increased subcutaneous fluid and the increased vascular permeability [39]. Other typical ultrasonic findings are "cobblestones" (single subcutaneous fat lobules surrounded by liquid), the "snowball" effect (a rotating appearance of heterogeneous subcutaneous tissue) and "dirty shading" (a hazy appearance of the affected subcutaneous tissue), which help differentiate GF from other, more benign infections [20, 40]. Computed tomography (CT) is the most sensitive and specific form of imaging of FG. It had 88.5% sensitivity and 93.3% specificity [41]. CT allows to determine the degree of infection and plan the volume of surgical debridement. Typical findings are fat accumulation around the affected structures, subcutaneous emphysema, abscess formation, asymmetric fascia thickening and abnormal fluid collections [21, 30, 42-44]. CT is useful for detecting the source of scrotal gas, for the exclusion of various intra- and retroperitoneal processes of the disease, for discovering new pockets of infection after surgery and for assessing wound healing [21].

Magnetic resonance imaging (MRI) is used to determine the infection degree [45]. MRI is excellent for soft tissue imaging, but is not recommended both because of the long implementation time and the cost.

Short-term systemic complications are acute renal failure, acute respiratory distress syndrome, cardiac arrhythmias, heart failure, multiple organ failure and bacteremia. The latter can cause acute thromboembolic events, such as stroke and arterial occlusion in the lower extremities with subsequent amputation. Patients may develop ileus due to the multiple surgeries they undergo. Infections may also occur after debridement [28, 32]. Complication such as fecal incontinence requires a colostomy to reduce fecal contamination [16, 35, 36]. Urinary tract infections, and impaired urination may be detected in penile area and require catheterization and cystostomy [27, 30, 36].

With genital involvement, psychological problems occur, both due to prolonged pain, cicatrix after healing and loss of sensitivity, and due to sexual dysfunction. Subsequent decreased quality of life and depression may develop [11, 27, 38, 40].

Systems for clinical assessment of the risk of necrotizing

fasciitis and of Fournier's gangrene and their prognosis

Tools have been created to determine both the NF risk and its prognosis. The Laboratory Risk Indicator for Necrotizing Fasciitis (LRINEC) was proposed in 2004 by C. Wong *et al.* [44]. It helps to differentiate necrotizing fasciitis from other soft tissue infections and to assess the severity of the infection. Through it, even early cases of necrotizing fasciitis can be distinguished. Abnormalities in six independent variables are evaluated: C-reactive protein, mg/L, total leukocyte count (WBC), cells/mm, hemoglobin, g/dl, sodium, mmol/L, creatinine, mg/dL, glucose, mg/dL. Score ≥ 6 supports the suspicion of necrotizing fasciitis, and score ≥ 8 is confirmatory. A large study of the effectiveness of the LRINEC system in emergency situations found a sensitivity for GF between 68% and 80%, which is unacceptably low given the high mortality associated with both delay in diagnosis and surgical treatment [45]. The limited sensitivity of the LRINEC system renders it inappropriate under conditions of urgency [45]. Some authors found that the Fournier's Gangrene Severity Index (FGSI) is useful for determining the prognosis of the disease [46]. FGSI include nine parameters: body temperature, heart rate, respiratory rate, serum sodium and potassium levels, bicarbonate, creatinine, hematocrit and leukocyte count. The parameters are evaluated on a scale of 0-4 and added up, as a result > 9 is associated with a 75% exit risk, and < 9 with a 78% chance of survival. A worse prognosis is expected already with elevated calcium levels and low magnesium levels [47].

In 2010 the index was expanded with age and tissue participation rates parameters [48]. The prognosis can also be determined by two general surgical scoring systems - SAPGAR - surgical APGAR score and ACCI - age adjusted Charleston Comorbidity Index. ACCI is prognostic and is based on the addition of points of 19 different comorbidities, with each comorbidity rating of 1, 2, 3 or 6. With higher scores, there is an increased risk of exitus. SAPGAR is used to calculate complications in the postoperative period. It is based on a score of 0 to 2 of muscle tone, heart rate, reflexes, skin color and respiratory rate. Scores are collected, and with a lower SAPGAR value, there is a higher risk of complications. SAPGAR and ACCI are not specific to GF, but are roughly equivalent to FGSI and UFGSI [49]. ACCI was found to be of the highest sensitivity and specificity and was among the easiest to use clinically [46].

Newer tools for assessing disease severity in many inflammatory and infectious diseases, including FG, are neutrophils/lymphocyte ratios (NLR), platelets/lymphocytes (PLR) and monocytes/lymphocytes (MLR) [50]. NLR > 8 and PLR > 140 , were associated with 4.66 and 11.6-fold increased exit hazard, respectively. Higher neutrophils/lymphocyte and platelet/lymphocyte ratios are indicative of a poorer prognosis. Retrospective comparison of FGSI versus NLR and PLR in patients with GF found that at higher NLR and PLR values there was a higher probability of exitus, even in patients for whom FGSI showed no statistically significant risk for this [20, 27, 36].

MLR was used to predict the need for repeated surgical

debridement in FG. A retrospective study found that higher MLR was indicative of greater debridement [51].

The success of FG treatment depends on a multidisciplinary team of physicians including a surgeon, urologist, anesthesiologist, pharmacist, infectionist, dermatologist, laboratory team and nursing staff [15, 18, 28, 33, 36]. The basis of successful therapy is early diagnosis, extensive surgery debridement, appropriate antibacterial preparations and hemodynamic resuscitation [7, 10, 11, 17, 19-21, 25, 27-36]. Laboratory and imaging studies should not delay early surgery, as the latter is the most significant factor in survival. Aggressive and early surgical debridement and fasciotomy of necrotic tissue with the insertion of drains is necessary [7, 11, 19, 20, 27, 29-31, 35, 36]. The debridement should be performed within the first 12 hours of hospitalization and repeated every 24 to 48 hours until infection control is achieved. All necrotic tissue should be removed until bleeding on skin margins is detected. After the debridement is completed, the wound is abundantly watered with saline, and hemostasis is carried out by electrocauterization of small vessels or ligation of larger ones. The testicles, even with extensive scrotal damage, are usually not affected, as they have a separate blood supply through the spermatic cord. They can be placed in subcutaneous pockets, usually on the upper inner surface of the hips or on the pubis [21, 24, 27]. The skin of the penis can be affected, but the corpora cavernosa and urethra are usually preserved [48, 49]. If the urethra is affected, a suprapubic tube can be inserted [21, 27, 28, 35, 48]. If the rectum or anus is affected, a colostomy or equivalent fecal system may be done [20, 21, 35].

Treatment is supplemented by antibacterial preparations. It starts with empirical broad-spectrum antibiotics until microbiological study results are obtained. Classically the combination cephalosporin third generation, aminoglycoside, penicillin and metronidazole [32, 36] is applied. Current recommended antibiotic regimens for GF are [19-21, 35]: carbapenems (imipenem or meropenem 1 g IV at 6-8 hours, ertapenem 1 g IV at 24 hours or piperacillin-tazobactam (3.375 g IV at 6 hours or 4.5 g IV at 8 hours) in combination with clindamycin (600 to 900 mg IV every 8 hours) and vancomycin (15 to 20 mg/kg IV at 8 to 12 hours). The latter can be replaced with daptomycin or linezolid [20]. If necessary, antimycotic drugs (fluconazole, amphotericin B or others) [19] are added. An alternative regimen is aminoglycoside or fluoroquinolone with metronidazole [19]. In patients exposed to fresh or salt water contaminated with *Aeromonas hydrophilia* and *Vibrio vulnificus*, doxycycline is recommended [19]. Antibiotic treatment should continue until the patient is stabilized and restored. Resuscitation care requires correction of electrolytes, blood sugar, hypotension, dehydration and other deviations [10, 19-21, 26, 30, 35]. Antibiotic and resuscitation measures must be at the same time as a prioritised, radical and broad debridement.

Treatment is complemented by hyperbaric oxygen therapy, immunotherapy, local therapy and therapeutic plasma exchange. Hyperbaric oxygen therapy (HBOT) is

administered only postoperatively [11]. It is used after the initial surgical debridement, improving survival and reducing mortality. It is an adjuvant therapy due to its bactericidal and bacteriostatic effects. HBOT improves tissue oxygenation with consequent increase in antibiotic delivery, slowing bacterial proliferation and stimulating wound healing. It should be repeated every 24 to 48 hours until infection control is achieved.

Intravenous immunoglobulins (IVIG) have been proposed to help neutralize streptococcal toxins and limit the systemic inflammatory response, but sufficient data on their benefit are lacking [50].

There is also insufficient evidence for therapeutic plasma metabolism aimed at removing toxins and inflammatory mediators [51].

After surgical removal, vacuum-assisted wound closure (VAC) can be applied for faster healing [45]. VAC or negative pressure wound therapy reduces the air pressure around the wound, enhances blood supply and migration of inflammatory cells to the affected area. This leads to the formation of granulation tissue and to the clearing of bacterial contamination, toxins, exudates and cell debris.

Topical honey application improves wound healing, but so far there are no studies to validate this type of therapy [14, 30].

For major anogenital and perineal defects, reconstructive surgery and extensive skin grafting are often required, improving quality of life [1, 21, 30, 33].

4. Conclusion

FG is a life-threatening infection with mortality rate up to 88%. The disease should be always considered when intense pain spread beyond the visual margins of the skin lesions affecting the anogenital and perineal areas. Associated metabolic syndrome and concomitant infections facilitate FG intensity and probability. Prompt hospitalization with broad surgical debridement is of outmost importance for the favourable clinical outcome. The disease is an enormous challenge to the multidisciplinary team that should provide proper patient's care and support. Upon short-term favorable outcome, reconstructive plastic surgery is needed to ensure better quality of life.

References

- [1] Carroll PR, Cattolica EV, Turzan CW, et al. Necrotizing soft-tissue infections of the perineum and genitalia. Etiology and early reconstruction. *West J Med.* 1986; 144 (2): 174-178.
- [2] Stephens BJ, Lathrop JC, Rice WT, et al. Fournier's gangrene: historic (1764-1978) versus contemporary (1979-1988) differences in etiology and clinical importance. *Am Surg.* 1993; 59: 149-154.
- [3] Short B. Fournier's gangrene: an historical reappraisal. *Intern Med J.* 2018; 48 (9): 1157-1160.
- [4] Fournier JA. Gangrène foudroyante de la verge. *La semaine médicale (Paris).* 1883; 3: 345.
- [5] Wong CH, Chang HC, Pasupathy S, et al. Necrotizing fasciitis: clinical presentation, microbiology, and determinants of mortality. *J Bone Joint Surg Am.* 2003; 85 (8): 1454-1460.
- [6] Mishra SP, Singh S, Gupta SK. Necrotizing Soft Tissue Infections: Surgeon Prospective. *Int J Inflam.* 2013; 2013: 609-628.
- [7] Wróblewska M, Kuzaka B, Borkowski T, et al P. Fournier's gangrene - current concepts. *Pol J Microbiol.* 2014; 63 (3): 267-273.
- [8] Taken K, Oncu MR, Ergun M, et al. Fournier's gangrene: Causes, presentation and survival of sixty-five patients. *Pak J Med Sci.* 2016; 32 (3): 746-750.
- [9] Wallace H, Perera T. Necrotizing Fasciitis. [Updated 2020 Jul 2]. In: StatPearls [Internet]. Treasure Island (FL): StatPearls Publishing; 2020 Jan. Available from: <https://www.ncbi.nlm.nih.gov/books/NBK430756/>.
- [10] Peetermans M, de Prost N, Eckmann C, et al. Necrotizing skin and soft-tissue infections in the intensive care unit. *Clin Microbiol Infect.* 2020; 26 (1): 8-17.
- [11] Thwaini A, Khan A, Malik A, et al. Fournier's gangrene and its emergency management. *Postgrad Med J.* 2006; 82 (970): 516-519.
- [12] Singam P, Wei KT, Ruffey A, et al. Fournier's Gangrene: A Case of Neglected Symptoms with Devastating Physical Loss. *Malays J Med Sci.* 2012; 19 (3): 81-84.
- [13] Goh T, Goh LG, Ang CH, et al. Early diagnosis of necrotizing fasciitis. *Br J Surg.* 2014; 101 (1): 119-125.
- [14] Singh A, Ahmed K, Aydin A, et al. Fournier's gangrene. A clinical review. *Arch Ital Urol Androl.* 2016; 88 (3): 157-164.
- [15] Voelzke BB, Hagedorn JC. Presentation and Diagnosis of Fournier's Gangrene. *Urology.* 2018; 114: 8-13.
- [16] Kuzaka B, Wróblewska MM, Borkowski T, et al. Fournier's Gangrene: Clinical Presentation of 13 Cases. *Med Sci Monit.* 2018; 24: 548-555.
- [17] Chernyadyev SA, Ufimtseva MA, Vishnevskaya IF, et al. Fournier's Gangrene: Literature Review and Clinical Cases. *Urol Int.* 2018; 101 (1): 91-97.
- [18] Gadler T, Huey S, Hunt K. Recognizing Fournier's Gangrene in the Emergency Department. *Adv Emerg Nurs J.* 2019; 41 (1): 33-38.
- [19] Montrieff T, Long B, Koyfman A, et al. Fournier's Gangrene: A Review for Emergency Clinicians. *J Emerg Med.* 2019; 57 (4): 488-500.
- [20] Auerbach J, Bornstein K, Ramzy M, et al. Fournier's Gangrene in the Emergency Department: Diagnostic Dilemmas, Treatments and Current Perspectives. *Open Access Emerg Med.* 2020; 12: 353-364.
- [21] Lewis GD, Majeed M, Olang CA, et al. Fournier's Gangrene Diagnosis and Treatment: A Systematic Review. *Cureus.* 2021; 13: 10-16.
- [22] Eke N. Fournier's gangrene: a review of 1726 cases. *Br J Surg.* 2000; 87: 718-728.23. Tahmaz L, Erdemir F, Kibar Y, et al. Fournier's gangrene: report of thirty-three cases and a review of the literature. *Int J Urol.* 2006; 13: 960-967.

- [23] Ozkan OF, Koksall N, Altinli E, et al. Fournier's gangrene current approaches. *Int Wound J*. 2016; 13: 713–716.
- [24] Herrero A. *Therapeutic Manual Emergency Medicine and Procedures*. 2016; 7th ed. McGraw-Hill. III.
- [25] Partin A, Dmochowski R, Kavoussi L, et al. *Campbell-Walsh-Wein Urology*. 2020; 12th ed. Elsevier. II. Gulias.
- [26] Vernon MP. Fournier's Gangrene, <https://emedicine.medscape.com>, Updated: Jun 03, 2021.
- [27] Sorensen MD, Krieger JN. Fournier's Gangrene: Epidemiology and Outcomes in the General US Population. *Urol Int*. 2016; 97 (3): 249-259.
- [28] Czymek R, Hildebrand P, Kleemann M, et al. New insights into the epidemiology and etiology of Fournier's gangrene: a review of 33 patients. *Infection*. 2009; 37: 306-312.
- [29] McCormack M, Valiquette A, Ismail S. Fournier's Gangrene: A Retrospective Analysis of 26 Cases in a Canadian Hospital and Literature Review. *Can Urol Assoc J*. 2015; 9: E407-410.
- [30] Sorensen MD, Krieger JN, Rivara FP, et al. Fournier's Gangrene: population based epidemiology and outcomes. *J Urol*. 2009; 181 (5): 2120-2126.
- [31] Lynch CM, Pinelli DM, Cruse CW, et al. Maternal death from postpartum necrotizing fasciitis arising in an episiotomy: a case report. *Infect Dis Obstet Gynecol*. 1997; 5: 341-344.
- [32] Czymek R, Frank P, Limmer S, et al. Fournier's gangrene: is the female gender a risk factor? *Langenbecks Arch Surg*. 2010; 395: 173-180.
- [33] Medhi R, Rai S, Das A, et al. Necrotizing fasciitis - a rare complication following common obstetric operative procedures: report of two cases. *Int J Womens Health*. 2015; 7: 357-360.
- [34] Ballard DH, Mazaheri P, Raptis CA, et al. Fournier's Gangrene in Men and Women: Appearance on CT, Ultrasound, and MRI and What the Surgeon Wants to Know. *Can Assoc Radiol J*. 2020; 71 (1): 30-39.
- [35] Rouzrokh M, Tavassoli A, Mirshemirani A. Fournier's gangrene in Children: Report on 7 cases and Review of Literature. *Iran J Pediatr*. 2014; 24 (5): 660-661.
- [36] Hagedorn J, Wessells H. A contemporary update on Fournier's gangrene. *Nature Reviews Urology*. 2016; 14 (4): 205-214.
- [37] Sparenborg JD, Brems JA, Wood AM, et al. Fournier's gangrene: a modern analysis of predictors of outcomes. *Transl Androl Urol*. 2019; 8 (4): 374-378.
- [38] Bloomgarden Z, Einhorn D, Grunberger G, et al. Fournier's gangrene and sodium-glucose cotransporter 2 inhibitors: Is there a causal association? *J Diabetes*. 2019; 11 (5): 340-341.
- [39] Serrano Olave A, Bueno Moral AI, Martínez Bañón C, et al. Fournier's Gangrene under Sodium-Glucose Cotransporter-2 Inhibitors Therapy in Gynecological Patients. *Int J Environ Res PublicHealth*. 2022; 19 (10): 76-82.
- [40] El-Qushayri A, Khalaf K, Dahy A, et al. Fournier's gangrene mortality: A 17-year systematic review and meta-analysis. *Int J Inf Dis*. 2020; 92: 218-225.
- [41] Yılmazlar T, Işık Ö, Öztürk E, et al. Fournier's gangrene: a review of 120 patients and mortality predictors. *Ulus Travma Acil Cerrahi Derg*. 2014; 20: 333-337.
- [42] Brennan M, LeFevre F. Necrotizing fasciitis: Infection identification and management. *Nurs Crit Care*. 2019; 14 (1): 6-11.
- [43] Eğin S, Kamalı S, Gökçek B, et al. Four Determinative Factors in Fournier's Gangrene Mortality. *Turk J Colorectal Dis*. 2019; 29 (1): 12-18.
- [44] Radcliffe RS, Khan MA. Mortality associated with Fournier's gangrene remains unchanged over 25 years. *BJU Int*. 2020; 125 (4): 610–616.
- [45] Elmi AM, Kusbeci M, Osoble, et al. A case report of Fournier's gangrene: Imaging ultrasound and computed tomography (CT) scan. *Radiol Case Rep*. 2022; 17 (3): 959-962.
- [46] Fernando SM, Tran A, Cheng W, et al. Necrotizing Soft Tissue Infection: Diagnostic Accuracy of Physical Examination, Imaging, and LRINEC Score: A Systematic Review and Meta-Analysis. *Ann Surg*. 2019; 269 (1): 58-65.
- [47] Creta M, Longo N, Arcaniolo D, et al. Hyperbaric oxygen therapy reduces mortality in patients with Fournier's Gangrene. Results from a multi-institutional observational study. *Minerva Urol Nefrol*. 2020; 72 (2): 223-228.
- [48] Feres O, Feitosa MR, Ribeiro da Rocha JJ, et al. Hyperbaric oxygen therapy decreases mortality due to Fournier's gangrene: a retrospective comparative study. *Med Gas Res*. 2021; 11 (1): 18-23.
- [49] Schneidewind L, Anheuser P, Schönborg S, et al. Hyperbaric Oxygenation in the Treatment of Fournier's Gangrene: A Systematic Review. *Urol Int*. 2021; 105 (3-4): 247-256.
- [50] Hedetoft M, Bennett MH, Hyldegaard O. Adjunctive hyperbaric oxygen treatment for necrotising soft-tissue infections: A systematic review and meta-analysis. *Diving Hyperb Med*. 2021; 51 (1): 34-43.
- [51] Raizandha MA, Hidayatullah F, Klopung YP, et al. The role of hyperbaric oxygen therapy in Fournier's Gangrene: A systematic review and meta-analysis of observational studies. *Int Braz J Urol*. 2022; 48 (5): 771-781.