



# Surgical Treatment of Skin Cancers of the Head and Neck at the DONKA Surgical Oncology Unit

**Bah Malick<sup>\*</sup>, Keita Mamady, Toure Alhassane Ismael, Cisse Kalil, Souare Mamadou Bobo, Conde Ibrahima Kalil, Traore Bangaly**

Surgical Oncology Unit at Donka National Hospital, Conakry University Hospital, Conakry, Guinea

## Email address:

lickmadem@yahoo.fr (Bah Malick), mamadykeita@rocketmail.com (Keita Mamady), tourealhassane@yahoo.fr (Toure Alhassane Ismael), mbobosouare@gmail.com (Souare Mamadou Bobo), condekalil1800@gmail.com (Conde Ibrahima Kalil), ucodonka@gmail.com (Traore Bangaly)

<sup>\*</sup>Corresponding author

## To cite this article:

Bah Malick, Keita Mamady, Toure Alhassane Ismael, Cisse Kalil, Souare Mamadou Bobo, Conde Ibrahima Kalil, Traore Bangaly. Surgical Treatment of Skin Cancers of the Head and Neck at the DONKA Surgical Oncology Unit. *International Journal of Clinical Dermatology*. Vol. 6, No. 2, 2023, pp. 24-28. doi: 10.11648/j.ijcd.20230602.13

**Received:** September 5, 2023; **Accepted:** October 12, 2023; **Published:** October 28, 2023

**Abstract:** *Objective:* To improve the surgical treatment of head and neck skin cancers. *Materials and methods:* This was a retrospective descriptive cohort study examining the sociodemographic, anatomopathological, therapeutic and evolutionary aspects of patients with head and neck skin cancer. *Results:* 148 patients (65.2%) were histologically confirmed and 43 (29.1%) underwent surgery. The mean age was  $33 \pm 16$  years. The average time to treatment was 6 months. There were 10 (22.0%) stage III cases. The most typical histological type was squamous cell carcinoma (97.7%), of which 18 cases (41.9%) had a tumor size  $> 4$  cm. Wide resection was performed in 88.4% of cases and surgical wound closure was achieved by flap grafting in 55.8% of cases. Healing was normal in 53.5% of cases. After a mean follow-up of  $16 \pm 22$  months, overall survival at 12 months was 44%. 13 patients (30.2%) are still alive. *Conclusions:* This study shows that only a small number of head and neck skin cancer patients are operated on in the oncology department of Conakry University Hospital. Ongoing training of healthcare professionals and dermatological surveillance for primary and secondary prevention of skin cancer in people with albinism may help to improve outcomes for people with skin cancer and improve the quality of care for head and neck skin cancer.

**Keywords:** Surgery, Cancer, Skin, Head, Neck

## 1. Introduction

Cutaneous cancers are malignant tumours that develop at the expense of one of the constituents of the skin, which may be of epidermal, melanic or adnexal origin [1].

Depending on the tissue affected, these may be carcinomas, melanomas or cancers of various origins (sarcomas, lymphomas). [2]. These cancers differ in their clinical, evolutionary and histological expression. 90% of cutaneous squamous cell carcinoma (SCC) lesions are located in the head and neck region [3].

Regardless of the type of skin cancer, age-standardized incidence is increasing worldwide [4]. Head and neck cancer ranks 6<sup>ième</sup> among all cancers, with more than 500,000 new cases and 300,000 deaths per year worldwide. [5].

Cutaneous melanoma of the head and neck accounts for 20% of all cutaneous melanomas [6].

In the United States, head and neck cancer affects more than 40,000 people every year. It is responsible for more than 20,000 deaths per year. [7]. In Western countries, the incidence of SCC has increased by 6-8% per year since 1960 [8].

In Togo, cutaneous carcinomas were the most frequent skin cancers recorded from 1973-1992 [9].

In Guinea, skin cancers of the head and neck accounted for 46% of skin cancers recorded at the Oncological Surgery Unit of the Donka National Hospital in 2017 [4]. The high prevalence of SCC and melanoma in blacks, as opposed to Basal Cell Carcinoma (BCC) in whites, has been reported in several studies [4]. Exposure to the sun is the major risk in white-skinned people, whereas non-sun

factors appear to be the main risk in black-skinned people. [10].

In Africa, these skin cancers appear on chronic wounds or burn scars, which explains why they are discovered late in life in areas not exposed to the sun. Albinism, sun exposure and immunosuppression are risk factors for certain skin cancers. [2, 10].

Treatment for head and neck cancer is multidisciplinary, combining surgery, radiotherapy and chemotherapy.

Despite the effectiveness of these management methods, 30 to 60% of local recurrences or second cancers are observed in the previously irradiated area. [11].

In our context, surgery is the most accessible means of treatment. Surgical removal is the standard treatment for non-metastatic skin cancer. The surgical modalities depend on the stage of progression [6].

Thus, under-notification of cases and, above all, the need to improve surgical management of patients and their post-surgical prognosis are the main reasons for conducting this study, the aim of which was to analyse the carcinological and aesthetic results of surgical treatment of skin cancers of the head and neck in the oncology department of the Donka National Hospital in Conakry.

## 2. Materials and Methods

This was a retrospective descriptive cohort study covering fourteen (14) years, from 1st May 2007 to 1st May 2021, in the oncology department of the Donka National Hospital in Conakry.

Our study included patients with histologically confirmed head and neck skin cancer who had undergone surgery.

The variables studied were epidemiological, clinical, therapeutic and evolutionary. Risk factors, co-morbidities and personal or family history were also reported.

Data were analyzed using SPSS software (version 21.0). Survival was analyzed using the Kaplan-Meier method.

## 3. Results

We collected 486 cases of skin tumours, 227 (46.7%) of which were located on the head and neck. Of these cases, 148 (65.2%) were histologically confirmed and 43 (29.1%) had been treated by surgery.

In our study, the mean age of patients was 33 years ( $\pm 16$  years) with extremes from 8 to 75 years. The 20-39 age group was represented in 22 (51.2%) cases. Males predominated in 26 (60.5%) cases, with a sex ratio of 1.52.

The majority lived in the interior of the country, with 27 (62.8%) cases and 37.2% living in Conakry. Twenty-three (53.48%) of the cases were married, 24 (55.8%) were at school and 14 (32.5%) were pupils/students. Albinism was the risk factor encountered (Table 1) in 24 (55.8%) cases.

Hypertension was present in 4 (9.3%) cases. Smoking was observed in 5 (11.6%) cases and a combination of smoking and alcoholism in 5 (11.6%) cases.

**Table 1.** Distribution of cases according to risk factors, cancer history and co-morbidity.

Features	Workforce	(%)
Risk factors		
Albinism	24	55,8
Radius U V	16	37,2
Burn scar	3	7,0
Comorbidity		
HTA	4	9,3
Diabetes	2	4,7
Hepatitis B	1	2,3
No	36	83,7
History of cancer		
No	42	97,7
Yes	1	2,3
Lifestyle		
Tobacco	5	11,6
Alcohol +Tobacco	5	11,6
No	33	76,7

Swelling was the main reason for consultation (90.7%), followed by ulceration (7.0%). Consultation was delayed by more than six (06) months in 37 (86.0%) cases. The WHO index was  $\leq 2$  in 42 (97.7%) cases.

In our study, the preferred site of the tumor was the head (86.0%) followed by the head and neck combination (9.3%) (Table 2). The tumor was located proportionally on the scalp and cheek in 13 (30.2%) cases, followed by the eyelids in 6 (14.0%) cases.

**Table 2.** Distribution of cases according to the tumor site.

Features	Workforce	%
Headquarters		
Scalp	13	30,2
Cheek	13	30,2
Eyelid	6	14,0
Front	3	7,1
Ear	2	4,6
Neck	2	4,6
Head and neck	4	9,3

The appearance of the tumor was ulcerating-boarding in 29 (67.4%) cases (Figure 1), followed by budding in 7 (16.3%) cases. The tumor was fixed in both planes in 26 (60.5%) cases and mobile in 17 (39.5%) cases. The consistency of the tumor was firm in 23 (53.5%) cases and hard in 15 (34.9%). It was painless in 37 (86.0%) cases and painful in 5 (11.6%).

The tumor was single in 36 (83.7%) cases and multiple in 7 (16.3%). It was non-invasive in 27 (62.8%) cases and invasive in 16 (37.2%). Tumor size was greater than 4 cm in 18 (41.9%) cases and between 2 and 4 cm in 15 (34.9%) cases. Examination of the lymph nodes revealed cervical adenopathy (16.3%), followed by submandibular adenopathy (9.3%) and maxillary adenopathy (7%).

The histological type was squamous cell carcinoma in 23 (53.5%) cases, followed by basal cell carcinoma in 5 (11.6%) cases. (Table 3)

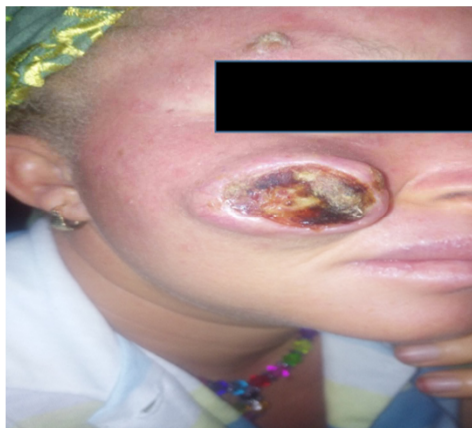According to the UICC TNM classification, 8<sup>eme</sup> 2017 Edition, patients consulted with stage III in 10 (22.0%) cases and stage II in 9 (20.0%) cases. There was one liver metastasis (4.6%).

**Table 3.** Distribution of cases according to histological type, TNM stage and site of metastasis.

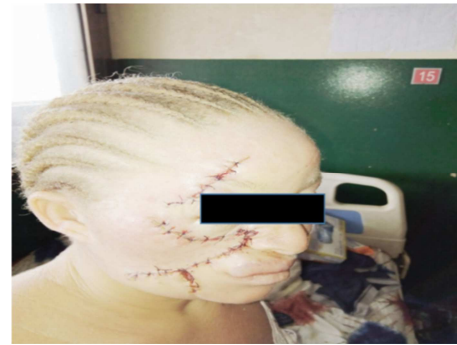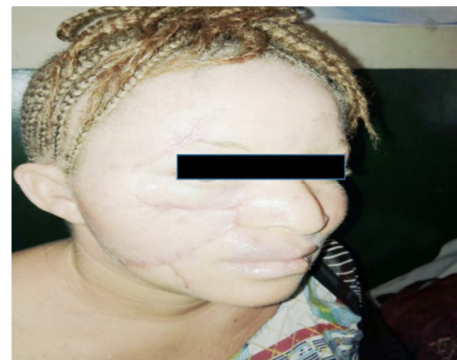Features	Workforce	(%)
Histological type		
Squamous cell carcinoma	23	53,5
Basal cell carcinoma	5	11,6
Melanoma	3	7,0
Merkel cell carcinoma	1	2,3
Sai carcinoma	11	25,6
TNM stage		
Stage 1	2	4,0
Stage 2	9	20,0
Stage 3	10	22,0
Stage 4	2	4,0
Not precise	20	46,0
Site of metastases		
Liver	2	4,6
No	28	65,1
Not rated	13	30,2

Patients received neoadjuvant chemotherapy in 6 (14.0%) cases and adjuvant chemotherapy in 3 (7.0%) cases, with an objective response in 3 cases. The protocol consisted of platinum salts and 5Fu (CDDP-5Fu) in 9 (20.9%) cases. The number of courses ranged from 2 to 6, with an average of 6.4 courses.

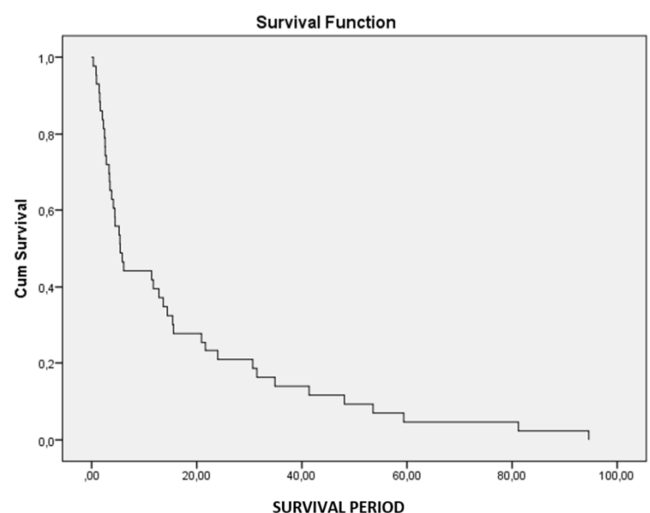
The time to surgery was 6 months in 15 (45.5%) cases; 41 (95.3%) cases had a curative indication for surgery. General anaesthesia was used in all patients. Wide excision was performed in 38 (88.4%) cases. The incision was circular in 17 (39.5%) cases and linear in 9 (20.9%) (Figure 2). We did not perform lymph node dissection. Surgical wounds were closed by skin flap grafting in 24 (55.8%) cases and by direct suture in 19 (44.2%) cases. 4 (9.3%) cases presented an early complication such as haemorrhage and 1 (2.3%) patient had suppurated. Healing was normal in 23 (53.5%) cases.

**Figure 1.** A 34-year-old patient presented with an ulcerative-bourgeolar aspect of squamous cell carcinoma of the cheek.

Follow-up was greater than 6 months in 15 (45.5%) patients. In terms of evolution, remission was complete in 20 (46.5%) patients (Figure 3). Recurrence occurred in 4 (9.3%) patients. Recurrence was local in 3 (75.0%) patients and locoregional in 1 (25.0%). 13 (30.2%) patients are still alive, 10 (23.3%) patients have died and 20 (46.5%) patients have been lost to follow-up.

**Figure 2.** Direct suture after wide resection of squamous cell carcinoma of the cheek in a 34-year-old patient on day 1 post-op.**Figure 3.** Scar from wide resection of squamous cell carcinoma of the cheek in a 34-year-old patient.

The mean follow-up time was 16 months ( $\pm 22$  months), and we observed 4 (9.3%) cases of recurrence. These recurrences were local in 3 (75%) cases and locoregional in 1 (25%). Overall survival at 12 months was 44% and at 24 months 20%. (Figure 4)

**Figure 4.** Overall survival of patients with head and neck skin cancer.

## 4. Discussion

Over 14 years, skin tumours localised to the head and neck accounted for 46.7% of all malignant skin tumours. This proportion is similar to that reported by Traoré B and al [4] in a study published in the Journal of Cancer Therapy, i.e. 46%

of cutaneous tumours of the head and neck. On the other hand, it is similar to that reported by Malalaniain A. and al [1] in Madagascar and significantly higher than that of Saka et al [12] in Togo, who respectively found a proportion of 44% and 25% of skin tumours located in the head and neck. The high frequency in our study could be explained by the fact that the head and neck are the parts of the body most exposed to UV rays, the main risk factor for skin cancers.

The average age was 33. This result is lower than those of Menye and al [13] and Hadan D and al [14] who reported mean ages of 43.7 and 71 respectively. The relatively young age of the patients with skin cancers located on the head and neck in our study could be explained by the fact that this is the most active layer with the longest exposure time to risk factors such as UV rays; 51.2% (22 cases) of them were aged between 20 and 39 years.

Males predominated in our study, with a sex ratio of 1.52. The predominance of this gender was also found by Fayek and al [15] in Egypt, with an M/F sex ratio of 1.4. However, our results differ from those of Grossi Marconi and al [16] in the United States and Ouédraogo and al [17] in Burkina Faso, who found a female predominance, with an M/F sex ratio of 1.05 and 1.2 respectively. To our knowledge, there is as yet no proven direct correlation between gender and the occurrence of skin cancers. However, the development of outdoor activities and exposure to the sun in recent years remains an important factor in the increase in the incidence of skin cancers. Alongside this factor, albinism appears to be the primary cause of skin cancer risk factors. [18] In our series, albinism was noted in 55.8% of cases.

According to location, the scalp and cheek were the areas most affected with a proportional frequency of 30.2%. In a 2011 study of head and neck SCC in Alabama, USA, Dean and al. [19] found that the ear and auricular region was the most common site, accounting for 65.2% of cases. However, Grossi Marconi and al [16] found that skin cancers of the head and neck preferentially involved the nose and face in 33% and 31% respectively.

In our study, the clinical presentation of the tumor was dominated by ulcerating-bourgeoning forms. Ouédraogo and al. [17] in Burkina Faso also made this observation. Our results corroborate the data in the literature [18].

According to the number of tumor sites, the tumor was unique in most cases (83.7%). This result is similar to that of Fayek and al who found that the tumor was unique (94%). [15]. Cutaneous cancers of the head and neck are rarely multifocal.

In our series, the mean tumor size was 5 cm. Hadan D and al [14] in their study reported an average of  $2.11 \pm 1.71$  cm. This difference in size observed in our study raises the issue of the inadequacy of skin cancer screening campaigns on the one hand, and on the other hand, the ongoing promotion of early diagnosis of cancers.

The most frequently diagnosed histological type was squamous cell carcinoma in 53.5% of cases. Menye and al reported that squamous cell carcinoma was also the predominant histological type with a proportion of 65.7%. [13]. This frequency of squamous cell carcinomas is thought

to be the result of prolonged and cumulative exposure to ultraviolet light [20].

The majority of patients consulted at stage III, compared with Fayek and al. [15] who reported a predominance of stage II. This predominance in our study can be explained by the fact that the majority of our patients consulted at an advanced stage of the disease.

In terms of treatment, although surgery is the standard treatment for localized head and neck skin cancer, only 29.1% of patients with head and neck skin cancer received surgical treatment, whereas in the study by Kelder and al. [21]. All patients underwent surgery. This could be explained by the high cost of treatment and the advanced stage of the disease at the time of the initial consultation.

Of these patients, 95.3% had a curative indication for surgery.

Most of our patients underwent wide resection. Wide resection aims to reduce the risk of relapse. The surgical treatment of choice was also wide resection as reported by Traoré and Lamah [4]. This is in line with the recommendations for the surgical management of skin cancers [18].

Closure of surgical wounds was obtained by skin flap grafting in 55.8% of cases. This procedure was previously reported by Traoré and Lamah [4].

As radiotherapy is the adjuvant treatment for skin cancer, especially at an advanced stage, it was clear that none of the patients in our study received radiotherapy.

During follow-up, we observed 9.3% of cases of recurrence, which is similar to the results of Vasconcelos et al who reported 8.9% of relapses [22]. This highlights the need for strict monitoring of patients who have been treated for skin cancer.

Overall survival at 12 months was 44% in our study, which is different from that of Dean and al [19] who reported an overall survival at 24 months of 62.2%. Our result could be explained by the fact that the majority of our patients consulted at an advanced stage and many of them did not benefit from adjuvant treatment.

## 5. Conclusion

Surgery for skin cancer of the head and neck is the mainstay of treatment for this disease. However, the procedure is only performed on a small number of patients requiring surgery at the surgical oncology department of Conakry University Hospital. Because of the wide excision, this surgery is mainly used for therapeutic purposes, which is the most commonly performed type of surgery. Surgical closure of the wound is achieved by skin flap transplantation. Complete responses were observed in most cases, unfortunately, postoperative mortality was not negligible and overall survival was poor.

Inclusion in the workforce, sun awareness, the use of protective measures (wearing a hat, sun cream and sunglasses), dermatological surveillance and primary and secondary prevention of skin cancers all help to improve results.

## References

- [1] Malalaniaina A, Lovasoa T, Mamisoa RI, Malala R, Soavina RL, Florine R, et al. Skin cancers in Madagascar: Where do we stand? *Pan Afr Med J*. 2019; 34: 1-8.
- [2] Traore B, Keita M, Condé M, Keita M, Diane S, Cissé M, et al. Anatomico-clinical characteristics of skin cancers in the surgical oncology unit of Conakry University Hospital. *Rev CAMES SANTE*. 2016; 4 (2): 78-82.
- [3] Szewczyk M, Pazdrouvski J, Golusinski P, Danczak-Pazdrowska A, Marszalek S and Golusinski W. Analysis of selected risk factors for nodal metastases in head and neck cutaneous squamous cell carcinoma. *Eur Arch Otorhinolaryngol*. 2015; 272; 3009-3012.
- [4] Traore B, Lamah L. Outcomes of Surgical Treatment of Skin Cancer at Surgical Oncology Unit of Donka, Conakry University Hospital. *JCT*. 2017; 08 (12): 1086-94.
- [5] Winquist E, Agbassi C, Meyers M B, Yoo J, Chan K W. Abstract Systemic therapy in the curative treatment of head and neck squamous cell cancer: systematic review. *Otolaryngology-Head and Neck Surgery*. 2017; 46: 19-29.
- [6] Kadakia S, Chan D, Mourad M, Ducic Y. The Prognostic Value of Age, Sex and Subsite in Cutaneous Head and Neck Melanoma; A Clinical Review of recent Literature. *Cancer prevention*. 2016; 9 (3): 5079-5082.
- [7] Sun Q, Prasad R, Rosenthal E, and Kaliyar SK. Grape seed proanthocyanidins inhibit the invasive potential of head and neck cutaneous squamous cell carcinoma cells by targeting EGFR expression and epithelial-to-mesenchymal transition. *Complementary and Alternative*. 2011; 11: 123-134.
- [8] Jean-Hilaire S, Jean-Marie L, Dan L, Luc T, Luca B. Dermatology and sexually transmitted infection. 6th edition, Paris: Elsevier Masson; 2017, 1288.
- [9] Saka B, Souley Z, Kombaté K, Mouhari M, Toure A, Akakpo S Et al. Les Cancers cutanés au Togo: 223 observations; *Med Trop*. 2016; 70: 169-171.
- [10] Asuquo M, Ebughe G. Frequently encountered skin cancers at Calabar Teaching Hospital, Calabar, Southern Nigeria. *Int J Dermatol*. 2012; 51: 36-40.
- [11] Mouttet-Audouard R, Gras L, Connet B and Lartigau E. Radiotherapy of head and neck tumours in irradiated areas. *Bulletin du Cancer*. 2011; 98 (12): 1477-1488.
- [12] Chiheb S, El Moutaoui L, Moustaghfir I, Benchikhi H. Cutaneous cancers: epidemiology, clinical and histological aspects. Service de Dermatologie, CHU Ibn Rochd de Casablanca. *Journal Marocain des Sciences Médicales*. 2009; 16 (3): 57-64.
- [13] Menye M, Nkoro GA, Lebogo KH, Kouotou EA. Skin cancer: epidemiological, clinical, and histological aspects in albinos and non-albinos in Yaoundé, Cameroon. *Our Dermatol Online*. 2023; 14 (2): 170-176.
- [14] Hadan D. Distribution of skin cancers of the head and neck according to anatomical subunit. *Eur Arch Otorhinolaryngol*. 2022; 279: 1461-6.
- [15] Fayek IS, Rifaat MA, Mohammed DB. Management and Clinico-Pathologic Aspects of Non-Melanoma Skin Cancer of the Head and Neck: A Retrospective Institutional Based Study at the Egyptian National Cancer Institute. *JCT*. 2019; 10: 846-62.
- [16] Grossi Marconi D, da Costa Resende B, Rauber E, de Cassia Soares P, Fernandes JM, Mehta N, et al. Head and Neck Non-Melanoma Skin Cancer Treated By Superficial X-Ray Therapy: An Analysis of 1021 Cases. *PLoS ONE*. 2016; 11: 156-544.
- [17] Ouedraogo MS, Zongo N, Ouedraogo NA, Tapsoba GP, Korsaga/Somé NN, Nyamba YB, et al. Black skin cancers in tropical Africa. *Annals of dermatology and venereology*. 2015; 142 (12); 389-390.
- [18] Lorient Y, Mordant P. Cancérologie. Issy-les-Moulineaux: Elsevier-Masson; 2011.
- [19] Dean N R, Sweeney L, Magouson J S, William R, Robinson D, Desmond R A Et al. Outcomes of Recurrent Head and Neck Cutaneous Squamous Cell Carcinoma; *Skin Cancer*. 2011; 97: 2492-9724.
- [20] Helgadottir H, Olsson H, Tucker MA, Yang XR, Höiom V, Goldstein AM. Phenocopies in melanoma-prone families with germ-line CDKN2A mutations. *Genet Med*. 2018; 20 (9): 1087-1090.
- [21] Kelder W, MD, PhD, Ardalan E, MBBS [Hons], FRACS et al. Cutaneous Head and Neck Squamous Cell Carcinoma with Regional Metastases: The Prognostic Importance of Soft Tissue Metastases and Extranodal Spread. *Surgical Oncology*. 2012, 19 (1) 274-27.
- [22] Vasconcelos L, Melo J C, Miot H A, Marques M E A and Abbade L F. Invasive head and neck cutaneous squamous cell carcinoma clinical and histopathological characteristics frequency of local recurrence and metastasis. *A Bras Dermatol*. 2014, 89 (4) 562-568.