

Efficacy and Safety of Combination Treatment of Oral Terbinafine and Itraconazole in Patients with Extensive Superficial Dermatophytes

Mohammad Enamul Hoque^{1,*}, Suraiya Akhter², Wahida Rahman³, Md. Mominul Hoque⁴

¹Department of Dermatology and Venereology, Army Medical College Cumilla & CMH Cumilla, Cumilla, Bangladesh

²Department of Pathology, Army Medical College Cumilla, Cumilla, Bangladesh

³Department of Pharmacology & Therapeutics, Army Medical College Cumilla, Cumilla, Bangladesh

⁴Department of Agricultural Extension, Agro-meteorological Information System, Dhaka, Bangladesh

Email address:

drenamul82@gmail.com (Mohammad Enamul Hoque)

*Corresponding author

To cite this article:

Mohammad Enamul Hoque, Suraiya Akhter, Wahida Rahman, Md. Mominul Hoque. (2024). Efficacy and Safety of Combination Treatment of Oral Terbinafine and Itraconazole in Patients with Extensive Superficial Dermatophytes. *International Journal of Clinical Dermatology*, 7(1), 1-5. <https://doi.org/10.11648/ijcd.20240701.11>

Received: January 8, 2024; Accepted: January 24, 2024; Published: February 5, 2024

Abstract: *Background:* Dermatophytosis, a prevalent fungal infection, is instigated by species like Trichophyton, Epidermophyton and Microsporum. The current approach for treating dermatophytosis involves a blend of systemic and topical antifungal therapies, applicable to all patients except those with localized, untreated Tinea. Notably, there is a growing incidence of inadequate response to the standard treatment regimen in recent times. *Objective:* To evaluate the efficacy and safety of combination treatment of oral terbinafine and itraconazole in patients with extensive superficial dermatophytes. *Materials and Methods:* This research comprised a randomized clinical trial involving 50 individuals diagnosed with extensive superficial dermatophytosis. Study conducted at the Department of Dermatology and Venereology, Combined Military Hospital Cumilla, the study spanned from July 2022 to June 2023. During the six-week duration, patients underwent treatment with terbinafine and itraconazole, with follow-up examinations every two weeks, including relevant investigations. Evaluation of treatment outcomes occurred at both four and six weeks. Statistical analysis was performed using version 25 of the Statistical Package for the Social Sciences (SPSS). *Results:* This study shows the majority of the participants within the age range of 16-30 years (56.0%) and the average age of the participants is 31.74±11.77 years. In terms of gender, the majority are male (78.0%). The most prevalent diagnosis is Tinea corporis (68.0%), followed by Tinea cruris (36.0%), Tinea faciei (28.0%), and Tinea incognito (12.0%). The majority of participants (85.0%) have had the disease for 12 months or less. The most common sites are the trunk (35.0%), whole body (26.0%), and crural area (24.0%). The majority of participants experience severe itching (56.0%), followed by moderate itching (34.0%), and a smaller percentage report mild itching (10.0%). The majority of participants showed improvement, with percentages increasing from 66.0% after 2 weeks to 84.0% after 4 weeks. The percentage of cured individuals also increased over time, reaching a substantial 90.0% after 6 weeks. *Conclusion:* The amalgamation of terbinafine and itraconazole demonstrates a superior clinical cure rate compared to use of single systemic antifungals. However, the observed clinical cure rate percentage is lower when juxtaposed with findings from previous studies. Notably, none of the used combination of systemic antimycotic medication has displayed success against tinea infections previously treated with topical formulations containing steroids.

Keywords: Safety, Combination Treatment, Terbinafine, Itraconazole, Dermatophytes

1. Introduction

Dermatophytosis stands out as a prevalent skin ailment

with a global impact, resulting from superficial fungi infiltrating and proliferating within keratinized tissues such as the skin, hair, and nails. Tinea, the condition associated with dermatophytosis, affects approximately 20-25% of the

world population [1, 2]. Over the last four decades, remarkable progress has been made in the management of this condition today due to evolution of the specialized antimycotic medication instead of using fundamental antiseptic having nonspecific and limited or no antifungal properties [1, 3].

The primary fungi responsible for dermatophytosis include Trichophyton, Microsporum, and Epidermophyton [1, 4]. Recently, there has been a shift in the tinea pattern, characterized by an increase in the prevalence of challenging-to-treat conditions such as recalcitrant, recurrent, and chronic dermatophytosis [3, 5]. Several factors contribute to the emergence of treatment-resistant tinea, including global warming, hot and humid climates, labor migration, frequent use of close-fitting and polyester clothing, obesity, inactive lifestyles, the rising occurrence of Trichophyton mentagrophytes, and poor compliance of the patients [1, 6, 7]. Besides, extensive use of available steroid-antifungal creams either directly purchased from the counters or advised by the practitioners or layman, functions as a significant contributor [8].

Terbinafine, the main drug that act systemically for dermatophytosis, operates as a first-line treatment by inhibiting squalene epoxidase, an enzyme involved in ergosterol synthesis crucial for fungal cell membrane formation [9]. Itraconazole exerts fungistatic action by inhibiting 14 α -demethylase, thereby hindering the formation of cell wall [10].

A conjugation therapy utilizing antifungal drugs that acts systemically with definite way of mechanisms has been shown higher cure rates and mitigate resistance of drugs, depending on synergic and additive effects of multiple medicines [1]. The effectiveness of both itraconazole and terbinafine in managing dermatophyte infections has been documented in several studies [7, 11-13]. From a clinical perspective, it becomes crucial for clinicians to assess the comparative efficacy of these two drugs in standard clinical scenarios. Consequently, the present study was designed to assess the safety and efficacy of a combined treatment involving terbinafine and itraconazole in patients with extensive superficial dermatophytes.

2. Materials and Methods

A non-blinded randomized clinical trial was conducted involving 50 extensive dermatophytosis patients attending the Outpatient Department (OPD) of the Department of Dermatology and Venereology at Combined Military Hospital (CMH) Cumilla from July 2022 to June 2023. The study-included patients with T. corporis, T. cruris, and T. faciei, T. incognito with a total body surface area involvement of 50%. Study has excluded women expecting baby and lactating, individuals having allergy to terbinafine or itraconazole, persons with a history of oral antifungal intake in the last month, patients with cardiac, renal, and hepatic diseases, abnormal complete blood count (CBC), renal function test, and liver function test (LFT). Enrolled

patients meeting the inclusion criteria provided informed consent before participation. The treatment involved administering terbinafine 250 mg and itraconazole 200 mg daily until lesion resolution or a maximum of 6 weeks. Patients were considered cured when there was an absence of scaling, erythema, and pruritus along with a negative KOH test.

Patients underwent evaluation for the severity of clinical parameters, specifically erythema, using a four-point scale: 0=none, 1=mild, 2=moderate, and 3=severe [1]. Initial, second-week, and fourth-week assessments included CBC, LFT, and-Electrocardiography (ECG). Patients were queried about any treatment-related side effects. Follow-up occurred at two-week intervals for a maximum of eight weeks (four weeks post-therapy or cure, whichever came first). Monitoring encompassed the treatment period and an additional four weeks post-treatment completion. The 'Rule of 9' was used to calculate Body Surface Area (BSA). Outcome measurements included ¹Cured, ²Partially Cured, and ³Failure. Statistical Package for Social Sciences Research (SPSS version 25) was used to organize and analyze the acquired data.

3. Results

The majority of the participants fall within the age range of 16-30 years (56.0%), followed by the age range of 31-45 years (34.0%). Only a small percentage are aged 46-60 years (6.0%), and there are even fewer participants above 60 years (4.0%). The average age of the participants is 31.74 years with a standard deviation of 11.77. In terms of gender, the majority are male (78.0%), and most participants are married (78.0%) (Table 1).

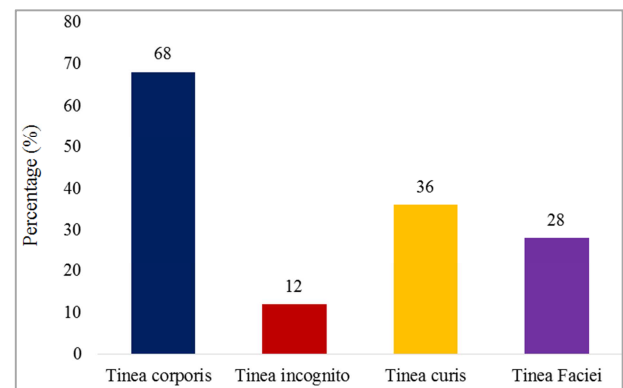


Figure 1. Diagnosis of disease of the study subject (n=50).

Table 1. Demographic characteristics of the study subject (n=50).

Age in years	Frequency	Percentage (%)
16-30	28	56.0
31-45	17	34.0
46-60	3	6.0

1 Absolute clinical resolution of the disease cases

2 More than 50% cured of the total BSA involved

3 After consecutive four weeks antifungal therapy severity of the disease increased or no improvement or less than 50% cured of total BSA involved

Age in years	Frequency	Percentage (%)
>60	2	4.0
Mean±SD	31.74±11.77	
Sex		
Male	39	78.0
Female	11	22.0
Marital status		
Married	36	72.0
Unmarried	14	28.0

The most prevalent diagnosis is Tinea corporis (68.0%), followed by Tinea cruris (36.0%), Tinea faciei (28.0%), and Tinea incognito (12.0%) (Figure 1).

The majority of participants (85.0%) have had the disease for 12 years or less, while a smaller percentage have had the disease for 1-3 years (8.0%) or more than 3 years (6.0%) (Table 2).

Table 2. Duration of disease of the study subject (n=50).

Duration	Frequency	Percentage (%)
≤12 months	43	85.0
1-3 months	4	8.0
>3 months	3	6.0

The most common sites are the trunk (35.0%), whole body (26.0%), and genital area (24.0%). Other sites include the axilla, back of the chest, perioral region, buttock, left thigh, scrotum, face, groin, axilla, neck & chest, hand and lower back (Table 3).

Table 3. Site of disease of the study subject (n=50).

Site of disease	Frequency	Percentage (%)
Crural area	12	24.0
Whole body	13	26.0
Trunk	15	35.0
Axilla	11	22.0
Back of the chest	3	6.0
Perioral region	3	6.0
Buttock	3	6.0
Thigh	4	8.0
Scrotum	4	8.0
Face	6	12.0
Axilla	3	6.0
Neck & chest	2	4.0
Hand	1	2.0
Lower back	1	2.0

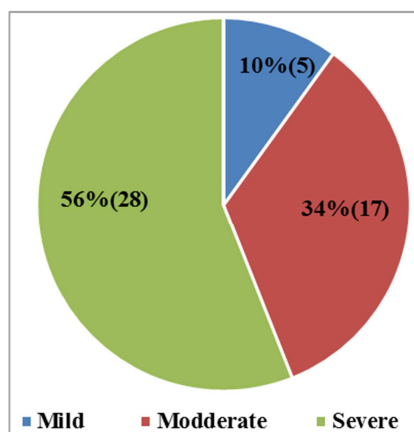


Figure 2. Itching of the study subject (n=50).

The majority of participants experience severe itching (56.0%), followed by moderate itching (34.0%), and a smaller percentage report mild itching (10.0%) (Figure 2).

The majority of participants showed improvement, with percentages increasing from 66.0% after 2 weeks to 84.0% after 4 weeks. The percentage of cured individuals also increased over time, reaching a substantial 90.0% after 6 weeks (Table 4).

Table 4. Follow up of study subject (n=50).

Follow up	Frequency	Percentage (%)
After 2 weeks		
Improved	33	66.0
Not improve	14	28.0
Cured	3	6.0
After 4 weeks		
Improved	42	84.0
Not improve	3	6.0
Cured	5	10.0
After 6 weeks		
Improved	3	6.0
Not improve	2	4.0
Cured	45	90.0

This table indicates that 4.0% of the participants experienced elevated liver enzymes as a complication during the study (Table 5).

Table 5. Complication of the study subject (n=50).

Complication	Frequency	Percentage (%)
Elevated liver enzymes	2	4.0

4. Discussion

Dermatophytosis is a prevalent superficial mycosis on a global scale [7, 14]. Numerous antifungal agents have been developed and more are in progress for treating this condition. Terbinafine stands out as one of the most widely employed antifungal drugs for superficial fungal infections due to its broad-spectrum fungicidal activity. The drug has consistently demonstrated efficacy against dermatophytes, that achieves cure rates exceeding 90% at a daily dose of 250 mg over a 2-week period [15].

However, recent observations note instances of clinical failure and relapses with terbinafine in patients with tinea infections, coinciding with an increased incidence of terbinafine resistance [16]. While resistance is not a common occurrence in case of terbinafine in clinical practice, a few authors have reported it in clinical isolates [6-8]. Majid et al. revealed in their study that only 43 out of 100 cases were able to maintain a long-term clinical and mycological cure after a 2-week oral terbinafine treatment, emphasizing the prevalence of incomplete mycological cure and relapse after standard terbinafine therapy for tinea corporis/cruris [16].

One of the primary mechanisms behind antifungal resistance is a decrease in effective drug concentration [17]. This phenomenon is well-established in terbinafine due to its standard dosing regimen of 250 mg daily, that causes accumulation of drug in skin and adipose tissue [9]. This

underscores that the current standard terbinafine therapy with a 250 mg/day dose may not be sufficient in the present context, whereas resistance of fungus is exacerbated by increased usage, inappropriate prescribing, and over-the-counter sales of antifungal agents [10, 11].

While there is no definitive evidence on the optimal strategy to prevent resistance [7]. Historically, the most commonly recommended measures have included the judicious use of antifungals and appropriate dosing, with a specific emphasis on avoiding low antifungal dosage treatments [14]. This study reported the mean age of the participant's was 31.74 ± 11.77 years. In terms of gender distribution, 78% of all participants were male, and 56% of the total study cohort fell within the range of the age of 16-30 years. Notably, 85% of the cases exhibited dermatophytosis, duration not over 12 months. These findings align well with the results of other studies [3-8, 10]. For instance, Ramesh *et al.* [1] reported a mean participant age of 36.47 ± 11.03 years in their study. Accordingly, 64.9% of all patients were female, and 66.7% of the whole study participants represent the age class of 18-40 years. Additionally, previous studies have been showed that 75.4% of the patients had disease not over six months.

This study indicates that the most prevalent variant was tinea corporis accounting for 68%, consistent with findings in prior studies [1, 15-17]. In a study by Ramesh *et al.* a similar pattern was observed, with the most common variant being tinea corporis constituting 71.9% in the present study¹. In this investigation, the aim was to assess the effectiveness and safety of once-daily terbinafine and itraconazole in patients with extensive dermatophytosis. Results revealed a progressive improvement, with 66% of patients showing improvement in the 2-week group, 84% in the 4-week group, and 96% achieving clinical cure in the 6-week group. These outcomes align with previous findings reported by different authors. Majid *et al.* found 87% patients are clinically cure from tinea corporis who were treated with terbinafine at 500 mg/day [16]. Similarly, Sanglard D reported 100% cure rates in patients with tinea pedis those who were treated with terbinafine at 250 mg twice daily [17]. Dolton *et al.* documented that 81.3% patients were clinically cure and 75% patients were mycologically cure with terbinafine in patients with onychomycosis [18].

This study comes with specific limitations due to its observational nature and survey design, the potential for selection bias cannot be entirely eliminated. Additionally, the study did not account for the use of other antifungal treatments which could have influenced the ultimate outcome. There is a need for long-term comparative studies to address the short comings identified in the present investigation.

5. Conclusion

This study indicates that the combined use of terbinafine and itraconazole result in a superior clinical recovery rate. However, neither combination proved effective against tinea infections that had been previously treated with formulations

containing topical steroids. There is a pressing need for strict legislation to curb the unjustified use of topical corticosteroid antifungal combination creams. Special attention needed to raise awareness among general practitioners about the misuse of topical steroid antifungal preparations. Sensitizing the general people to adopt preventive steps against tinea. Additionally, appropriate treatments for others members of family will assist to downgrade the infections or cases burden.

Abbreviations

ADMS: Assistant Director of Medical Service
 CBC: Complete Blood Count
 CMH: Combined Military Hospital
 ECG: Electrocardiography
 LFT: Liver Function Test
 OPD: Out Patient Department
 SPSS: Statistical Package for Social Sciences Research

Conflicts of Interest

The authors declare no conflicts of interest.

References

- [1] Ramesh A, Devasena S, Mathew D. Efficacy and Safety of Oral Terbinafine with Itraconazole or Griseofulvin Combination Therapy in the Management of Dermatophytosis-A Randomised Clinical Trial. *Journal of Clinical & Diagnostic Research*. 2022 Jan 1; 16(1): 175-180.
- [2] Havlickova B, Czaika VA, Friedrich M. Epidemiological trends in skin mycoses worldwide. *Mycose*. 2008; 51: 02-15.
- [3] Hay R. Therapy of skin, hair and nail fungal infections. *J. Fungi (Basel)*. 2018; 4(3): 99.
- [4] Rajabian A, Hosseinzadeh H. Dermatological effects of nigella sativa and its constituent, thymoquinone. In: Preedy VR, Watson RR, editors. *Nuts and Seeds in Health and Disease Prevention*. San Diego, CA: Elsevier; 2020. Pp. 329–55.
- [5] Dogra S, Uprety S. The menace of chronic and recurrent dermatophytosis in India: Is the problem deeper than we perceive? *Indian Dermatol Online J*. 2016; 7(2): 73-76.
- [6] Rengasamy M, Chellam J, Ganapati S. Systemic therapy of dermatophytosis: Practical and systematic approach. *Clin Derm Rev*. 2017; 1(3): 19-23.
- [7] Babu PR, Pravin A, Deshmukh G, Dhoot D, Samant A, Kotak B. Efficacy and safety of terbinafine 500 mg once daily in patients with dermatophytosis. *Indian J Dermatol*. 2017; 62(4): 395-399.
- [8] Dutta B, Rasul E, Boro B. Clinico-epidemiological study of tinea incognito with microbiological correlation. *Indian J Dermatol Venereol Leprol*. 2017; 83(3): 326.
- [9] Lipner SR, Scher RK. Onychomycosis: Treatment and prevention of recurrence. *J Am Acad Dermatol*. 2019; 80(4): 853-67.

- [10] Gupta AK, Mays RR, Versteeg SG, Piraccini BM, Shear NH, Piguet V, et al. Tinea capitis in children: A systematic review of management. *J Eur Acad Dermatol Venereol*. 2018; 32(12): 2264-2274.
- [11] Kumar G, Saxena K, Koti VR. A comparative study on efficacy of oral terbinafine and itraconazole on dermatophytic infections. *Int J Res Dermatol*. 2022 Jul; 8(4): 381-387.
- [12] Shi TW, Zhang JA, Zhang XW, Yu HX, Tang YB, Yu JB. Combination treatment of oral terbinafine with topical terbinafine and 10% urea ointment in hyperkeratotic type tinea pedis. *Mycoses*. 2014; 57(9): 560-4.
- [13] Li RY, Wang AP, Xu JH, Xi LY, Fu MH, Zhu M, et al. Efficacy and safety of 1% terbinafine film-forming solution in Chinese patients with tinea pedis: A randomized, double-blind, placebo-controlled, multicenter, parallel-group study. *Clin Drug Investig*. 2014; 34(3): 223-30.
- [14] Sharma P, Bhalla M, Thami GP, Chander J. Evaluation of efficacy and safety of oral terbinafine and itraconazole combination therapy in the management of dermatophytosis. *J Dermatolog Treat*. 2020; 31(7): 749-753.
- [15] Newland JG, Abdel-Rahman SM. Update on terbinafine with a focus on dermatophytoses. *Clin Cosmet Investig Dermatol*. 2009; 2: 49-63.
- [16] Majid I, Sheikh G, Kanth F, Hakak R. Relapse after oral terbinafine therapy in dermatophytosis: A clinical and mycological study. *Indian J Dermatol*. 2016; 61(5): 529-33.
- [17] Sanglard D. Emerging threats in antifungal-resistant fungal pathogens. *Front Med (Lausanne)* 2016; 3: 11.
- [18] Dolton MJ, Perera V, Pont LG, McLachlan AJ. Terbinafine in combination with other antifungal agents for treatment of resistant or refractory mycoses: Investigating optimal dosing regimens using a physiologically based pharmacokinetic model. *Antimicrob Agents Chemother*. 2014; 58(1): 48-54.