



Surgical Management of Skeletal Class II Deformity Patients- a Case Series

Mehta Payal^{1,*}, Nimisha Desai¹, Nehal Patel², Tushar Makwana¹

¹Department of Oral and Maxillofacial Surgery, Karnavati School of Dentistry, Gandhinagar, India

²Fellowship in Cleft and TMJ, ABMSS Cleft Center, Surat, India

Email address:

mehtapayal199326@gmail.com (M. Payal)

*Corresponding author

To cite this article:

Mehta Payal, Nimisha Desai, Nehal Patel, Tushar Makwana. Surgical Management of Skeletal Class II Deformity Patients- a Case Series *International Journal of Clinical Oral and Maxillofacial Surgery*. Vol. 6, No. 2, 2020, pp. 49-55. doi: 10.11648/j.ijcoms.20200602.16

Received: October 20, 2020; **Accepted:** November 6, 2020; **Published:** December 8, 2020

Abstract: Class II malocclusions constitute a high percentage of ortho-surgically treated cases. Approximately 70% of the patients have associated skeletal discrepancy characterized by an exaggerated sagittal distance between the maxilla and the mandible, which could result in maxillary prognathism, mandibular retrognathism, or both (2) Class II malocclusion can be treated by a combination of maxillary and mandibular surgeries, maxillary surgery alone or by mandible surgery solely depending on the underlying skeletal discrepancy i.e Maxillary Le Fort I superior repositioning with autorotation of mandible, Bi-jaw surgery—bilateral sagittal split osteotomy (BSSO) along with maxillary Le Fort I impaction., Genioplasty-advancement of chin. Material and methods: 10 cases of Skeletal Class –II malocclusion were selected randomly irrespective of age, sex, caste, religion, etiology and socioeconomic status, good general health without any systemic disease. Study was conducted in the Department of Oral and Maxillofacial Surgery, Karnavati School of Dentistry, Uvarsad. Conclusion: 14 According to the outcomes of the cases it provided a reliable esthetic and functional enhancement of the patient when maxilla was superiorly positioned, with mandibular advancement, genioplasty for retruded chin according to the treatment planned for each patient.

Keywords: Skeletal Class II, Deformity, Orthognathic Surgery, Surgical Management

1. Introduction

Class II malocclusions constitute a high percentage of ortho-surgically treated cases [4], Approximately 70% of the patients have associated skeletal discrepancy characterized by an exaggerated sagittal distance between the maxilla and the mandible, which could result in maxillary prognathism, mandibular retrognathism, or both [2]. Class II malocclusion can be treated by a combination of maxillary and mandibular surgeries, maxillary surgery alone or by mandible surgery solely depending on the underlying skeletal discrepancy i.e Maxillary Le Fort I superior repositioning with autorotation of mandible, Bi-jaw surgery—bilateral sagittal split osteotomy (BSSO) along with maxillary Le Fort I impaction., Genioplasty-advancement of chin. When there are severe skeletal components also associated with that malocclusion, such as a vertical growth pattern and a retruded mandible, a combined surgical approach is often the best treatment option [5]. Treatment choices for preadolescents and teenagers are

particularly difficult because of the uncertainty regarding the magnitude and direction of remaining growth. The results obtained by surgical management of such cases usually ensure a better esthetic, functional stability [1]. The goal of orthognathic surgery is basically to achieve harmony between functional stability and esthetic enhancement [3, 6, 7] which thereby fulfils patients need. So here in this study we have evaluated result of 10 patients of skeletal class II deformity treated surgically and their outcomes we have discussed.

2. Aims and Objectives

The aim of the study was to surgically correct with either Bilateral sagittal split osteotomy, Lefort I osteotomy, genioplasty or Bijaw surgery as indicated in skeletal class II deformity patients. The objective of this study was: To study different cases of skeletal class II malocclusion, to surgically correct facial asymmetry, to achieve stable occlusion, to achieve satisfactory esthetics and function.

3. Materials and Methods

3.1. Methods of Data Collection

Definition of Study Subject

10 cases of Skeletal Class –II malocclusion were selected randomly irrespective of age, sex, caste, religion, etiology and socioeconomic status, good general health without any systemic disease. Study was conducted in the Department of Oral and Maxillofacial Surgery, Karnavati School of Dentistry, Uvardsad for evaluation of different treatment modalities such as Maxillary Le Fort I superior repositioning with autorotation of mandible, Bi-jaw surgery—bilateral sagittal split osteotomy (BSSO) along with maxillary Le Fort I impaction., Genioplasty—advancement of chin for surgical management of skeletal Class-II deformity.

It is a retrospective human study and ethical committee and all authors have got institutional review board approval.

3.2. Method (Study Design)

According to each patient requirement different osteotomy procedures were carried out for 10 different patients. They were as follows: as Maxillary Le Fort I superior repositioning with autorotation of mandible, Bi-jaw surgery - Bilateral sagittal split osteotomy (BSSO) along with maxillary Le Fort I impaction., Genioplasty - advancement of chin for surgical management of skeletal Class-II deformity.

4. Discussion

Deformities at an early age, when the patient is still growing, have the potential to be corrected with growth-modifying appliances. But in adults Class II malocclusion, surgical intervention to reposition the jaws and dentoalveolar segments becomes the only option to treat such patients where growth modulation is not possible using fixed functional appliances (FFA), headgear, camouflage to mask the underlying skeletal discrepancy [10]. This cases can be treated by a combination of maxillary and mandibular surgeries, maxillary surgery alone or by mandible surgery solely depending on the underlying skeletal discrepancy. Maxillary Le Fort I (superior repositioning) with autorotation of mandible, Bi-jaw surgery—bilateral sagittal split osteotomy (BSSO) along with maxillary Le Fort I

superior positioning., Genioplasty—advancement of chin. The results obtained by surgical as well as orthodontic management of such cases usually ensure a better esthetic, functional stability.

10 patients of skeletal class II have been treated surgically and results evaluated were: Out of 10 cases 3 patients underwent Bijaw surgery. And 7 patients underwent Single jaw surgery. In the cases of vertical maxillary excess cases single jaw surgery was planned in most of the cases. “Careful diagnosis and treatment planning is required for successful outcome of any Skeletal class II patient-Hanumath et al [8]. It is Sometimes difficult to improve labially inclined teeth, particularly in patients with mandibular retrognathia, because symphysis menti is often thin. Insufficient space therefore is available to permit sagittal rotation of the teeth without root exposure from the alveolar bone. And so 3 staged method for correction of skeletal discrepancy is advised (Kazuhiro Matsushita). Genioplasty for retruded chin and constructing infrastructure for subsequent le fort 1 osteotomy and then lefort 1 osteotomy itself is carried, finally a two-jaw surgery.

5. Conclusion

Overall Class II malocclusions require careful diagnosis and treatment planning for a successful outcome [12]. Treatment planning according to the level of discrepancy ensures stability and good outcome [8, 9]. Orthodontics play a crucial role in management and patient satisfaction. Surgical superior repositioning of the maxilla for aesthetic and functional correction of selected dentofacial deformities, especially open bite deformity, produces an optimum aesthetic correction of the deformity with excellent stability [13]. Mandibular sagittal split osteotomy in combination with pre- and postsurgical orthodontics is an efficient approach in the therapy of adult Class II, division 1 malocclusion. Sagittal occlusal malrelationships are corrected and the hard- and soft tissue profiles straightened in a consistent way [14]. According to the outcomes of the cases it provided a reliable esthetic and functional enhancement of the patient when maxilla was superiorly positioned, with mandibular advancement, genioplasty for retruded chin according to the treatment planned for each patient.

Result: the different surgeries done in 10 different patients accordingly are summarised in Table 1.

Table 1. Data of 10 Patients with Skeletal Class II Patients which Were Surgically Managed by Different Orthognathic Surgery.

Sr. no	Patients Name	AGE/sex	Single Jaw / bi jaw surgery	Surgery done before starting orthodontic treatment completed	Surgery done after preorthodontic treatment completed	Surgery done after orthodontic treatment Completed
1.	PURVA BHOJANI	23/F	Single jaw	x	√	x
2.	HIRAL PATEL	15/F	Single jaw	x	√	x
3.	SUMITA BALAR	20/F	Bi jaw	x	√	x
4.	PARTH TANNA	18/M	Single jaw	x	√	x
5.	NARESHBHAI	25/M	Single jaw	x	√	x
6.	SANJAY VANKAR	24/M	Single jaw	x	√	x
7.	DEEPA PRAJAPATI	20/F	Bi jaw	x	√	x
				x	x	√
8.	ASHA HALMATI	15/F	Bi jaw	√	x	x
				x	√	x

Sr. no	Patients Name	AGE/sex	Single Jaw / bi jaw surgery	Surgery done before starting orthodontic treatment completed	Surgery done after preorthodontic treatment completed	Surgery done after orthodontic treatment Completed
9.	MIRALI RIBADIYA	16/F	Bi jaw	x	√	x
10.	SONIYA	20/F	Single jaw	x	√	x

Table 1. Continued.

Sr. no	Patients Name	Osteotomy performed	Treatment done	Advancement /rotation/superior positioning performed
1.	PURVA BHOJANI	Mandibular Osteotomy	bilateral sagittal split osteotomy	Advancement of 4mm on RIGHT SIDE And 7mm on LEFT SIDE of mandible
2.	HIRAL PATEL	Mandibular Osteotomy	bilateral sagittal split osteotomy	Advancement of 6mm on RIGHT SIDE And 8mm on LEFT SIDE of mandible
3.	SUMITA BALAR	Maxillary and mandibular osteotomy	left i osteotomy right side bilateral sagittal split osteotomy	Advancement of 4mm on RIGHT SIDE of mandible
4.	PARTH TANNA	Maxillary osteotomy	left i osteotomy	Superior positioning of maxilla i.e anteriorly 6mm and posteriorly 5mm
5.	NARESHBHAI	Mandibular Osteotomy	bilateral sagittal split osteotomy	Advancement of 6mm on RIGHT SIDE And 7mm on LEFT SIDE of mandible
6.	SANJAY VANKAR	Maxillary osteotomy	left i osteotomy	Superior positioning of maxilla i.e anteriorly 6mm and posteriorly 4mm
7.	DEEPA PRAJAPATI	Maxillary osteotomy	left i segmental osteotomy	Anterior maxillary setback
8.	ASHA HALMATI	Mandibular osteotomy	Advancement of mandible was done genioplasty	Advancement of mandible
		Maxillary osteotomy	left i segmental osteotomy	Anterior maxillary setback
9.	MIRALI RIBADIYA	Maxillary osteotomy	left i osteotomy	Superior positioning of maxilla
		Mandibular osteotomy	bilateral sagittal split osteotomy genioplasty	Advancement of mandible
10.	SONIYA	Maxillary osteotomy	left i osteotomy	Superior positioning of maxilla i.e anteriorly 5mm and posteriorly 3mm

Case-1

Name- Poorva

Age - 23/F

Single/Bijaw - Single jaw surgery.

Treatment Done- BILATERAL SAGITTAL SPLIT OSTEOTOMY.

(Advancement of 4mm on RIGHT SIDE And 7mm on LEFT SIDE of mandible.)

Preoperative Photographs.

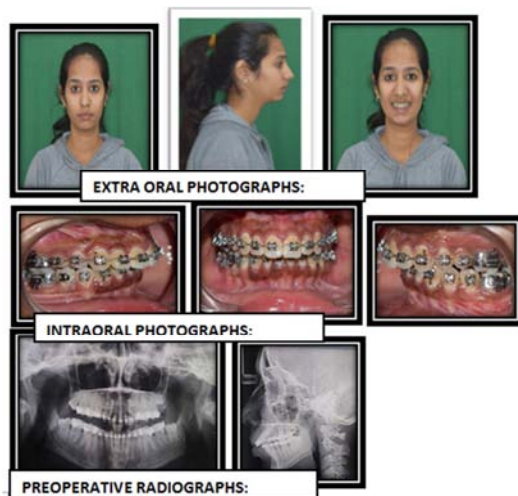


Figure 1. Extraoral photograph-front view lateral view; intraoral photographs, preoperative radiograph- OPG, Lateral cephalogram.

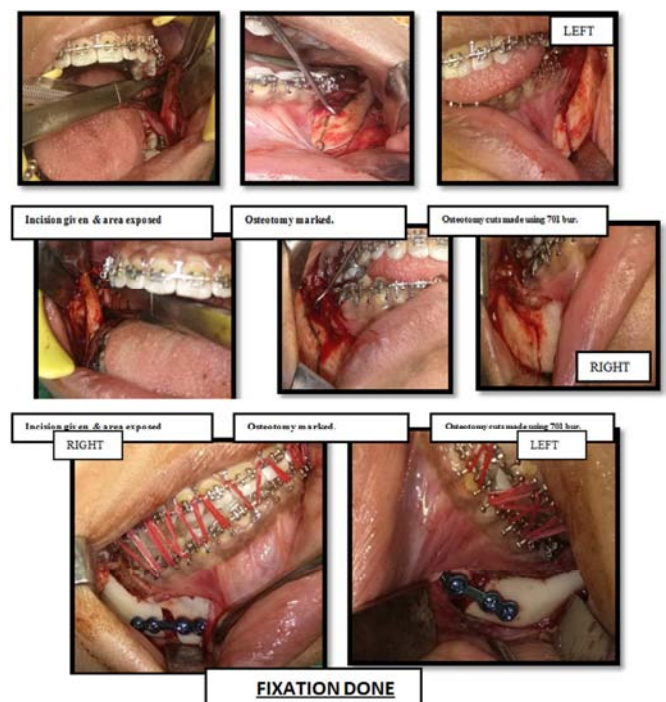


Figure 2. Treatment Done: Bilateral Sagittal Split Osteotomy.

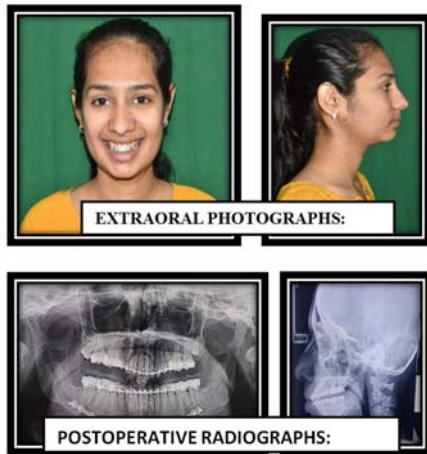


Figure 3. Postoperative records.

Case-2

Name- HIRAL

Age - 15/F

Single/Bijaw - Single jaw surgery.

Treatment Done- BILATERAL SAGITTAL SPLIT OSTEOTOMY.

(Advancement of 6mm on RIGHT SIDE And 8mm on LEFT SIDE of mandible.)

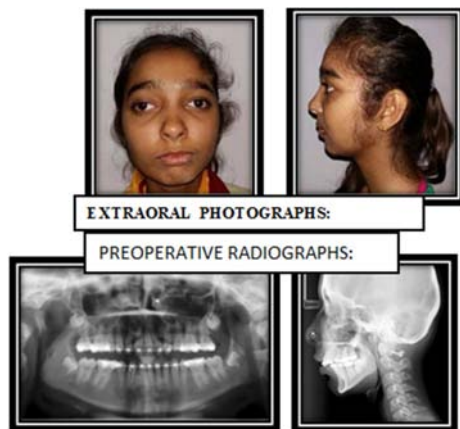


Figure 4. Preoperative records.

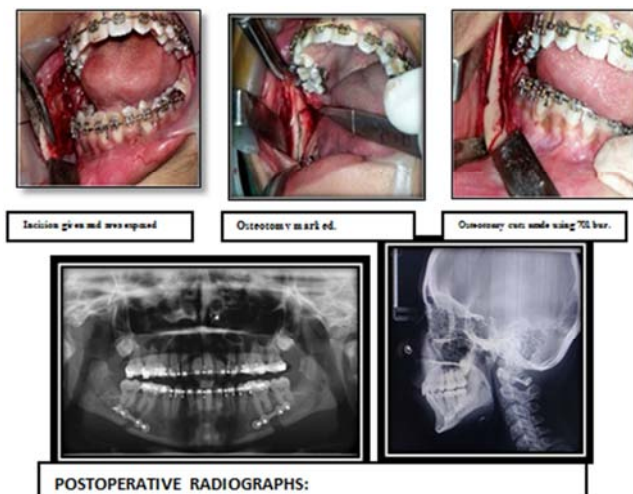


Figure 5. Treatment done.

Case-3

Name- SUMITA

Age - 20/F

Single/Bijaw - Bi jaw surgery.

Treatment Done- LEFORT I OSTEOTOMY

RIGHT SIDE BILATERAL SAGITTAL SPLIT OSTEOTOMY

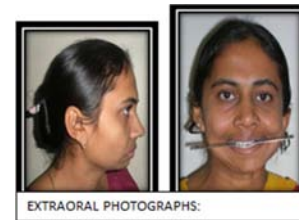

Figure 6. Preoperative records.

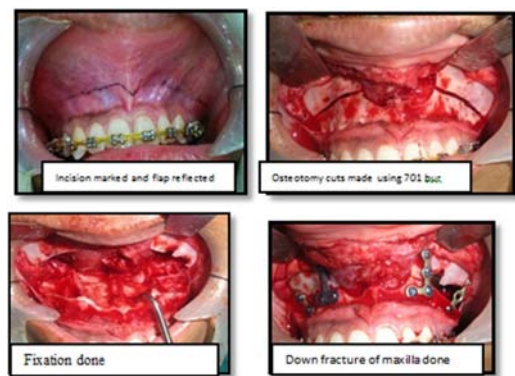


Figure 7. Treatment done: lefort I osteotomy.

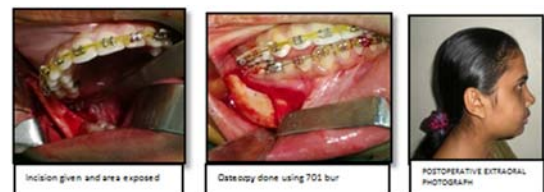

Figure 8. Bilateral sagittal split osteotomy.

Case-4

Name- PARTH

Age - 18/M

Single/Bijaw - Single jaw surgery.

Treatment Done- LEFORT I OSTEOTOMY

PREOPERATIVE RECORDS:

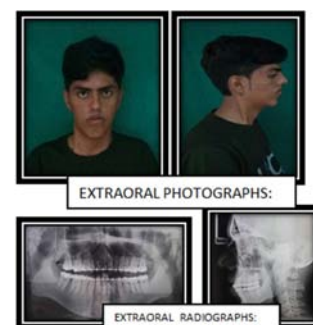

Figure 9. Preoperative photographs.

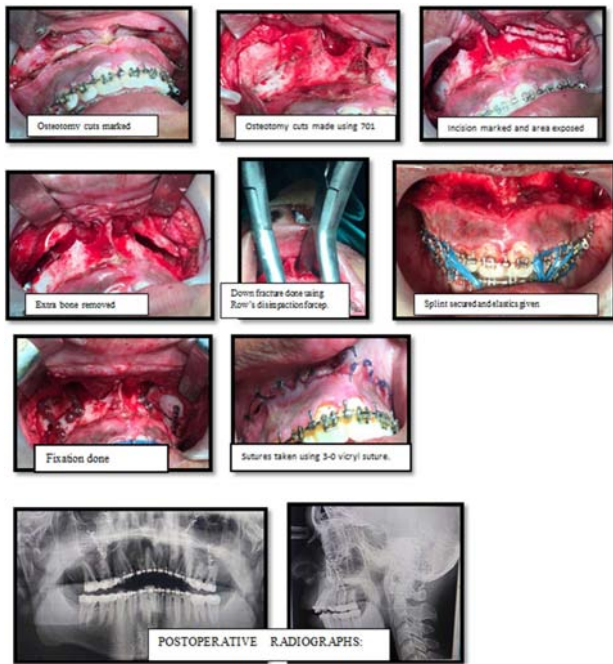


Figure 10. Treatment done: left I osteotomy.

Case-7

Name- Deepa

Age - 20/F

Single/Bijaw - Bi jaw surgery.

Treatment Done-1. LEFORT I SEGMENTAL OSTEOTOMY, 2. GENIOPLASTY

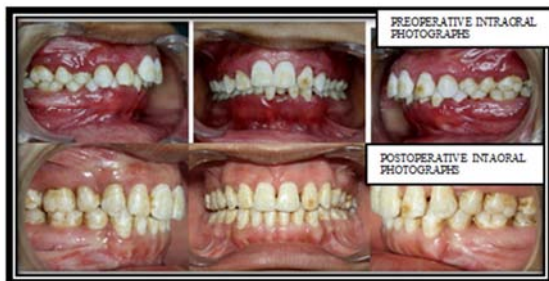
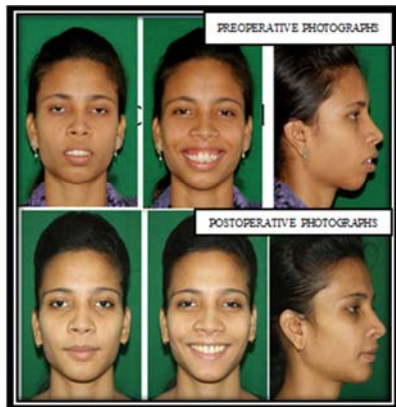

Figure 11. Preoperative record.

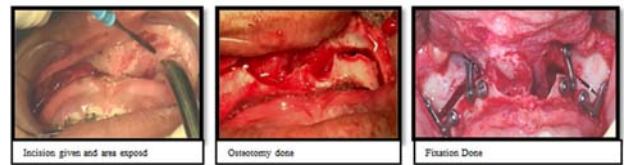

Figure 12. Treatment done: left I osteotomy.

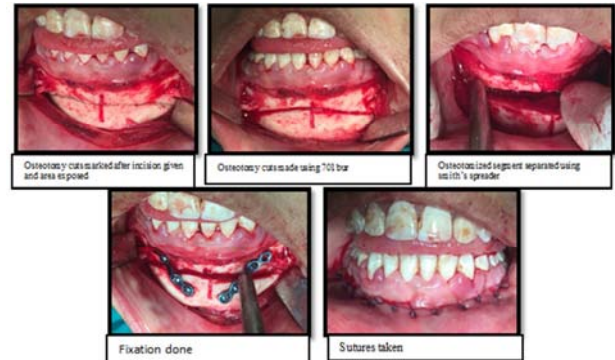


Figure 13. Genioplasty.

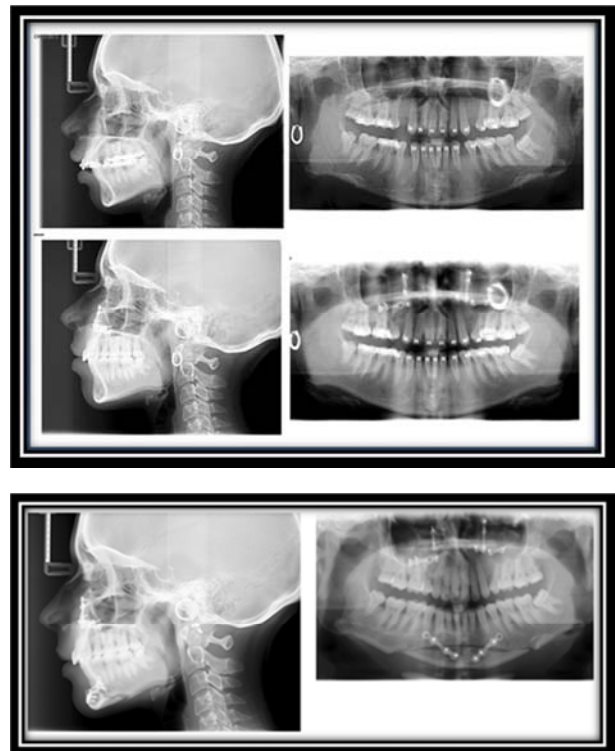


Figure 14. Radiographs.

Case-8

Name- MIRALI

Age - 16/F

Single/Bijaw - Single jaw surgery.

Treatment Done- 1. LEFORT I OSTEOTOMY

2. BILATERAL SAGITTAL SPLIT OSTEOTOMY.

3. GENIOPLASTY



Figure 15. Preoperative records.

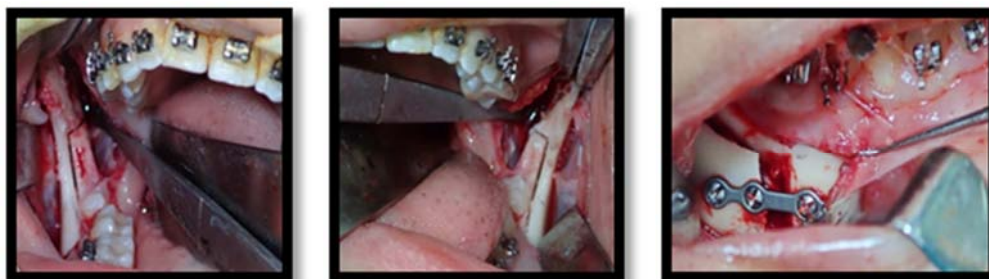

Figure 16. Bilateral sagittal split osteotomy.

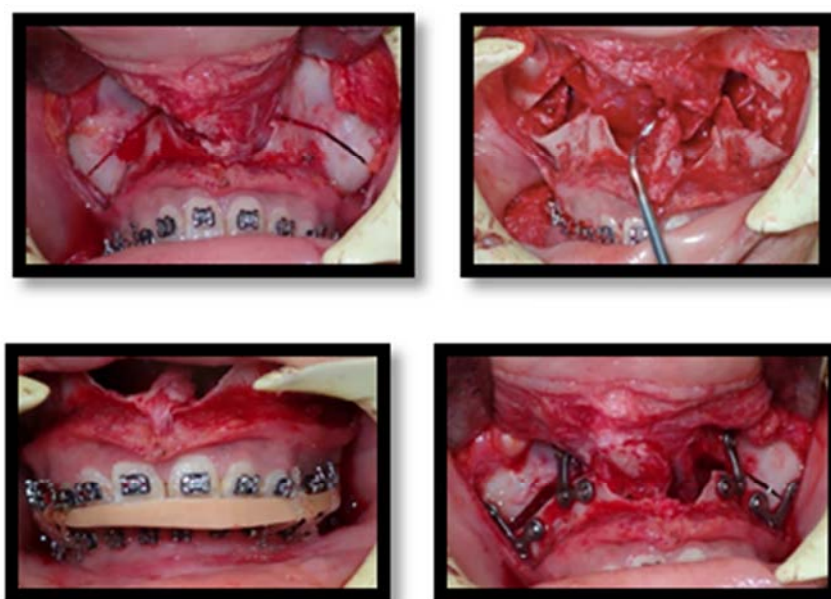


Figure 17. Lefort I osteotomy.

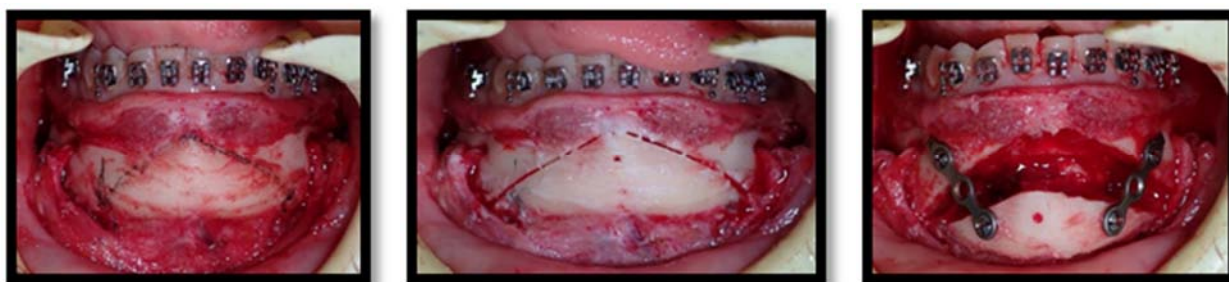

Figure 18. Genioplasty.

References

- [1] Sundararajan S, Parameswaran R, Vijayalakshmi D. Orthognathic surgical approach for management of skeletal class II vertical malocclusion. *Contemp Clin Dent*. 2018 Jun 1; 9 (5).
- [2] Donjuán Villanueva JJ, Vásquez Estrada HA, Hernández Carvallo JR, Nachón García MG. Surgical-orthodontic treatment in a class II malocclusion patient. Case report. *Rev Mex Ortod*. 2016.
- [3] Gupta H, Autar R, Abraham J, Bagchi P, Gupta S. Combined orthodontic and surgical correction of adult skeletal class II with hyperdivergent jaws. *Natl J Maxillofac Surg*. 2012; 3 (1): 6.
- [4] Sarnat BG. Effects and noneffects of personal environmental experimentation on postnatal craniofacial growth. *J Craniofac Surg*. 2001; 12 (3): 205–1.
- [5] Janson M, Janson G, Sant’Ana E, Simão TM, De Freitas MR. An orthodontic-surgical approach to class II subdivision malocclusion treatment. *J Appl Oral Sci*. 2009; 17 (3): 266–7.
- [6] Forssell K, Turvey TA, Phillips C, Proffit WR. Superior repositioning of the maxilla combined with mandibular advancement: Mandibular RIF improves stability. *Am J Orthod Dentofac Orthop*. 1992; 102 (4): 342–5.
- [7] Matsushita K, Yamaguchi HO, Koshikawa-Matsuno M, Inoue N. Evaluation of a three-stage method for improving mandibular retrognathia with labially inclined incisors using genioplasty, segmental osteotomy, and two-jaw surgery. *Case Rep Med*. 2014; 201.
- [8] Krishna Nayak US. Surgical Orthodontic treatment of Skeletal Class II malocclusion. Vol. 3, *Journal of Scientific Dentistry*.
- [9] Katta A, Rajasigamani K, Balachander R, Karthik K. Surgical correction of class II skeletal malocclusion in an adult patient. *J Orofac Sci [Internet]*. 2014 [cited 2019 Dec 5]; 6 (1): 5 Available from: <http://www.jofs.in/text.asp?2014/6/1/58/132587>.
- [10] Chhibber A, Upadhyay M, Uribe F, Nanda R. Long-term surgical versus functional Class II correction: A comparison of identical twins. *Angle Orthod*. 2015 Jan 1; 85 (1): 142–5.
- [11] Daokar ST, Agrawal G, Chaudhari C, Yamyar S. Ortho-surgical Management of Severe Skeletal Class II Div 2 Malocclusion in Adult. *Orthod J Nepal*. 2018 Jan 7; 7 (1): 44–5.
- [12] Wertz RA. Diagnosis and treatment planning of unilateral class II malocclusions. *Angle Orthod*. 1975; 45 (2): 85–9.
- [13] Schendel SA, Eisenfeld JH, Bell WH, Epker BN. Superior repositioning of the maxilla: Stability and soft tissue osseous relations. *Am J Orthod*. 1976; 70 (6): 663–7.
- [14] Epker BN, Fish LC. Surgical superior repositioning of the maxilla: What to do with the mandible? *Am J Orthod*. 1980; 78 (2): 164–9.