



# Stevens-Johnson Syndrome Associated to the Administration of Janssen AD26.COVS2 COVID-19 Vaccine in Tijuana, Baja California, México, a Case Report

Daniel Pacheco Ambriz<sup>1</sup>, Lorena Lizbeth Félix Guerrero<sup>2</sup>, Giselle Anahí Olivas Cárdenas<sup>2</sup>, Alicia Pastora Amarillas Villalvazo<sup>3</sup>, Lorena Diaz Amezcua<sup>4</sup>

<sup>1</sup>Emergent Care Unit, Regional General Hospital #20 IMSS, Tijuana, México

<sup>2</sup>Emergent Care Unit Rotation, Universidad Autonoma de Baja California, Regional General Hospital #20 Instituto Mexicano del Seguro Social (IMSS), Tijuana, México

<sup>3</sup>Dermatology Department, Regional General Hospital #20 Instituto Mexicano del Seguro Social (IMSS), Tijuana, México

<sup>4</sup>Pathology Department, Regional General Hospital #1 Instituto Mexicano del Seguro Social (IMSS), Tijuana, Mexico

## Email address:

tio76@hotmail.com (D. P. Ambriz)

## To cite this article:

Daniel Pacheco Ambriz, Lorena Lizbeth Félix Guerrero, Giselle Anahí Olivas Cárdenas, Alicia Pastora Amarillas Villalvazo, Lorena Diaz Amezcua. Stevens-Johnson Syndrome Associated to the Administration of Janssen AD26.COVS2 COVID-19 Vaccine in Tijuana, Baja California, México, a Case Report. *International Journal of Clinical Oral and Maxillofacial Surgery*. Vol. 8, No. 1, 2022, pp. 1-4. doi: 10.11648/j.ijcoms.20220801.11

**Received:** November 10, 2021; **Accepted:** December 7, 2021; **Published:** January 24, 2022

**Abstract:** *Background:* Stevens-Johnson syndrome and toxic epidermal necrolysis are rare pathologies characterized by mucocutaneous involvement, considered as late hypersensitivity mainly associated with drugs. Other less frequent causes include infections, vaccines, systemic diseases and botanical medicine. COVID-19 vaccines can cause adverse reactions mainly from vaccine-induced immune responses. We present a clinical case of a patient with Stevens-Johnson syndrome diagnose, without no history of factors related to this pathology, except for the use of Ad26.COVS2 (Janssen/Johnson & Johnson) vaccine *Clinical case:* A 20 years old male patient with clinical and histopathological characteristics compatible with Stevens Johnson syndrome and whose background history was the application of the Ad26.COVS2 vaccine (Janssen / Johnson & Johnson) 11 days prior to the start of the disease. At arrival at the emergency room he got a dermatologic consult who started treatment with metilprednisolone 1gr intravenously, Aciclovir 200mg orally and topic fluocinolone. He was hospitalized in charge of dermatology presenting improvement deciding outpatient treatment. Five days after his hospital discharge, at dermatology external consultation he's found with overall improvement and fewer dermic lesions. *Conclusions:* At this time we didn't find a case where they reported Stevens-Johnson syndrome associated to Ad26.COVS2 vaccine. Although the information regarding the adverse effects of the new vaccines against COVID-19 is still limited, there is the possibility of a direct association between the Ad26.COVS2 vaccine and a Stevens Johnson Syndrome.

**Keywords:** Stevens Johnson Syndrome, Toxic Epidermal Necrolysis, COVID-19, Ad26.COVS2 Vaccine

## 1. Background

Stevens – Johnson Syndrome and Toxic Epidermal Necrolysis are rare entities, it has a 2 - 7 cases per million incidence by year. Stevens-Johnson Syndrome is the less severe presentation and is three times more frequent than Toxic Epidermal Necrolysis. The mortality rate of Stevens-Johnson is 10% [1].

The most common precipitating factors are drugs. It usually presents 8 weeks following exposure, in children and adults, mostly between the 4 days and 4 weeks period. Mycoplasma Pneumoniae infection is the second most frequent etiology. Other associated risk factors, although less frequent, are botanical medicine, vaccines, systemic diseases and contrast dye [1].

The pathogenesis is not well known, but it's considered a type IV hypersensitivity mediated by T cells, possibly caused

by vaccine components eliciting an immune dysregulation, leading to a T-lymphocyte auto-immune response [2].

Both pathologies can present erythematous or violaceous patches, atypical target lesions, blisters, excoriations and ulcers. The blisters usually present a positive Nikolsky sign (sliding of the top layer of skin when its lightly rubbed) [3].

The distinctive feature is the affection of the mucosa (present in 80% of the cases), mostly oral mucosa over ocular, genital or anal mucosa. Systemic symptoms, though not present in all cases, can present themselves before the skin and mucosa features about three days. The symptoms are: skin pain, eye pain or other mucous membranes, headache, rhinitis general malaise, sore throat, cough and myalgia [4].

By definition Stevens-Johnson syndrome affects less than 10% of the body surface, the overlap of Steven-Johnson Syndrome and Toxic epidermal Necrolysis undertake about 10-30%. Toxic Epidermal Necrolysis (also known as Lyell syndrome) involves > 30% of skin. The histopathological findings include subepidermic blisters with generalized necrosis y apoptotic keratinocytes, associated with a minimal lymphocytic inflammatory infiltrate [5].

Coronavirus disease 2019 (COVID-19) vaccines are considered the most effective intervention to control the worldwide coronavirus epidemics we are nowadays confronted with [6].

However, as for all types of drugs and vaccines, COVID-19 vaccines can cause adverse reactions mainly from vaccine- induced immune responses [7].

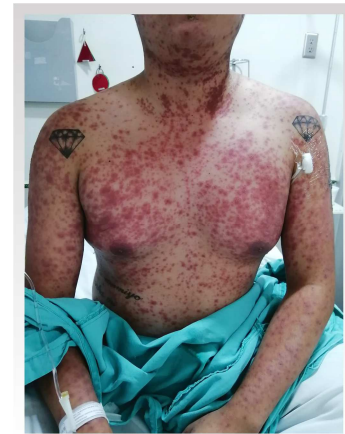Next we present a clinical case of a patient with Stevens-Johnson syndrome diagnose, without no history of factors related to this pathology, except for the use of Ad26.COVID2.S (Janssen/Johnson & Johnson) vaccine.

## 2. Clinical Case

20 years old male patient, who resides in Tijuana city - Mexico. History of Ad26.COVID2.S (Janssen/Johnson & Johnson) vaccine eleven days prior to the beginning of the clinical manifestations, without any other related known risk factors.

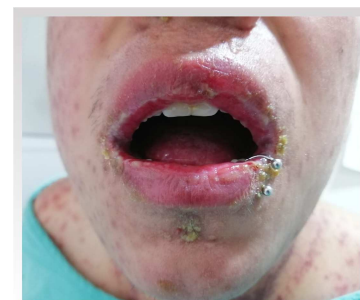He was seen in the Emergency department on July 2021 presenting generalized dermic lesions with predominance in trunk, face, hands and feet sparing palms and soles. Characterized by multiple different sizes violaceous papular lesions, some confluent into vesicles and blisters and a fine scale exfoliate. Overlaying some purpuric and petechial lesions, also some myeliceric scab and comedon. (*Figure 1*)

Erythematous and dry nasal mucosa with myeliceric scabs. Oral mucous with multiple vesicles and myeliceric scabs on lips. Also hemorrhagic ulcers and pseudomembrane formation in tongue and cheek, erythematous and edematous oropharynx (*Figure 2*). Bilateral Conjunctival mucosa presents bulbar conjunctivitis, purulent secretion, bilateral tearing, palpebral edema with overlying purpuric lesions and intense ocular pain. (*Figure 3*).

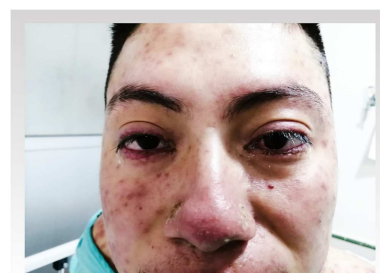


**Figure 1.** Purpuric and petechial lesions.

Clinical Features starts five days prior his hospitalization with the presence of erythema, tearing, pruritus and foreign body sensation on both eyes. 24 hours after, he starts with asthenia, adinamia, odynophagia, sialorrhea, and solid dysphagia, febricula at 37.5C also with generalize, non pruritic and painless d dermic lesions with incipient gradual distribution at upper limbs and palms progressing to trunk, face and finally lower limbs and soles.



**Figure 2.** Hemorrhagic ulcers and pseudomembrane formation in tongue and cheek.



**Figure 3.** Bulbar conjunctivitis, purulent secretion.

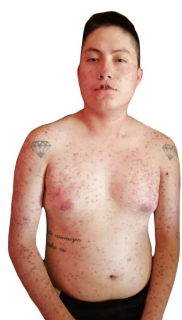The skin biopsy reported stratum corneum with net orthokeratosis, stratum granulosum two layers: stratum spinosum with irregular acanthosis and acantholysis areas. Numerous apoptotic keratinocytes, fibrin deposit areas with microabscess with intraepithelial polymorphonuclear cells. Vacuolated and pigmented stratum basale. Dermoeepidermic union with subepidermic ampules with moderate polymorphonuclear cells infiltrate, dermal papilla with loss of pigment, superficial dermis with lymphocytic infiltrate on

blood vessels, media and deep dermis with edema, congestion and fibrosis.

He had extensive clinical workup for differential diagnosis, obtaining negative results for HIV, syphilis and viral hepatitis.

At arrival at the emergency room he got a dermatologic consult who started treatment with methylprednisolone 1gr intravenously, Aciclovir 200mg orally and topical fluocinolone. Also an ophthalmologic consult who diagnose follicular conjunctivitis of viral etiology starting treatment with prednisone 50mg ophthalmic solution and fluoroquinolone in ophthalmic solution.

He is admitted to internal medicine floor for a day, deciding out-patient management by dermatology with definitive treatment: clindamycin 300mg orally, colloid water, polividone 20mg, hydrocortisone 1mg topical and hidroxycine 10mg orally. Five days after his hospital discharge, at dermatology external consultation he's found with overall improvement and fewer dermic lesions. (*Figure 4*).



*Figure 4. Five days after his hospital discharge.*

### 3. Discussion

Since COVID-19 vaccination is spreading, there have been numerous reports of adverse reactions to the vaccine. The fear of the vaccine in the population is not justified, since many supposed reactions to the vaccine are in fact not due to it [8].

There are several side effects associated with vaccines, many of them are dermic. Some of this reactions are mostly inflammation and irritation in the injection site, many others are related to the effect of the attenuated live virus. In rare occasions, vaccines have been related with generalized hypersensitivity like erythema multiforme, Stevens-Johnson syndrome, urticaria (hives), acute generalized exanthematic pustulosis and drugs hypersensitivity syndrome [9].

A study on skin reactions to the COVID-19 vaccine in Primary Dermatology Care patients reported out of 200 vaccinated patients admitted, 21 (10.5%) referred cutaneous reactions with onset after vaccination. Only one patient required hospitalization for generalized bullous erythema multiforme, which occurred 48 h after the second vaccine dose.

The other patients' cutaneous reactions to vaccination were of mild/moderate degree. Three patients presented exacerbation of their cutaneous diseases [10].

We found an extensive investigation focused on multiform

erythema, Stevens-Johnson and toxic epidermal necrolysis associated to vaccines in an 18 year period from 1999 to 2017 in the United States. They found that of 466,027 vaccine associated side effects, 89 were Stevens-Johnson syndrome [11].

In our study search for studies on new vaccines against COVID 19 adverse effects with special focus on mucocutaneous affections, we found a report that exposed a clinical case of a 74 year old male patient with a severe dermic reaction, characterized by erythematous layers extending 50% body surface [12].

Of note, it must be considered that the presence of a rash may also represent an immune response to spike protein, as similar morbilliform eruptions that are negative for viral particles have been observed in patients with primary COVID-19 infection [13].

Also, Pityriasis rosea (PR) (-like) eruptions have been described after COVID-19 vaccination. Of note, PR eruptions have been already described following other types of vaccinations, such as influenza vaccination with detection of human herpes virus (HHV)-6 and/or HHV-7 7 in skin biopsies [14].

In another article we found a case of a 65 year old male patient with small vessel cutaneous vasculitis diagnosis, both reports mention a history of Ad26.COV2.S vaccine [15].

### 4. Conclusion

At this time we didn't find a case where they reported Stevens-Johnson syndrome associated to Ad26.COV2.S vaccine. Regarding our patient, considering the clinical manifestations, the histopathological findings and the lack of other risk factors or relevant history besides the use of Ad26.COV2.S vaccine against COVID-19, we consider that, although it's a rare entity and we need more studies that evaluate the adverse effects of the new anti COVID-19 vaccines, there's a direct association between the Ad26.COV2.S vaccine and Stevens-Johnson syndrome.

### References

- [1] Charlton OA, Harris V, Phan K, et al. Toxic Epidermal Necrolysis and Steven-Johnson Syndrome: A Comprehensive Review. *Adv Wound Care (New Rochelle)*. 2020; 9 (7): 426-439. doi: 10.1089/wound.2019.0977.
- [2] Lavery MJ, Nawimana S, Parslew R, Stewart L. A flare of pre-existing erythema multiforme following BNT162b2 (Pfizer-BioNTech) COVID-19 vaccine. *Clin Exp Dermatol*. 2021; 46: 1325-1327. doi: 10.1111/ced.14714.
- [3] Salazar Mayorga et al. Stevens-Johnson Syndrome and Toxic Epidermal Necrolysis, a diagnostic and therapeutic. *Synergy Medical Journal*. Vol. 5. Num. 1. January 2020, e308.
- [4] Kim MA, Lee YW, Kim SR, et al. COVID-19 vaccine-associated anaphylaxis and allergic reactions: consensus statements of the KAAACI Urticaria/Angioedema/ Anaphylaxis Working Group. *Allergy Asthma Immunol Res*. 2021; 13: 526-544. doi: 10.4168/air.2021.13.4.526.

- [5] Lerch M, Mainetti C, Terziroli Beretta-Piccoli B, et al. Current Perspectives on Stevens-Johnson Syndrome and Toxic Epidermal Necrolysis. *Clin Rev Allergy Immunol*. 2018; 54 (1): 147-176. doi: 10.1007/s12016-017-8654-z.
- [6] CDC COVID 19 Response Team. Food and Drug Administration. Allergic reactions including anaphylaxis after receipt of the first dose of Pfizer - BioNTech COVID-19 vaccine United States, December 14-23, 2020. *MM WR Morb Mortal Wkly. Rep*. 2021; 70: 4651. doi: 10.15585/mmwr.mm7002e12. doi: 10.4168/aair.2021.13.4.526.
- [7] Baden LR, El Sahly HM, Essink B, et al. Efficacy and safety of the mRNA-1273 SARS-CoV-2 vaccine. *N Engl J Med*. 2021; 384: 403-416. doi: 10.1056/NEJMoa2035389.
- [8] Kounis NG, Koniari I, de Gregorio C, et al. Allergic reactions to current available COVID-19 vaccinations: pathophysiology, causality, and therapeutic considerations. *Vaccines (Basel)*. 2021; 9: 221. doi: 10.3390/vaccines9030221.
- [9] Frantz, R.; Huang, S.; Are, A.; Motaparthi, K. Stevens-Johnson Syndrome and Toxic Epidermal Necrolysis: A Review of Diagnosis and Management. *Medicina* 2021, 57, 895. <https://doi.org/10.3390/medicina57090895>.
- [10] Burlando M, Herzum A, Micalizzi C, Cozzani E, Parodi A. Cutaneous reactions to COVID-19 vaccine at the Dermatology Primary Care. *Immun Inflamm Dis*. 2021; 1-7. doi: 10.1002/iid3.568.
- [11] Su JR, Haber P, Ng CS, et al. Erythema multiforme, Stevens Johnson syndrome, and toxic epidermal necrolysis reported after vaccination, 1999-2017. *Vaccine*. 2020; 38 (7): 1746-1752. doi: 10.1016/j.vaccine.2019.12.028.
- [12] Lospinoso K, Nichols CS, Malachowski SJ, Mochel MC, Nutan F. A case of severe cutaneous adverse reaction following administration of the Janssen Ad26.COV2.S COVID-19 vaccine. *JAAD Case Rep*. 2021; 13: 134-137. doi: 10.1016/j.jdc.2021.05.010.
- [13] Ghimire K, Adhikari N. Morbilliform rashes in a patient with COVID-19 infection: a case report. *JNMA J Nepal Med Assoc*. 2021; 59: 399-401. doi: 10.31729/jnma.5128.
- [14] Cyrenne BM, Al-Mohammed F, DeKoven JG, Alhusayen R. Pityriasis rosea-like eruptions following vaccination with BNT162b2 mRNA COVID-19 Vaccine. *J Eur Acad Dermatol Venereol*. 2021; 13: 546. doi: 10.1111/jdv.17342 20.D.
- [15] Berry CT, Eliliwi M, Gallagher S, et al. Cutaneous small vessel vasculitis following single-dose Janssen Ad26.COV2.S vaccination. *JAAD Case Rep*. 2021; 15: 11-14. doi: 10.1016/j.jdc.2021.07.002.