



The Mechanics of Apical Rotation in Patients with Myocardial Infarction and Reduced Left Ventricular Function

Mohamed Roshdy, Ramy Omar

Department of Cardiology, National Heart Institute, Cairo, Egypt

Email address:

Ramymomar84@gmail.com (R. Omar)

To cite this article:

Mohamed Roshdy, Ramy Omar. The Mechanics of Apical Rotation in Patients with Myocardial Infarction and Reduced Left Ventricular Function. *International Journal of Cardiovascular and Thoracic Surgery*. Vol. 7, No. 6, 2021, pp. 64-69. doi: 10.11648/j.ijcts.20210706.12

Received: December 31, 2020; **Accepted:** April 1, 2021; **Published:** November 23, 2021

Abstract: Background: Traditionally the use of Left ventricular ejection fraction (LVEF) for assessment of left ventricular (LV) systolic function is the most widely used method. However, this method is inaccurate after acute MI, this attributed to the development of wall-motion abnormalities after acute MI; In addition, the biplane Simpson method calculation is inaccurate, because it relies on geometric assumptions. Recently, the use of two-dimensional speckle-tracking imaging has facilitated noninvasive measurement of LV torsion. Objective: The aim of this study was to use speckle-tracking echocardiography to assess apical rotation in patients with anterior and inferior myocardial infarction (MI). Patients and methods: The present study enrolled 54 patients with anterior or inferior MI, in addition to 20 healthy volunteers (matched for age and sex) as the control group. Using commercially available two-dimensional strain software, apical, basal rotation, and LV torsion were calculated. Basal and apical LV short-axis images were acquired for further off-line analysis. Results: Apical rotation was significantly reduced in the patient group compared with the control group ($P < 0.001$). Consequently, torsion degree ($P < 0.001$), torsion rate, and untwisting rate ($P = 0.007$) were significantly reduced. There was a significant correlation between ejection fraction and apex rotation ($r = 0.466$, $P = 0.044$), torsion degree ($r = 0.499$, $P = 0.03$), and untwisting rate ($r = -0.543$, $P < 0.001$). Correlation with basal rotation was nonsignificant, and thus measurement of apical rotation alone (rather than calculation of LV torsion) might provide a simple and accurate alternative for assessment of LV contractility. Conclusion: Apical rotation and torsion were decreased in ST-elevation MI, and this was statistically significant in patients with LV dysfunction.

Keywords: Apical Rotations, Ejection Fraction, Myocardial Infarction, Speckle-Tracking Echocardiography, Torsion

1. Introduction

The complex architecture of left ventricular (LV) myocardial fibers is a vital contributor to normal LV performance [1]. Contraction of obliquely oriented myocardial fibers leads to a systolic wringing motion of the LV as a result of the opposing rotation of the apex and the base. Myocardial fiber orientation in the LV wall changes from a left-handed helix in the subepicardium to a right-handed helix in the subendocardium [2–5]. Contraction of these obliquely oriented fibers creates a wringing or twisting motion of the LV.

Speckle tracking is a simple echocardiographic method for assessing LV strain, rotation, and twist. Speckle-tracking

echocardiography (STE) is an angle-independent technique that allows an accurate assessment of segmental myocardial deformation.

The lack of angle dependency is of great advantage because myocardial strain (Σ) could be tracked in two-dimensional echo imaging along the direction of the wall instead of along the ultrasound beam [6]. Torsion can be measured by rotation data in basal and apical short-axis views.

Myocardial infarction (MI) is accompanied with regional wall-motion abnormalities in the LV apex, because LV torsion is predominantly generated from apical rotation so that LV torsion might be depressed. The LV untwisting

begins before aortic valve closure and before longitudinal and radial expansion [7]. Because it is one of the earliest events leading to LV filling, untwisting might be a critical determinant of early diastolic function. The quantification of LV untwisting might provide novel insights into diastolic function [8, 9].

2. Objective

The aim of the work was to assess apical rotation in acute ST-elevation MI.

3. Patients and Methods

The present study included 74 individuals who were divided into two groups:

(1) Group I (the patient group): This group included 54 MI patients, including 19 patients with LV dysfunction [ejection fraction (EF) < 50%] and 35 patients with normal LV function. Thirty-eight patients had anterior MI and 16 patients had inferior MI.

(2) Group II: This group included 20 healthy age- matched and sex-matched volunteers apparently free from cardiovascular risk factors.

Inclusion criteria included an incidence of first acute myocardial infarction (AMI), with or without LV dysfunction. All patients were treated with thrombolysis (except three patients, in whom no reperfusion therapy was carried out).

Exclusion criteria included incidences of significant valvular disease, pericardial diseases, congenital heart disease, or advanced renal or hepatic disease, and previous coronary artery bypass graft or percutaneous coronary intervention.

Participants in the study were subjected to full history taking, thorough clinical examination, 12-lead ECG, two-dimensional echocardiography, M-mode, and Doppler examination.

Apical rotation, basal rotation, torsion degree, torsion rate, and untwisting rate were calculated (Figures 1 and 2).

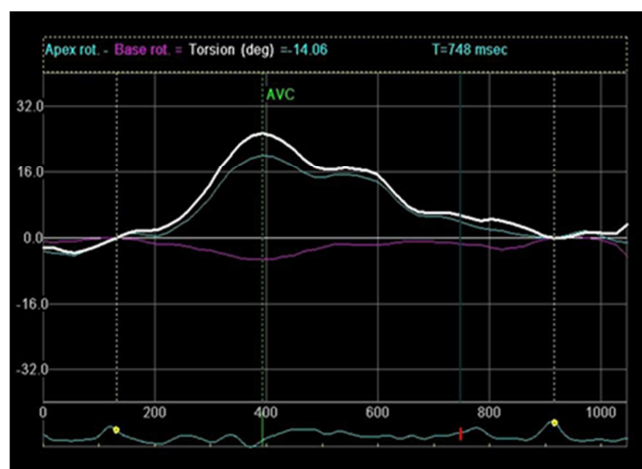


Figure 1. Torsion degree in a myocardial infarction patient (patient 34) showing reduction in apical rotation and torsion degree.

LV rotation and torsion were assessed by acquisition of

specific short-axis planes with internal landmarks: the basal plane was acquired at the level of the mitral valve leaflets while excluding the mitral annulus, and the apical plane was acquired distally to the papillary muscles [10]. Every effort was made to make the LV cross-section as circular as possible. The frame rate range was 65–80/s. In each phase, the cine loop images of three consecutive cardiac cycles were stored for off-line analysis with a dedicated platform EchoPac PC (EchoPac PC, version 1.8.1. X; GE Healthcare, Chicago, United States).

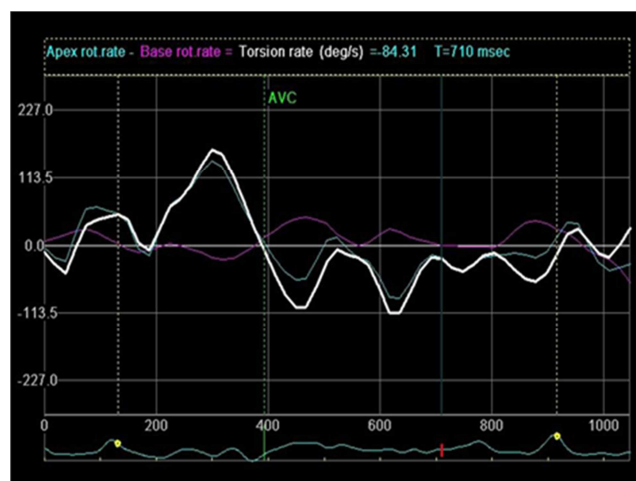


Figure 2. Torsion rate and untwisting rate in a myocardial infarction patient (patient 34) showing decrease in untwisting rate.

3.1. Statistical Analysis

Data were collected, tabulated, and statistically analyzed with an IBM compatible personal computer with SPSS statistical package (version 17; SPSS Inc., Chicago, IL, USA).

3.2. Descriptive Statistics

This included percentage, mean (X), and SD.

3.3. Analytical Statistics

These were ascertained using the X^2 -test, Student's t-test, and analysis of variance (F), with a level of significance as follows: P-values less than 0.05 were considered significant, P-values less than 0.001 were considered highly significant, and P-values greater than 0.05 were considered nonsignificant [11].

3.4. Ethical Consideration

Consent was obtained from every patient after explanation of the procedure. Medical research and ethics committee approved the study.

4. Results

Regarding age and sex, there were no significant differences between the studied groups (Table 1).

Table 1. Distribution of demographic data.

The variables	Groups				Test	P-value
	patient		control		t/ χ^2	
Age (years)						
Range	32	80	25	75	1.707	0.092
Mean ± SD	59.333	10.409	54.8	9.34		
Sex						
Male	45	83.33	17	85	0.03	0.862
Female	9	16.67	3	15		
Weight (kg)						
Range	55	100	60	76	6.159	<0.001*
Mean ± SD	81.944	8.807	69.1	4.919		

Table 2. Comparison between the study groups by conventional echocardiography.

The variables	Groups				Test	
	patient		control		t/X ²	P-value
Range	2.000	4.000	2.000	3.800	1.344	0.183
Mean ± SD	2.963	0.457	2.795	0.532		
LA (cm)						
Range	2.300	4.700	2.500	3.800	3.270	0.002*
Mean ± SD	3.669	0.530	3.255	0.319		
LVIDs (cm)						
Range	2.100	6.800	2.400	3.700	2.652	0.010*
Mean ± SD	3.844	0.900	3.295	0.341		
LVIDd (cm)						
Range	3.200	8.100	4.300	5.600	1.533	0.130
Mean ± SD	5.381	0.845	5.080	0.381		
EDV (ml)						
Range	45.000	351.000	82.000	153.000	1.805	0.075
Mean ± SD	145.389	50.568	124.250	21.359		
ESV (ml)						
Range	15.000	241.000	20.000	60.000	2.668	0.009*
Mean ± SD	68.574	38.093	45.400	11.133		
IVSd (cm)						
Range	0.700	2.600	0.900	2.200	0.951	0.345
Mean ± SD	1.404	0.416	1.305	0.335		
IVSd (cm)						
Range	0.500	2.100	0.500	1.100	2.502	0.015*
Mean ± SD	0.980	0.290	0.805	0.188		
FS%						
Range	15.000	44.000	28.000	45.000		
Mean ± SD	28.926	6.818	34.850	5.050	−3.537	0.001*
EF%						
Range	31.000	73.000	55.000	76.000		
Mean ± SD	54.426	10.421	64.500	6.794	−4.010	<0.001*
E (m/s)						
Range	0.380	1.040	0.370	1.100	−3.266	0.002*
Mean ± SD	0.663	0.154	0.803	0.184		
A (m/s)						
Range	0.250	1.100	0.390	0.880	1.133	0.261
Mean ± SD	0.657	0.172	0.608	0.145		
E/A Range	0.470	3.230	0.650	2.060	−2.144	0.035*

AO, aorta; EDV, end-diastolic volume; EF%, ejection fraction; ESV, end-systolic volume; FS%, fractional shortening; IVSd, interventricular septum dimension in diastole; IVSs, interventricular septum dimension in systole; LA, left atrium; LVIDd, left ventricular end-diastolic dimension in diastole; LVIDs, left ventricular end-systolic dimension; peak A, late ventricular filling wave velocity; peak E, early rapid ventricular filling wave velocity; P>0.05, insignificant; P<0.05, significant; P<0.001, highly significant.

Table 3. Comparison between patients and controls as regards rotation and rotation rate.

The variables	Groups				Test	P-value
	patient		control		t/X ²	
Apex rotation (deg.)						
Range	0.340	15.980	2.580	16.700	−4.448	<0.001 *
Mean ± SD	6.128	4.059	12.981	6.236		
Basal rotation (deg.)						

The variables	Groups				Test	P-value
	patient		control			
Range	-15.130	4.470	-11.720	2.060	1.048	0.298
Mean \pm SD	-3.106	3.952	-4.158	3.483		
Torsion degree (deg./mm)					-4.291	<0.001*
Range	0.530	19.250	4.800	14.720		
Mean \pm SD	9.360	4.977	17.134	7.605	-2.758	0.007*
Torsion rate (deg./s)						
Range	17.470	167.00	44.690	146.000	2.412	0.007*
Mean \pm SD	76.007	32.108	98.609	28.967		
Untwisting rate (deg./s)					2.412	0.007*
Range	-150.000	-27.340	-128.910	-66.090		
Mean \pm SD	587	30.465	-99.972	22.435		

P>0.05, insignificant; P<0.05, significant; P<0.001, highly significant

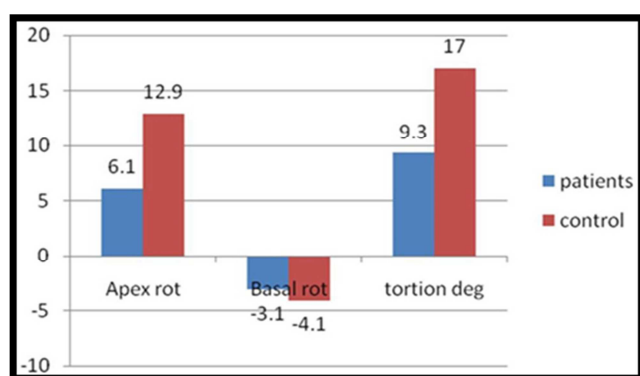


Figure 3. Comparison between study groups regarding apex rotation, basal rotation, and torsion degree.

Regarding conventional echocardiographic parameters, there were significant differences between group I (patients) and group II (control) as regards EF (P<0.001), fractional shortening, left atrium dimension, left ventricular end-

systolic dimension, interventricular septum dimension in diastole, end-systolic volume, peak E velocity, and E/A ratio (P<0.05) (Table 2).

Apical rotation was significantly reduced in the patient group compared with the control group (P<0.001). Consequently, torsion degree (P<0.001), torsion rate, and untwisting rate (P=0.007) are significantly changed (Figure 3 and Table 3).

No difference was found between anterior and inferior MI as regards torsion (P=0.870) (Table 4).

In patients with LV dysfunction, significant correlation was found between EF and apex rotation (r=0.466, P=0.044), torsion degree (r=0.499, P=0.03), and untwisting rate (r=-0.543, P<0.001).

Correlation of EF with basal rotation was nonsignificant, and thus measurement of apical rotation alone (rather than calculation of LV torsion) might provide a simple and accurate alternative for assessment of LV contractility (Table 5).

Table 4. Comparison between anterior and inferior myocardial infarction.

The variables	Anterior MI	Inferior MI	T-test	P-value
FS%	29.16 \pm 7.18	28.38 \pm 6.05	0.38	0.70
EF%	54.76 \pm 10.93	53.63 \pm 9.39	0.36	0.72
E wave (m/s)	0.67 \pm 0.17	0.66 \pm 0.12	0.22	0.83
A wave (m/s)	0.66 \pm 0.16	0.66 \pm 0.21	0.02	0.99
E/A	1.08 \pm 0.41	1.15 \pm 0.69	0.51	0.61
Average global longitudinal strain (%)	11.5 \pm 3.37	12.93 \pm 4.76	1.26	0.21
Basal rotation (deg.)	-3.35 \pm 3.85	-2.53 \pm 4.26	0.7	0.49
Apical rotation (deg.)	5.84 \pm 4.26	6.81 \pm 3.57	0.80	0.43
Torsion degree (deg./mm)	9.29 \pm 4.99	9.53 \pm 4.09	0.16	0.87
Torsion rate (deg./s)	76.56 \pm 34.21	74.70 \pm 27.45	0.19	0.85
Untwisting rate (deg./s)	-74.81 \pm 29.74	-74.06 \pm 33.11	0.08	0.94

EF%, ejection fraction; FS%, fractional shortening; MI, myocardial infarction; peak E, early rapid ventricular filling wave velocity, peak A, late ventricular filling wave velocity; P>0.05, insignificant; P<0.05, significant; P<0.001, highly significant.

Table 5. Correlation between ejection fraction and fractional shortening and rotation in patients with ejection fraction less than 50%.

Patients (N=19)	EF		FS	
	R	P-value	R	P-value
Apex rotation (deg.)	0.466	0.044*	0.434	0.063
Basal rotation (deg.)	-0.202	0.407	-0.266	0.271
Torsion degree (deg./mm)	0.499	0.030*	0.517	0.023*
Torsion rate (deg./s)	0.197	0.420	0.266	0.272
Untwisting rate (deg./s)	-0.564	0.012*	-0.478	0.038*

EF, ejection fraction; FS, fractional shortening; P>0.05, insignificant; P<0.05, significant; P<0.001, highly significant.

5. Discussion

We studied apical rotation measured using non- Doppler two-dimensional speckle tracking in 54 MI patients, and in the age-matched and sex-matched control group (20 individuals).

The present study showed reduction in apical rotation in MI. Apical rotation was not only significantly lower in AMI compared with controls (6.128 ± 4.059 vs. 12.981 ± 6.236 , $P < 0.001$), but it was also lower in individuals with left ventricular ejection fraction (LVEF) less than 50% (5.889 ± 3.707), compared with those who had LVEF more than 50% (6.368 ± 4.442 , $P = 0.668$).

These results are similar to previous studies that used an optical device and tagged MRI to quantify apical motion [5, 12, 13]. LV systolic dysfunction in patients with MI was mainly attributed to transmural infarction resulting in severe reduction of circumferential strain in the apex. These severe impairments of apical strain cannot generate sufficient apical rotational movement, which is the main determinant of LV systolic twist.

Reduction of torsion and apical rotation were more marked in patients with LV dysfunction than in patients with EF more than 50%. This is a result of the mild reduction of circumferential strain in the apex that may affect LV twist behavior in a mild manner in patients with EF more than 50%. Normal LV systolic function associated with MI is usually the result of a small subendocardial infarction with preserved epicardial function. Thus, another possibility is that these counteracting forces, generated by the subendocardial layer against the subepicardial layer, decrease in the setting of subendocardial dysfunction, resulting in sufficient subepicardial fiber torque to drive torsional deformation toward positive angles.

LVEF is currently the most widely used index of LV systolic function. However, it should be noted that the development of wall-motion abnormalities after AMI significantly decreases the accuracy of LVEF.

Thus, LV apical rotation could provide a more accurate measurement of LV performance compared with LVEF. These observations suggest that apical rotation can serve as a marker of LV contractility and that its measurement using STE alone provides a noninvasive assessment of global LV function. If so, this technique is promising for use in routine clinical practice.

Apical rotation is highly sensitive to ischemia and becomes abnormal within a few seconds after coronary ligation or balloon occlusion [14]. This was further confirmed by Nagel et al. [15], who investigated cardiac rotation in patients with anterolateral MI. In these patients, there was less systolic rotation at the apex in comparison with controls. The same was reported recently by Takeuchi et al. [16], who used STE for LV torsion analysis in patients with anterior MI.

The present study showed reduction in torsion degree in MI. This abnormality can be predominantly attributed to reduced apical rotation. Peak systolic torsion was not only

significantly lower in AMI compared with controls ($P < 0.001$), but it was also lower in individuals with LVEF less than 50% compared with those who had LVEF more than 50%. This relationship between torsion and low EF in those with prior MI was confirmed by Govind et al. [17]. Peak systolic torsion was not only significantly lower in AMI compared with controls ($P < 0.01$), but it was also lower in individuals with LVEF less than 40% compared with those who had LVEF more than 40% ($P < 0.02$).

The present study showed that torsion had a significantly positive linear relation ($r = 0.499$, $P = 0.30$) with LVEF in individuals with LVEF less than 50%.

Garot et al. [18] investigated systolic twist angles in patients after acute anterior MI, and in a control group. Myocardial ischemia caused a decrease in LV twist angles in patients with respect to controls, which was related to global LV function. The same was observed by Buchalter et al. [12].

This was in agreement with the results of Nucifora et al. [19], who studied a total of 120 patients with a first ST-segment elevation AMI. Compared with control individuals, the peak LV torsion in AMI patients was significantly impaired.

The present study showed that apical and basal rotation responded differently to AMI. Apical rotation showed clear changes, whereas basal rotation exhibited no significant alterations. LVEF was correlated significantly with apical rotational parameters, whereas correlations with basal parameters were nonsignificant. Because assessment of rotation by STE is less accurate for the basal level than for the apical level, measurement of apical rotation alone (rather than calculation of LV torsion) might provide a simple and accurate alternative for assessment of LV contractility. These results agree with those of previous studies [13, 20] and with the study by Toumanidis et al. [10] (LV apical rotation: $3.68 \pm 1.73^\circ$ pre-AMI vs. $2.19 \pm 1.64^\circ$ post-AMI, $P < 0.009$).

The LV global torsion decreased significantly. Strain and rotational changes of the LV apex were primarily correlated with EF, but those of the LV base were not. EF had a significant correlation with the global LV twist ($r = 0.31$, $P < 0.05$).

In the present study there was no difference between anterior and inferior MI as regards torsion ($P = 0.87$). In the study by Bansal et al. [21] there was no difference in global LV systolic torsion in patients with anteroapical or inferoposterior infarcts (1.81 ± 1.13 vs. $2.27 \pm 1.18^\circ/\text{cm}$, $P = \text{NS}$), and no differences in regional torsion.

Torsion was most impaired in patients with multiple areas of infarction ($1.03 \pm 0.89^\circ/\text{cm}$, $P < 0.01$). Apical rotation is mostly decreased after large anterior MI [22]. The present study did not assess the size of infarction and this explains why there was no difference between anterior and inferior MI as regards apical rotation ($P = 0.426$).

6. Conclusion

Apical rotation and torsion were decreased and diastolic untwisting was depressed in ST-elevation MI, and this was statistically significant in patients with LV dysfunction.

Limitations

The major limitations of the present study are that it was based on a single-center experience and may be limited by the small number of patients.

Conflicts of Interest

There are no conflicts of interest.

References

- [1] Luo Y, Liu Y, Guan X, Zhang Y, Li J. Value of three dimensional-speckle tracking imaging for predicting left ventricular function after non-ST-segment elevation myocardial infarction with percutaneous coronary intervention. *J Xray Sci Technol* 2018; 26: 331–9.
- [2] Bastawy I, Ismail M, Hanna HF, El Kilany W. Speckle tracking imaging as a predictor of left ventricular remodeling 6 months after first anterior ST elevation myocardial infarction in patients managed by primary percutaneous coronary intervention. *Egypt Heart J* 2018; 70: 343–52.
- [3] Ingels NB Jr, Hansen DE, Daughters GT II, Stinson EB, Alderman EL, Miller DC. Relation between longitudinal, circumferential, and oblique shortening and torsional deformation in the left ventricle of the transplanted human heart. *Circ Res* 1989; 64: 915–927.
- [4] Moon MR, Ingels NB Jr, Daughters GT II, Stinson EB, Hansen DE, Miller DC. Alterations in left ventricular twist mechanics with inotropic stimulation and volume loading in human subjects. *Circulation* 1994; 89: 142–150.
- [5] Kroeker CA, Tyberg JV, Beyar R. Effects of ischemia on left ventricular apex rotation. An experimental study in anesthetized dogs. *Circulation* 1995; 92: 3539–3548.
- [6] Monaster SS, Ahmad MK, Braik AG. Comparison between strain and strain rate in hypertensive patients with and without left ventricular hypertrophy: a speckle-tracking study. *Menoufia Med J* 2014; 27: 322–328.
- [7] Haberka M, Liszka J, Kozyra A, Finik M, Gąsior Z. Two-Dimensional Speckle Tracking Echocardiography Prognostic Parameters in Patients after Acute Myocardial Infarction. *Echocardiography* 2015; 32: 54–60.
- [8] Lester SJ, Tajik AJ, Nishimura RA, Oh JK, Khandheria BK, Seward JB. Unlocking the mysteries of diastolic function: deciphering the Rosetta Stone 10 years later. *J Am Coll Cardiol* 2008; 51: 679–689.
- [9] Sengupta PP, Tajik AJ, Chandrasekaran K, Khandheria BK. Twist mechanics of the left ventricle: principles and application. *JACC Cardiovasc Imaging* 2008; 1: 366–376.
- [10] Toumanidis ST, Kaladaridou A, Bramos D, Skaltsiotis E, Agrios JN, Vasiladiotis N, et al. Apical rotation as an early indicator of left ventricular systolic dysfunction in acute anterior myocardial infarction: experimental study. *Hellenic J Cardiol* 2013; 54: 264–272.
- [11] Armitage P, Berry G, Matthews JNS. Statistical methods in medical research. 4th ed. Wiley-Blackwell, Chicago, USA: Blackwell Scientific Publication; 2002.
- [12] Buchalter MB, Weiss JL, Rogers WJ, Zerhouni EA, Weisfeldt ML, Beyar R, Shapiro EP. Noninvasive quantification of left ventricular rotational deformation in normal humans using magnetic resonance imaging myocardial tagging. *Circulation* 1990; 81: 1236–1244.
- [13] Nagel E, Stuber M, Lakatos M, Scheidegger MB, Boesiger P, Hess OM. Cardiac rotation and relaxation after anterolateral myocardial infarction. *Coron Artery Dis* 2000; 11: 261–267.
- [14] Kim J, Weinsaft JW. Thrombosis and prognosis following ST-Elevation myocardial infarction: Left ventricular thrombus assessment by cardiac magnetic resonance. *Circ Cardiovasc Imaging* 2015; 8: e004098.
- [15] Nagel E, Stuber M, Burkhard B, Fischer SE, Scheidegger MB, Boesiger P, Hess OM. Cardiac rotation and relaxation in patients with aortic valve stenosis. *Eur Heart J* 2000; 21: 582–589.
- [16] Takeuchi M, Nishikage T, Nakai H, Kokumai M, Otani S, Lang RM. The assessment of left ventricular twist in anterior wall myocardial infarction using two-dimensional speckle tracking imaging. *J Am Soc Echocardiogr* 2007; 20: 36–44.
- [17] Govind SC, Gadiyaram VK, Quintana M, Ramesh SS, Saha S. Study of left ventricular rotation and torsion in the acute phase of ST- elevation myocardial infarction by speckle tracking echocardiography. *Echocardiography* 2010; 27: 45–49.
- [18] Garot J, Pascal O, Diébold B, Derumeaux G, Gerber BL, Dubois- Randé JL, et al. Alterations of systolic left ventricular twist after acute myocardial infarction. *Am J Physiol Heart Circ Physiol* 2002; 282: H357–H362.
- [19] Nucifora G, Marsan NA, Bertini M, Delgado V, Siebelink HM, van Werkhoven JM, et al. Reduced left ventricular torsion early after myocardial infarction is related to left ventricular remodeling. *Circ Cardiovasc Imaging* 2010; 3: 433–442.
- [20] Helle-Valle T, Crosby J, Edvardsen T, Lyseggen E, Amundsen BH, Smith HJ, et al. New noninvasive method for assessment of left ventricular rotation: speckle tracking echocardiography. *Circulation* 2005; 112: 3149–3156.
- [21] Bansal M, Leano RL, Marwick TH. Clinical assessment of left ventricular systolic torsion: effects of myocardial infarction and ischemia. *J Am Soc Echocardiogr* 2008; 21: 887–894.
- [22] Blasen C, Codreanu A, Robert F, Meniconi N, Beissel J, Wagner DR. Measurement of ventricular twist by 2D speckle tracking early after acute myocardial infarction. Comparison between anterior and inferior infarction. *Bull Soc Sci Med Grand Duche Luxemb* 2009; 2: 115–129.