



Case Report

Obstructive Thrombosis of a Mitral Prosthetic Valve in the Context of COVID-19 in Senegal

Ba Papa Ousmane^{1,2}, Diagne Papa Amath^{1,2}, Diop Momar Sokhna^{1,2},
Ismael Ibouroi Moina-Hanifa², Ikponmwosa Gold^{1,2}, Dioum Momar^{1,2}, Ba El Hadj Boubacar^{1,2},
Bizrane Myriam¹, Ba Papa Salmane^{1,2}, Ciss Amadou Gabriel^{1,2}

¹Department of Thoracic and Cardio-Vascular Surgery, Fann Hospital, Dakar, Senegal

²Cuomo Cardio-Pediatric Center in Fann Hospital, Dakar, Senegal

Email address:

papy.ba@gmail.com (Ba Papa Ousmane), diagnepapaamath@gmail.com (Diagne Papa Amath),
momarsokhna08@yahoo.fr (Diop Momar Sokhna), ismael.hanifaa@gmail.com (Ismael Ibouroi Moina-Hanifa),
goldikponmwosa@gmail.com (Ikponmwosa Gold), momar.dioum@yahoo.fr (Dioum Momar), elhadji34@live.fr (Ba El Hadj Boubacar),
myri.biz@gmail.com (Bizrane Myriam), mansalb@yahoo.fr (Ba Papa Salmane), cissgaby@yahoo.fr (Ciss Amadou Gabriel)

To cite this article:

Ba Papa Ousmane, Diagne Papa Amath, Diop Momar Sokhna, Ismael Ibouroi Moina-Hanifa, Ikponmwosa Gold, Dioum Momar, Ba El Hadj Boubacar, Bizrane Myriam, Ba Papa Salmane, Ciss Amadou Gabriel. Obstructive Thrombosis of a Mitral Prosthetic Valve in the Context of COVID-19 in Senegal. *International Journal of Cardiovascular and Thoracic Surgery*. Vol. 9, No. 4, 2023, pp. 51-55.

doi: 10.11648/j.ijcts.20230904.12

Received: May 31, 2023; **Accepted:** July 18, 2023; **Published:** August 5, 2023

Abstract: COVID-19 causes a hypercoagulable state, predisposing to a thrombotic state, particularly in patients with mechanical valve. Thrombosis of a prosthetic valve is a rare but serious complication of valve replacement by mechanical prosthesis. It is a medical and surgical emergency. Diagnosis is based primarily on trans-thoracic echocardiography. All obstructive thromboses of the left heart require surgery. We report the case of a 30-year-old female patient with a background COVID-19 infection who presented with New York Heart Association (NYHA) class III dyspnea, chest pain and fever, a transthoracic echocardiography showed obstructive mechanical mitral valve thrombosis. She was hospitalized in the cardiology department and anticoagulant therapy was initiated. The mechanical valve was, then, removed. On H15 postoperatively she was febrile with a temperature of (40°C), the pupils were isocoric, and there was a decerebrate rigidity, however, her hemodynamic state was stable. The PCR test result for COVID-19 was positive 15 hours after the surgery, a thoracic computer tomography angiography scan revealed a mild form of COVID-19. A brain computer tomography scan revealed a COVID-19 encephalopathy. Unfortunately at H20, the infectious workup showed leucocytosis and a positive CRP, which required initiating empiric antibiotic therapy with ceftriaxone and gentamicin awaiting for microscopy, culture and sensitivity results. Treatment with methylprednisolone was also started. The dose of immediate postoperative anticoagulation was maintained at 200 IU/Kg/D. On H24 her Glasgow Coma Scale was 3/15, pupils were fixed and dilated with loss of brainstem reflexes. Death was declared at Day 2 postoperatively as a result of neurological complications. Standard prophylactic and therapeutic protocols need to be reviewed when COVID-19 occurs in a patient with a mechanical valve prosthesis.

Keywords: Mechanical Valve Thrombosis, COVID-19, Anticoagulation

1. Introduction

Rheumatic disease is still very common in sub-Saharan Africa. Mitral valve disease is the most common form of rheumatic disease [1].

Prosthetic valve thrombosis is one of the major

complications of valve replacement [2].

COVID-19 leads to a state of hypercoagulability that can potentiate the risk of thrombosis on the prosthetic valve [3].

2. Case Presentation

We report the case of a 30-year-old female patient who was hospitalized on account of New York Heart Association (NYHA) class III dyspnea, chest pain and fever. A diagnosis of an obstructive thrombosed mechanical prosthetic mitral valve on cardiac ultrasound with a background COVID-19 infection was made. Two years earlier, she had undergone mitral valve replacement with a mechanical prosthesis (CARBOMEDICS Standard N°29) due to severe rheumatic mitral insufficiency. The initial postoperative course was uneventful, and oral anticoagulant was introduced with a target INR between 2.5 and 3.5. As part of her cardiology follow-up, she regularly underwent trans-thoracic cardiac echocardiography (TTE). On 26th month postoperatively (M26), she presented with NYHA class III dyspnea associated with intense chest pain. The patient wanted to get pregnant and decided to stop the anticoagulant (acenocoumarol) without medical advice, 3 months prior to her admission (because of its teratogenic effects). She also stopped monitoring PT-INR checks.

She was hospitalized in the cardiology department and the following treatment has been introduced:

1. Anticoagulant therapy: Heparin at a dose of 400 IU/kg/day administered continuously through a syringe pump.
2. Diuretic: Lasix (furosemide) 20mg, administered intravenously three times daily.
3. Cordarone: Administered intravenously at a dose of 300mg/20ml, with a speed of 40ml/hour.
4. Milrinone: Administered at a rate of 0.8 μ g/kg/min.
5. Omeprazole: A 20mg tablet taken once daily.

Clinical examination at presentation showed a poor general condition without peripheral signs of cardiac congestion, a heart rate of 118 beats per minute, a respiratory rate of 26

cycles per minute, oxygen saturation of 98%, and a temperature of 36.5°C. Examination findings revealed a sternotomy scar, a discrete prosthetic click, a tricuspid insufficiency murmur graded at 2/6, and a loud second heart sound at the pulmonary area.

A transthoracic echocardiography (TTE) showed an initial mean transmitral gradient of 25mmHg at her admission. This increased during her hospitalization with a mean transmitral gradient of 36 mmHg and the effective valve area (EVA) estimated at 0.44cm². The parameters of transthoracic echocardiography are summarized in the table below:

Table 1. Transthoracic echocardiography.

Echocardiography data	
LV diastolic diameter (mm)	26
LV systolic diameter (mm)	17
Septal thickness (mm)	7
Posterior wall (mm)	8
LA area (cm ²)	30
RA area (cm ²)	15
LV%EF (%)	67
TAPSE (mm)	12

LV = Left ventricular; LA = Left atrium; EF = Ejection fraction
TAPSE = Tricuspid annular plan systolic excursion

Echocardiography showed reduced prosthetic mitral valve mobility with visualization of only one mechanical valve's leaflet and abnormal transprosthetic flow (as indicated by aliasing). Additionally, we found a dilated left atrium, type II septum, correct global kinetics with good ventricular systolic function, moderate alteration of the longitudinal function of the right ventricle (RV), a moderate eccentric tricuspid insufficiency with pulmonary artery systolic pressure (PASP) of 78 mmHg (figure 1).

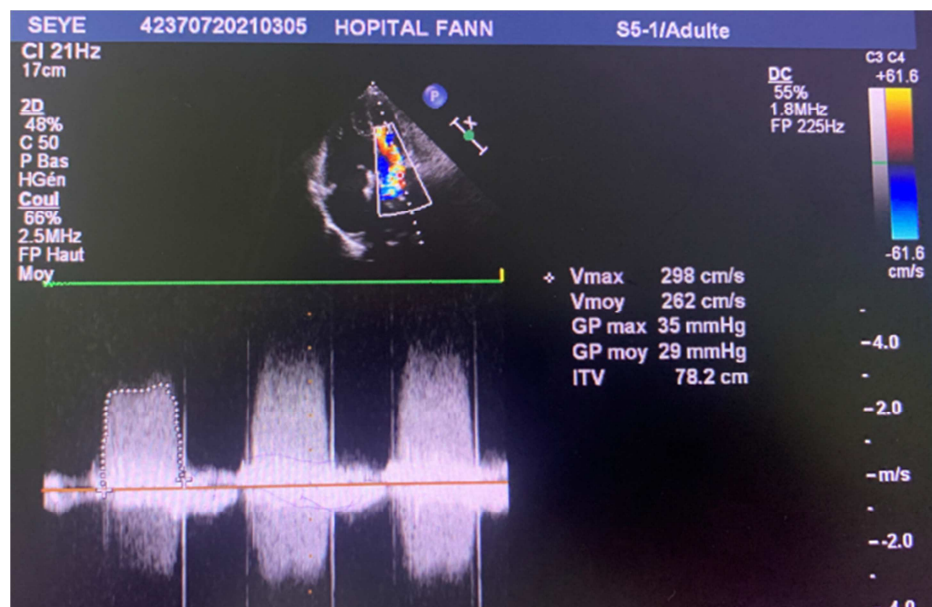


Figure 1. Preoperative Transthoracic Echocardiography.

The indication for a surgical revision was determined. The laboratory assessment including a full blood count, serum

electrolytes, urea, and creatinine and liver function tests, were all within normal ranges. The otorhinolaryngology review showed normal findings. A COVID-19 PCR test had been performed the day before her surgery. In the context of the surgical management of patients during the COVID-19 pandemic, this test was routinely performed.

Due to the deterioration of her hemodynamic condition, she was transferred to the cardiac surgery intensive care unit on day 4 of her hospitalization. The doses of vasopressors were increased and she was on continuous monitoring.

On day 5 of hospitalization, the surgery was performed under cardiopulmonary bypass (CPB) with a bicaval cannulation, antegrade Delnido cardioplegia, and mild hypothermia at 34 degrees.

The removal of the mechanical valve was done by direct approach through a left atriotomy parallel to the interatrial groove. Intraoperative findings revealed the presence of a prosthetic ring and an intra-prosthetic thrombus causing occlusion of one of the two leaflets (figure 2).

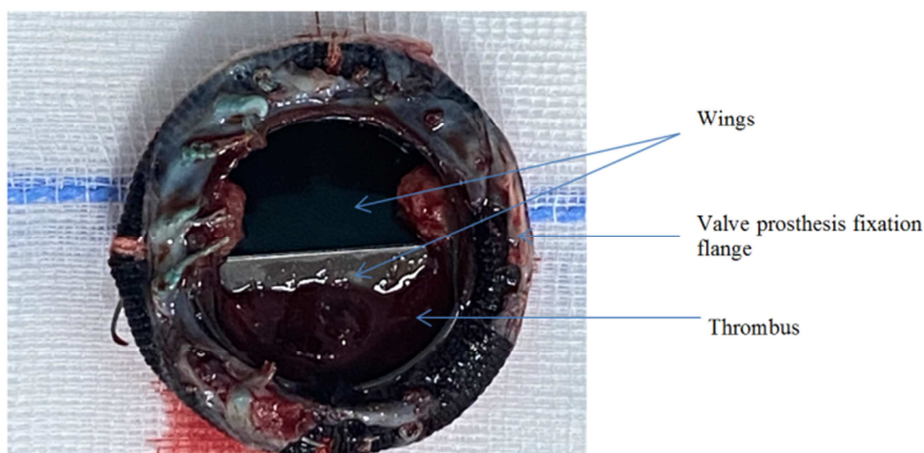


Figure 2. Thrombosed mechanical valve prosthesis after ablation.

After the surgery, she was transferred to the intensive care unit, intubated and sedated. The immediate postoperative cardiac ultrasound showed a functional non-stenotic mitral prosthesis (mean gradient: 3 mmHg). The left ventricular systolic function was good, while the right ventricular systolic function was severely impaired (TAPSE: 6 mm). There was also moderate tricuspid insufficiency with PAPS: 46mmHg.

When the sedation was stopped at H3, she had a delay in waking up and her pupils were pinpoint. At H6, unfractionated heparin was started at 200 IU/Kg/D according to our post

operative protocols.

At H15 the pupils were isocoric and she presented continuous hyperthermia at 40° C, decerebrate rigidity. Her respiratory and hemodynamic states were still stable at that time.

The PCR test results came back positive, and a chest computer tomography (CT) scan showed a ground-glass appearance in the subpleural area in favor of COVID-19 infection in its mild form. The CT scan is illustrated in figure 3.

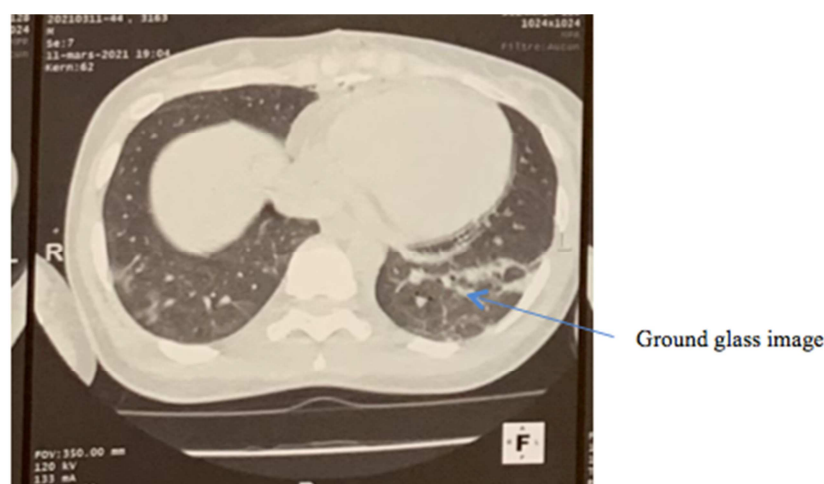


Figure 3. CT angiography.

Due to suspicion of COVID-19 encephalopathy, an emergency brain scan was performed and showed central

hernia with effacement of the perimesencephalic cisterns, elongation of cerebellar tonsils, loss of grey-white matter

differentiation suggesting a cytotoxic edema and lack of opacification of cerebral arteries (suggesting brain death).

At H20 the sepsis workup showed leucocytosis and a positive CRP, necessitating an empirical antibiotic therapy with ceftriaxone and gentamicin.

Methylprednisolone was started. The dose of immediate postoperative anticoagulation was maintained at 200 IU/Kg/D.

Her clinical condition worsened with a progressive deterioration of the respiratory and hemodynamic state. At H24 Glasgow Coma Scale was 3/15, and pupils were fixed and dilated. Death was declared at D2 as a result of neurological complications.

3. Discussion

The incidence of mechanical valve prosthesis thrombosis ranges from 0.03-4.3% per year [4]. The most commonly reported cause in the literature is suboptimal anticoagulant treatment [5]. Initially described as a respiratory disease, COVID-19 is now recognized as a systemic disease [6]. COVID-19 induces a hypercoagulable state, the underlying mechanism of which is not yet fully understood. This involves both arterial and venous systems. It appears that the hypercoagulability is attributed to direct endothelial damage caused by the virus and the inflammatory response triggered by the complement system [7]. According to some authors, this is due to the activation of pro-inflammatory proteins including cytokines and interleukins [8]. In most cases, thromboembolic events occur during the remission period [9]. Venous thrombosis occurs even in previously anticoagulated patients [10]. According to the recommendations of the International Society of Thrombosis and Hemostasis (ISTH), anticoagulation with low molecular weight heparin is recommended for all patients who require hospitalisation [11]. Especially if the patient has a risk factor (active cancer, reduced mobility, D-dimer greater than 2 times normal) with a low risk of bleeding. Several studies have recommended the use of higher doses of unfractionated heparin in severe forms of COVID-19. [12]

This article represents, to our knowledge, the second documented case of thrombosis of a mechanical mitral valve prosthesis associated with COVID-19. The first case reported involved a 58-year-old patient who was adhering to her anticoagulant therapy. She had undergone mitral valve replacement six years earlier due to severe mitral stenosis. She presented with severe respiratory distress and palpitations two days before admission, leading to her transfer to the intensive care unit due to unstable respiratory condition. Her anti-vitamin K treatment was stopped and she was given therapeutic dose of enoxaparin. When the diagnosis of thrombosed mechanical heart valve prosthesis was made, enoxaparin was replaced by unfractionated heparin with an electric syringe pump (14,000 IU/D) for a weight of 80 kilograms [13].

In our case, the patient was taking her anticoagulant irregularly.

The sudden increase in the transmitral gradient, along with hemodynamic instability and limited mobility, strongly suggested prosthesis thrombosis or pannus formation. However, pannus formation is a chronic process and therefore does not lead to acute prosthesis dysfunction, this diagnosis was eliminated.

In our patient, we thought that the mechanical prosthesis thrombosis was due to hypercoagulability secondary to the SARS-CoV-2 infection. However, considering the therapeutic noncompliance, it is also possible that a combination of both mechanisms played a potentiating role.

Currently, there are no specific guidelines for managing patients with both COVID-19 and a prosthetic valve.

In this case, we opted for surgical intervention due to the obstructive thrombosis of the mitral valve prosthesis with hemodynamic instability. Surgery for obstructive prosthetic valve thrombosis is a high-risk surgery with a mortality that can reach 50%, especially for patients with NYHA class IV [14, 15].

Monitoring of anticoagulant therapy presents significant challenges, particularly regarding the risk of hemorrhage or thrombosis when management is suboptimal. Advances in perioperative care, surgical techniques and anesthesia have greatly improved the prognosis of these patients.

4. Conclusion

Left heart obstructive thrombosis is a surgical emergency with a high morbidity and mortality. Prevention is based on strict patient compliance and monitoring of anticoagulant therapy.

Further studies will be essential to better understand the role of COVID-19 in the occurrence of thrombo embolic events.

Conflict of Interest Statement

All the authors do not have any possible conflicts of interest.

Patient Consent

The patient's family has given their consent to use his data.

References

- [1] WHO. Rheumatic Fever and rheumatic heart disease: report of a WHO expert consultation. Geneva: World Health organization, 2004.
- [2] Sabahattin Gündüz, Macit Kalçık, Mustafa Ozan Gürsoy and al (2020): Diagnosis, treatment & management of prosthetic valve thrombosis: the key considerations, *Expert Review of Medical Devices*, 2020 Mar; 17 (3): 209-221.
- [3] M Y Abou-Ismaïl, A Diamond, S Kapoor and al. The hypercoagulable state in COVID-19: Incidence, pathophysiology, and management. *Thromb Res.* 2020 Oct; 194: 101-115.

- [4] Silbert H, Khan SS, Matloff The St Jude valve: thrombolysis as the first line of therapy for cardiac valve replacement. *Circulation* 1993; 87: 30.
- [5] Dürtleman N, Pellerin M, Bouchard D, Prosthetic valve thrombosis: twenty-year experience at the Montreal Heart Institute. *J Thorac Cardiovasc Surg* 2004; 127: 1388-1392.
- [6] Katneni U, Alexaki A, Hunt R C et al: Coagulopathy and Thrombosis as a Result of Severe COVID-19 Infection: A Microvascular Focus. *Thromb Haemost.* 2020 Dec; 120 (12): 1668-1679.
- [7] Chauban A J, Wiffen L, Brown T COVID-19: A collision of complement, coagulation and inflammatory pathways. *J Thromb and Haemost* Volume 18, Issue 9 p. 2110-2117.
- [8] Iba T, Levy J, Levi M et al Coagulopathy in COVID-19 *J Thromb and Haemost.* 2020 Sep; 18 (9): 2103-2109.
- [9] Langer F, Kluge S, Klamroth R et al Coagulopathy in COVID-19 and Its Implication for Safe and Efficacious Thromboprophylaxis. *Hamostaseologie* 2020 Aug; 40 (3): 264-269.
- [10] Fontana P, Casini A, Robert-Ebadi H, Glauser F, Righini M, Blondon M. Venous thromboembolism in COVID-19: systematic review of reported risks and current guidelines. *Swiss Med Wkly.* 2020; 150: w 20301.
- [11] Manolis A S, Manolis T A, Manolis A A et al COVID-19 Infection: Viral Macro- and Micro-Vascular Coagulopathy and Thromboembolism/Prophylactic and Therapeutic Management. *J Cardiovasc Pharmacol Ther* 2021 Jan; 26 (1): 12–24.
- [12] Di Micco P, Tufano A, Cardillo G and al, The impact of risk-adjusted heparin regimens on the outcome of patients with Codis 19 infection. *Viruses* 2021; 13: 1720.
- [13] Jeckelmann C, Djokic B, Duchatelle V and al Case report: Mechanical mitral prosthetic valve thrombosis in the context of COVID-19 despite effective anticoagulation. *European Heart Journal-case reports* (2022); 6 (2), 1-6.
- [14] Roudaut R, Serri K, and Lafitte S. Thrombosis of prosthetic heart valves: diagnosis and therapeutic considerations. *Heart.* 2007 Jan; 93 (1): 137-142.
- [15] Pibarot P, Dumesnil JG, Prosthetic heart valve: selection of optimal prosthetic and long-term management. *Circulation.* 2009; 119: 1034-48.