

# Gastric Actinomycosis Case Report and Literature Review

Plamen Chernopolsky\*, Rossen Madjov, Vasil Bozhkov, Ivan Krasnaliev, Valentina Madjova

University Hospital "St. Marina", Medical University, Varna, Bulgaria

## Email address:

p\_chernopolsky@yahoo.com (P. Chernopolsky)

\*Corresponding author

## To cite this article:

Plamen Chernopolsky, Rossen Madjov, Vasil Bozhkov, Ivan Krasnaliev, Valentina Madjova. Gastric Actinomycosis Case Report and Literature Review. *International Journal of Gastroenterology*. Vol. 5, No. 1, 2021, pp. 1-4. doi: 10.11648/j.ijg.20210501.11

**Received:** December 3, 2020; **Accepted:** January 11, 2021; **Published:** January 22, 2021

---

**Abstract:** Actinomycosis is an indolent infection that usually presents a diagnostic challenge to the physician. The most commonly affected zones are the cervicofacial, thoracic and abdominal areas. Abdominal actinomycosis although recognized for more than 150 years, is still wide unknown for most of the clinicians. Its various clinical manifestations are usually considered to present malignant process rather than infection. Intramural gastric actinomycosis is extremely rare clinical nosologic unit and usually the original source of infection is unknown. The usual clinical presentations include mild fever, epi- or mesogastric pain, weight loss, and bleeding from upper gastrointestinal tract. This chronic infection has tends to mimic malignancy. Gastric actinomycosis is very rare and with a good prognosis gastric disease. When established clinically, that is quite difficult diagnosis to be done before obtaining a surgical specimen. Although the findings are nonspecific, actinomycosis should be included in the differential diagnosis when CT scans show infiltrative mass with abnormal aggressiveness and dense enhancement of inhomogeneous contrast, especially in patients with leukocytosis, fever, or prolonged use of intrauterine contraceptives. We report a case of intramural gastric actinomycosis and review of cases of abdominal and gastric actinomycosis reported rarely in the literature. Reporting of such clinical case may help clinicians to increase the knowledge and awareness of this rare and treatable disease.

**Keywords:** Actinomycosis, Gastric Localization, Gastrectomy

---

## 1. Introduction

Actinomycosis –chronic infectious disease of farm animals and humans due to injury to the mouth with sharp and hard foods infected with the radiant fungus (actinomycetes), which exists mainly in cereals - rye, barley, straw, hay. Actinomycetes are a group of bacteria found as a natural flora of the oral cavity.

There are four main types of clinical forms of Actinomycosis, to wit - cervicofacial (31-65%), abdominal (20-36%), thoracic (15-30%) and cerebral form. Abdominal actinomycosis was first reported in 1846 by W. Bradshaw [4], (31 years before actinomyces were isolated). Gastric actinomycosis is very rare and with a good prognosis gastric disease. When established clinically, that is quite difficult diagnosis to be done before obtaining a surgical specimen.

## 2. Case Report

A 65-year old man was admitted in the Second Department of surgery with a 3-4 month history of epigastric discomfort and postprandial pain, nausea and rare vomiting, moderate weight loss (6-7 kg) and weakness. Physical examination revealed a moderate general condition, with a blood pressure 130/80, heart rate – 90/min. No fever, lack of palpable lymph nodes. The only abnormal finding during abdominal examination was a palpable tumor formation with a diameter approximately 9-10 cm in the upper abdomen.

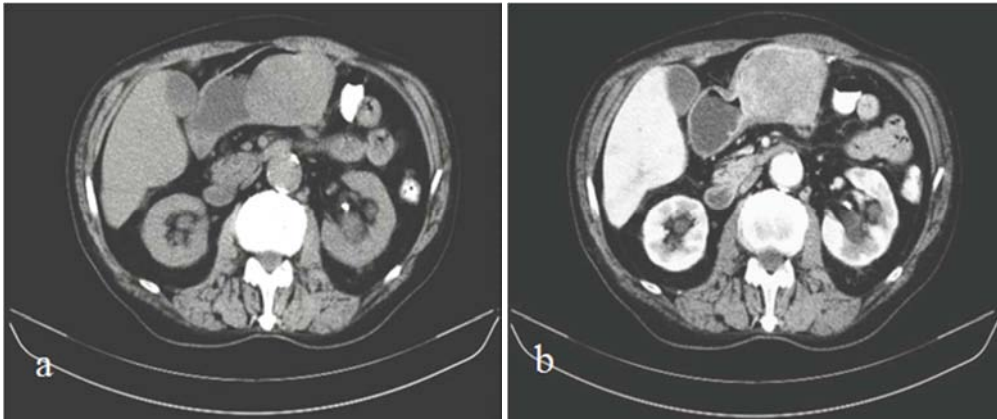
From laboratory test results: hemoglobin– 106 g/l; white blood cells (WBC) – 16,33; platelet (PLT) – 431; blood glucose – 3,8; creatinine – 93; ASAT – 15,3; GGT – 110,1; total protein – 70,0 g/l; sodium - 142,0; potassium – 4,90.

Ultrasound sonography was made – in left liver lobe a heterogeneous formation was found. A CT scan revealed a heterogenous tumor mass about 8/9 cm in diameter (Figure 1 a, b), coming from the smaller curvature of the stomach and a

lesion in the liver – about 5 mm in right lobe.

An upper gastrointestinal tract endoscopy was made - a polypoid lesion showing approximately 5-6 cm protuberance into the gastric lumen, at the lesser gastric curvature with

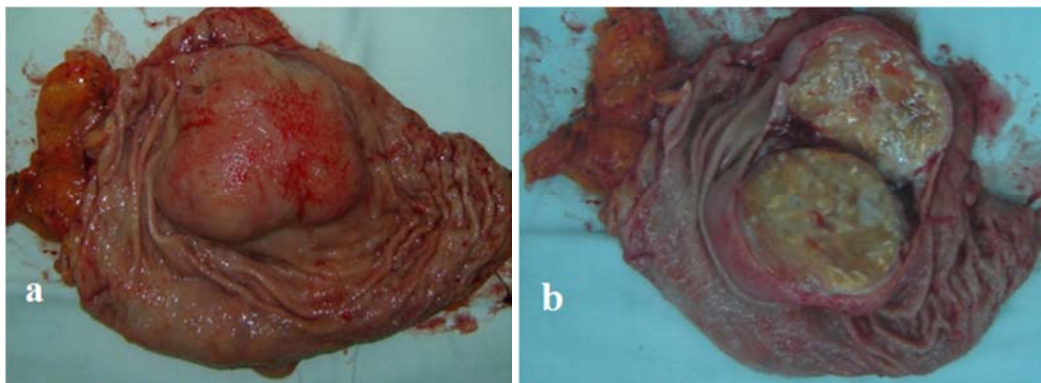
macroscopically normal mucosa above it. Biopsy specimens were negative for malignancy and showed nonspecific inflammatory reaction.



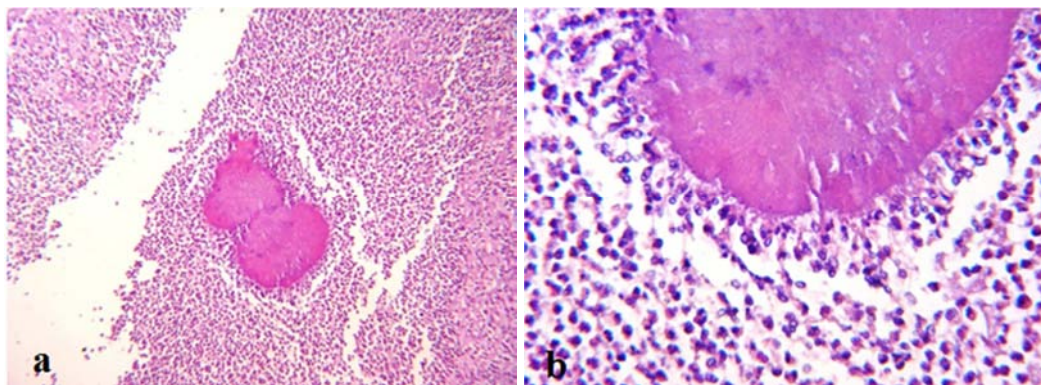
**Figure 1.** a – CT scan – tumor mass of the stomach; 1 b – contrast enhanced CT – diffuse heterogeneously enhancing mass-lesion in the stomach.

One unit of erythrocyte mass was transfused to increase hemoglobin before operation. An elective surgical intervention was performed with the presumption for gastric malignancy. During laparotomy a fixed tumor mass with

dimensions 9/6 cm in the posterior stomach wall was found (Figure 2 a, b), no other abdominal abnormalities. A subtotal gastrectomy Roux-en-Y type was performed.



**Figure 2.** a – Postoperative specimen; 2 b – Cutting surface of the specimen (well defined tumor; intact mucosa).



**Figure 3.** a – cavity filled with leukocytes, and among them floating actinomycetes granule [Hemalaun eosin 10 x 10]; 3 b – actinomycetes granule (Hemalaun eosin 10 x 40).

One week treatment with antibiotics and parenteral proton pump inhibitor was administered after the operation. The patient was discharged with normal postoperative period and followed up till now for a period of 6 months - in good health

and free from symptoms, proceeding with antibiotic treatment.

The pathohistological findings presented an inflammatory pseudo-tumor with chronic inflammatory cells, fibrous tissue.

Gastric actinomycosis was diagnosed by the finding of characteristic “sulfur granules” (Figure 3 a, b). All lymph nodes were negative for malignancy.

### 3. Discussion

Actinomycosis has a worldwide spreading and is found both among the urban and the inhabitants of the villages. It is a rare chronic granulomatous-suppurative inflammation caused by anaerobic, Gram-positive *Actinomyces* species. O. Bollinger (1877) isolated diverging mycelia from lesions in the jaw bones of neat. But Israel (1878) was the first who cultured the same mycelia using tissues of humans. Actinomycosis was first found in a living person by Ponfick in 1879 [4], and was first isolated under anaerobic conditions in 1891. Berardi (1979) first established the association between *Actinomyces israelii* and clinical signs of the abdominal actinomycosis [2].

The main form in humans is caused by *Actinomyces israelii*, and significantly less frequent by *A. naeslundii*, *odontolyticus*, *viscosus* or *meyeri* [6]. They are normal commensal indwellers of the female genital tract and human gastrointestinal tract. This bacterium does not invade intact mucous membrane and it can become pathogenic in the presence of injured mucosa. Once the infection is detected, the host elicits an intense inflammatory response (ie, with suppuration and granuloma formation).

There is no link between the disease and the habitat, social class or ethnicity, although early studies described a predominance of cases among villagers and farmers. There seems to be a male-to-female ratio of between 1,5:1 and 3:1.

The expected spread of the population is one case per 40 - 119 000 population [3].

The most commonly affected zones are the cervicofacial, thoracic and abdominal areas. Factors that predispose to abdominal actinomycosis include previous abdominal surgery, intestinal perforation, penetrating abdominal trauma, and foreign bodies [1, 8, 9].

The appendix and colon are the most commonly affected intra-abdominal organs, but the exact explanation for how these organs are infected is contradictory. Although organisms spread to other organs or anatomical structures by direct spread, hematogenous spread can also occur in some cases (as in patients with liver actinomycosis).

Gastric actinomycosis is extremely rare, possibly because the low gastric pH kills and inhibits the growth of the microorganisms. To date about 25 cases of gastric actinomycosis have been reported in the medical literature [7, 12, 14]. The usual clinical symptoms of gastric actinomycosis are mild fever, epigastric pain in the epigastrium area, nausea, vomiting, weight loss, fatigue and bleeding from the upper gastrointestinal tract [13, 18]. Some patients report the sensation of a mass in the abdomen. The duration of symptoms ranges from 30 days to several years.

It was once called actinomycosis as “the most misdiagnosed disease”. Clinical findings vary depending on the primary or main site of involvement and the duration of

the disease. Although actinomycosis usually causes a chronic, localized inflammatory process associated with fever and leukocytosis, the diagnosis is often not suspected. Laboratory tests are nonspecific – compatible with malignancy and inflammatory bowel disease (may show anemia and leukocytosis).

Radiographic and endoscopic studies, when available usually fail to yield the diagnosis and frequently suggest a malignancy or gastric ulcer. CT scanning is the most appropriate imaging modality (especially contrast enhanced). CT findings usually demonstrate an infiltrative lesion with diffuse thickening of the stomach wall. The appearance suggests adenocarcinoma or stomach lymphoma [8, 11].

Endoscopic biopsies are nonspecific because of the submucosal affection of the inflammatory tissue. A preoperative diagnose is practically impossible, unless fistulas are present and specimen of pus reveals the pathogen.

A definite diagnosis is almost always established after surgery and histopathological examination of the resected specimen and is usually based on histological identification of the actinomycotic granule or culture of *Actinomyces*, or both. Sections from biopsies reveal acute or chronic inflammation and granulation. Neutrophils, foamy macrophages, plasma cells and lymphocytes surrounding dense fibrotic tissue are commonly found. In majority of cases a tentative diagnosis is established by the histological appearance of the sulfur granules, a hallmark of actinomycosis composed of irregular masses of branched Gram-positive filaments with peripheral clubbing. They are usually considered in a diagnosis of actinomycete infection, but are present in only 50% of all cases [4, 10, 15]. The granules are often discrete, about 100 to 1000 micrometers in diameter, and are often seen directly without magnification or under the microscope with low magnification. The granules consist of a protein-polysaccharide complex and are mineralized by calcium and phosphate. Similar granules are also known in infections with other microorganisms – *Nocardia brasiliensis* or *Streptomyces madurae*.

The rare occurrence of the disease and its uncharacteristic clinical, radiological and endoscopic findings are the reasons for the frequent misconception of this condition as a neoplasm. This can lead to an unnecessary radical surgical procedure with many complications and even death. In our case, a Rout-en-Y subtotal gastrectomy was performed without additional complications.

In the case of gastric actinomycosis, a major surgical procedure or resection within the oncological range should be avoided, limited surgical resection is sufficient.

Uncomplicated actinomycosis can be treated medically with antibiotics. A long course of treatment is required due to the poor penetration of antibiotics into the fibrous tissue. The recommended antibiotic after surgery is Penicillin 18 to 24 million units per day, followed by oral administration Penicillin for 3-12 months. Ampicillin, amoxicillin, tetracycline, macrolides, clindamycin and cephalosporins were also reported to be effective. However, if actinomycosis can be completely removed by surgery, a shorter period of

antibiotic administration could be effective.

## 4. Conclusion

Abdominal and especially gastric actinomycosis still remains an uncommon clinical entity, which could mimic a great variety of intraabdominal complaints, covering from inflammatory diseases to malignant process. The presence of actinomyceal infection should be in physicians' mind when patients' clinical presentation is with unusual and atypical abdominal complaints.

Diagnosis is difficult and no test allows definite diagnosis - less than 10% are diagnosed preoperatively. Although the findings are nonspecific, actinomycosis should be included in the differential diagnosis when CT scans show infiltrative mass with abnormal aggressiveness and dense enhancement of inhomogeneous contrast, especially in patients with leukocytosis, fever, or prolonged use of intrauterine contraceptives.

Surgical resection of the engaged region of the stomach followed by high dose long-term antibiotics assures definite treatment of the disease.

## References

- [1] Acevedo F, Baudrand R, Letelier LM, et al. Actinomycosis: a great pretender: Case reports of unusual presentations and a review of the literature. *Int J Infect Dis.* 2008; 12: 358-362.
- [2] Berardi RS. Abdominal actinomycosis. *Surg Gynaecol Obstet* 1979; 149: 257-66.
- [3] Cintron JR, Del Pino A, Duarte B, Wood D. Abdominal actinomycosis. Report of two cases and review of the literature. *Dis Colon Rectum* 1996; 39: 105-8.
- [4] Cope Z. Visceral actinomycosis. *Br Med J* 1949; 2: 1311-6.
- [5] Das N, Lee J, Madden M, et al. A rare case of abdominal actinomycosis presenting as an inflammatory pseudotumour. *Int J Colorectal Dis.* 2006; 21: 483-484.
- [6] Garner J. P., M. Macdonald, P. K. Kumar - Abdominal actinomycosis. *International Journal of Surgery* (2007) 5, 441-448.
- [7] Fernandez-Acenero MJ, Silvestre V, Fernandez-Roldan R, Cortes L, Garcia-Blanch G. Gastric actinomycosis: A rare complication after gastric bypass for morbid obesity. *Obesity Surgery*; 14, 1012-1025.
- [8] Ha HK, Lee HJ, Kim H, Ro HJ. Abdominal actinomycosis: CT findings in 10 patients. *Am J Roentgenol* 1993; 161: 791-4.
- [9] Harsch IA, Benninger J, Niedobitek G, et al. Abdominal actinomycosis: complication of endoscopic stenting in chronic pancreatitis. *Endoscopy* 2001; 33: 1065-9.
- [10] Heo SH, Shin SS, Kim JW et al. Imaging of Actinomycosis in Various Organs: A Comprehensive Review. *RadioGraphics* 2014; 34: 19-33.
- [11] Kaszuba M, Tomaszewska R, Pityński K, et al. Actinomycosis mimicking advanced cancer. *Pol Arch Med Wewn* 2008; 118: 581-4.
- [12] Lee CM, Ng SH, Wan YL, Tsai CH. Gastric actinomycosis. *J Formos Med Assoc* 1996; 95 (1): 66-8.
- [13] Lee IJ, Ha HK, Park CM, et al. Abdominopelvic actinomycosis involving the gastrointestinal tract: CT features. *Radiology* 2001; 220 (1): 76-80.
- [14] Oksuz M, Sandikci S, Culhaci A, et al. Primary gastric actinomycosis: A case report. *Turkish Journal of Gastroenterology* 2007, Volume 18, No 1, page 44-46.
- [15] Schaal K, Lee H. Actinomycete infections in humans: a review. *Gene* 1992; 115: 201-11.
- [16] Sumer Y, Yilmaz B, Emre B, et al. Abdominal mass secondary to actinomyces infection: an unusual presentation and its treatment. *J Postgrad Med* 2004; 50: 115-7.
- [17] Yegüez JF, Martinez SA, Sands LR, Hellinger MD. Pelvic actinomycosis presenting as malignant large bowel obstruction: a case report and a review of the literature. *Am Surg* 2000; 66 (1): 85-90.
- [18] Weese WC, Smith IM. A study of 57 cases of actinomycosis over a 36-year period. *Arch Intern Med* 1975; 135: 1562-8.