

A Rare Case of Post-Traumatic Ludwig Angina in a Child

Rajkumari Khatri

Dr Rajkumari ENT & Head and Neck Oncology Centre, Indore, India

Email address:

raj.sachdeva@rediffmail.com

To cite this article:

Rajkumari Khatri. A Rare Case of Post-Traumatic Ludwig Angina in a Child. *International Journal of Otorhinolaryngology*. Vol. 8, No. 2, 2022, pp. 37-40. doi: 10.11648/j.ijo.20220802.12

Received: June 9, 2022; **Accepted:** June 27, 2022; **Published:** July 20, 2022

Abstract: Ludwig angina is life-threatening soft tissue cellulitis that occurs on the floor of the mouth, including the submental, sublingual, and submandibular spaces bilaterally. Ludwig Angina is a rapidly progressive inflammatory disease, predominantly affecting adults secondary to the dental infection, but may also affect children. So, a high index of suspicion is needed for early diagnosis and timely intervention to prevent complications and mortality. This article describes a rare case of post-traumatic Ludwig angina in a two-year-old child, following an oral cavity injury by an accidental fall on a metallic object (Tap). The patient with an injury in the oral cavity, especially the tongue and the floor of the mouth, should be informed about the life-threatening complications such as Ludwig Angina that may occur, therefore, such high risk case needs emergency admission, monitoring, and immediate medical treatment to prevent any compromised airway or any other life-threatening complications.

Keywords: Ludwig Angina, Complications, Post-Traumatic, Children

1. Introduction

The disease Ludwig Angina was originally addressed by a German army physician, Wilhelm Frederick von Ludwig in 1836, and it is labeled after him. It is also known otherwise as "Angina Ludovici".

Ludwig angina is a type of bacterial infection, a life-threatening type of soft tissue cellulitis involving 3 compartments on the floor of the mouth, including the submental, sublingual, and submandibular spaces bilaterally. The condition carries a risk of rapid progression and severe airway compromise and sudden fatality [1-4].

Originally, a Latin writer applied the term "Angina" to a condition in which difficulty in breathing and swallowing existed, either together or separately, accompanied by a feeling of choking, arising out of an inflammatory disease condition located between the mouth and the stomach.

Ludwig angina is a type of bacterial infection involving oral flora, both aerobes, and anaerobes. The most common organisms are *Staphylococcus*, and *Streptococcus*, whereas anaerobes such as *Bacteroides*, *Peptostreptococcus*, *Fusobacterium*, and *Actinomyces*. *Streptococcus Viridans* is the commonest organism in cases of dental infection.

Most deaths from this disease are caused by airway

compromise and resultant asphyxia. In the pre-antibiotic era, the mortality from this condition exceeded 50%. With rapid airway management and antibiotic therapy, along with advanced imaging and surgical procedures, mortality is approximately 8% [3, 4].

It was revealed in a clinical review that, in nearly 90% of Ludwig angina cases, dental infection was the cause, mostly from the lower molars, primarily second and third [1, 4]. Other less common etiologies comprise a penetrating injury to the floor of the mouth, osteomyelitis or fracture of the jaw, otitis media, tongue piercing, sialadenitis, and sialolithiasis of the submandibular glands, osteomyelitis, traumatic intubation, peritonsillar abscess, and infected thyroglossal cysts.

The infection progresses rapidly, leading to aspiration pneumonia and airway obstruction. The infection spreads lingually rather than buccally because the lingual aspect of the tooth socket is thinner. The infection can spread so far as to include the pharyngomaxillary and retropharyngeal spaces, encircling the airway [1, 4].

The conditions influencing Ludwig angina include dental caries, recent dental treatment, systemic illnesses such as diabetes mellitus, malnutrition, obesity, hepatic disorders, alcoholism, neutropenia, oral malignancy, haematological disorders or the consumption of toxic agents,

glomerulonephritis, and a compromised immune system (caused by AIDS or SLE, organ transplantation, sickle cell disease) [1, 4, 7, 10]. Most affected patients are between 20 and 60 years of age, although an age range of 12 days to 84 years has been reported. [1, 7] Any age group can be affected and no particular underlying systemic illness is needed [2]. Other common symptoms include mouth pain, hoarse voice, and sore throat. Stridor indicates impending airway obstruction, while dysarthria and increased tongue prominence indicate sublingual space involvement [1, 4, 5].

This paper describes a case report of Ludwig angina that developed from a penetrating injury to the floor of the mouth by a metallic object in a 2-year-old child who presented with Ludwig angina. This case is important as timely diagnosis, evaluation of the mode of presentation and prompt management have prevented the development of complication of abscess and its sequelae and mortality.

2. Case Report

A 2-year-old male child presented with a generalised bilateral swelling in the submandibular, submental, and sublingual regions along with an incised cut injury on the floor of the mouth. The child was crying excessively. The swelling developed following injury from a metallic object (tap) on the previous day, followed by bleeding from the oral cavity. The child was referred for suturing of the tongue wound and swelling management.

On examination, the General condition of the child was normal. He was afebrile, breathing regularly and rhythmically. On local examination, the floor of the mouth was elevated, and there was an incised gaping wound approximately 2 inches in size with exposed muscle with an elevated tongue and there was no evidence of infection as seen in figure 1. Generalized bilateral swelling in the submandibular, submental, and sublingual regions extending to the mid-portion of the neck, with mild tenderness as seen in figure 2. There was no active bleeding, no stridor, and no cyanosis. The patient has been admitted to the emergency & Conservative treatment started. On the next day, Investigations were done. The WBC count was 12000/cumm with polymorphs 80%. The x-ray ST-Neck lateral view revealed soft tissue swelling in the neck but the airway was not compromised.

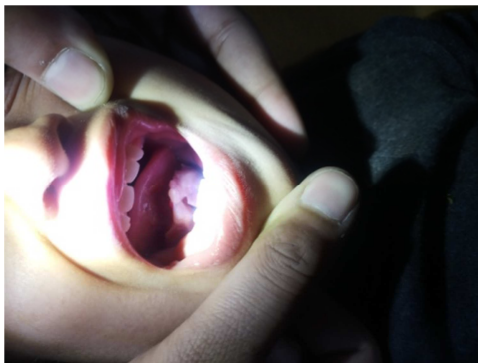

Figure 1. Injury to the floor of the mouth.

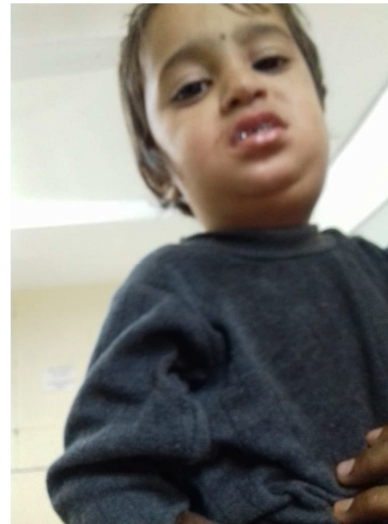


Figure 2. Cellulitis of the submental & submandibular region extending to the neck.

Considering the severe swelling of the floor of the mouth, tongue, sub-mental and sub-mandibular region, upper neck, risk of infection of cellulitis, prevention of subsequent complication of compromised breathing, immediate intervention with broad-spectrum intravenous antibiotics with cefixime, gentamicin & metronidazole, steroids & analgesic, and anti-inflammatory drugs were given. Local oral toileting with betadine oral rinse was done and kept nil by mouth for 3 days. The mother of the child was taught to nurture the child in the prone position over her shoulder to avoid the tongue fall and to massage the submental and submandibular regions towards the floor of the mouth to relieve edema as there was already an open wound in the floor of the mouth. Intravenous fluids were given for 3 days till the neck swelling regressed completely. On the 4th day, the patient was discharged with oral antibiotics and analgesics. The secondary suturing of the wound on the floor of the oral cavity was done after 10 days when the oral cavity swelling had completely receded. The child was followed for 3 months, and no complications were observed.

This is a very important case because Post-Traumatic Ludwig Angina is a rare disorder in children not reported so far in the literature. In children, the spread of the infection can rapidly compromise the airway, as its diameter is very small, and can lead to severe complications which may be proved fatal. Timely diagnosis and management were required, a slight delay in management would have led to complications like abscess formation, and spread to other neighbouring structures like neck muscles, airway, and mediastinum, which may be fatal. The suturing of the wound in the floor of the mouth was delayed, which helped in speedy recovery by releasing the pressure, thereby avoiding the pressure necrosis, and compromised airway.

3. Discussion

Ludwig angina was first mentioned in the literature by Wilhelm Friedrich von Ludwig in 1836, who described his

observations of patients with gangrenous induration of the connective tissues of the neck that advanced to involve the tissues that cover the small muscles between the larynx and the floor of the mouth. The condition involves all 3 compartments on the floor of the mouth, including the submental, sublingual, and submandibular spaces bilaterally [1]. In the present case, the swelling was found in the submental, submandibular, and sublingual regions extending to the mid-neck region within 24 hrs, following injury. However, the elevation of the floor of the mouth along with swelling of the tongue, and upper neck were observed, which were ominous signs, suggesting emergency intervention and observation. To prevent the secondary infection of the oral wound, local hygiene was done by betadine lotion as the child was too small to have local gorggles, only Intravenous fluids were given for 72 hrs, followed by clear fluids orally afterward for 2 weeks.

According to Kruger et al., Ludwig's angina is differentiated from other oro-cervical infections by bilateral impairment and raised tongue; in the absence of these symptoms, cellulitis may not be considered Ludwig angina [8, 9]. However, the extent of the disease might be underestimated in 70% of the cases [5]. In keeping with this notion, hospitalisation should be taken as the initial measure, and treatment should be based on 3 important aspects that include upper airway maintenance, drainage or surgical decompression, and intravenous antimicrobial therapy [7].

Any injury to the floor of the mouth should be managed immediately to prevent the rapid progression of the disease to the life-threatening condition of Ludwig Angina & subsequent complications. If the swelling develops following the injury, then suturing should be delayed. or if, for some reason, primary suturing is done in a case with cellulitis, the suture should be loosened to allow the edema to regress.

According to C Karuppasamy et al. age ranges from 5 years to 76 years. The most common age group involved was found to be the 5th decade. According to Syed Farhan Ali Razib, the highest numbers of patients were in their 3rd decade of life [2].

Almost all the patients came with complaints of neck swelling, pain, and fever. Dental infection was the commonest source of infection. In the present case, the cause of the Ludwig Angina was a penetrating injury to the floor of the mouth & age of the patient was only 2 years. All features of Ludwig Angina were present except fever, as immediately after injury, due to bleeding, he was attended to by the family physician and antibiotic and symptomatic treatment was started almost instantaneously.

Laboratory testing and imaging have no role in the immediate evaluation of the patient, as this is a clinical diagnosis. As this is most often an odontogenic infection, treatment includes removal of the offending teeth, also allowing for cultures to be obtained. If there is an abscess present, it can be drained [6].

Mihai Juncar et al. reported a case of a 58-year-old male patient with an intraorally open mandibular fracture that, left untreated for 3 days, was complicated by Ludwig angina.

Following aggressive surgical treatment, severe septic complications were avoided. While in the present case study, there was no suppuration, no fever, only cellulitis, leading to edema and swelling, though the WBC count was high. [10].

In 2018, Singh et al. reported a case of huge Ludwig Angina in a 6-month-old male child [11]. The tongue, which is soft in consistency, grows hard and becomes inflexible so that the patient will soon be suffocated unless relieved promptly [12]. It is more prevalent in adults, but up to a third of cases are reported in children [13]. Ludwig Angina is more common in boys than in girls [14]. Ludwig Angina usually develops in people with low immunity. Yet, it can also develop in healthy individuals [15].

Though the role of IV steroids is debatable, several case reports have shown a decrease in the need for airway management with the use of steroids. In this case study, the author has observed an improvement in cellulitis following steroid therapy. The duration of the antibiotics is usually two weeks. The WBC count and fever need to be monitored closely. Surgery is usually resorted to for patients who fail medical therapy.

4. Conclusion

Ludwig Angina is an inflammatory disease condition which may affect people of all ages, and is secondary to dental infection, especially molar teeth. In children, it is a rare disease that may occur following oral cavity injury in the floor of the mouth. Early diagnosis of Ludwig's angina is of great significance. Prompt intervention with broad-spectrum antibiotics and steroids, and surgical drainage will reduce the fatal outcome significantly, and, if needed, tracheostomy often gives much better results in the treatment of Ludwig's angina. Early detection and treatment of dental infections may help prevent the development of Ludwig's angina. Early intervention at the right time prevented the patient, in this case from further complications.

Conflicts of Interest

The author declare that she has no competing interests.

Acknowledgements

I gratefully acknowledge the parents of the child for sharing the case details for this paper with anonymity maintained.

I am highly thankful to Dr. V. S. Nanduri for providing guidance in writing the article.

References

- [1] Shemesh, A., Yitzhak, A., Itzhak, J B., Azizi, H., Solomonov, M. Ludwig Angina after First Aid Treatment: Possible Etiologies and Prevention—Case Report. *J Endod.* 2019; 45: 79–82.

- [2] Karuppasamy, C., Ganapathy, S., Rajkamal Pandian, D., kumar, S. Clinical Profile and Outcome of Ludwig's Angina in Tertiary Care Hospital in Tamil Nadu. *Int J Sci Stud.* 2019; 6 (12): 121-123.
- [3] Razib, SFA., Banerjee, S., Uddin, MM., Shameeussalam, K., Rahman, MM. Distribution and Determinants of Ludwig's Angina: Experience of 30 Cases in Bangladesh. *J Curr Adv Med Res.* 2016; 3 (1): 16-20.
- [4] Maheen, M., Gopakumar, A., Philip, RA., Thoma, Z. A Case Report on LUDWIG'S ANGINA: An ENT Emergency. *Asian J Pharm Clin Res.* 2019; 12 (6): 3-4.
- [5] Simsek, M., Yildiz, E., Hamdi, MA. Ludwig's angina: A case report. *J B R J Interdiscip Med Dent Sci.* 2014; 2: 1-4.
- [6] John, NM., Kumar, RA., Subbegowda, SH. Ludwig's Angina: A Study on Etiology and Factors affecting the Prognosis and Management. *Otorhinolaryngology Clinics: An International Journal.* 2018; 10 (2): 47-51.
- [7] Campos, MA., Prota, MLC., Gomes, CA., Amaral, KP., Almeida, DC. Ludwig's angina after severe thrombocytopenic purpura associated with dengue fever. *Rev Soc Bras Med Trop.* 2014; 47 (1): 116-118.
- [8] Kruger, G. *Oral and Maxillofacial Surgery.* 5th ed. Rio de Janeiro: Guanabara koogan; 1984.
- [9] Hyde, WP. Ludwig's Angina and Cervical Cellulitis (Differential diagnosis). *Jour. A. D. A.*; 1933: 2046.
- [10] Juncar, M., Juncar, R., Onisor-Gligor, F. Ludwig's angina A rare complication of mandibular fractures. *Journal of International Medical Research.* 2019; 47 (5): 2280-87.
- [11] Singh, AP., Tanger, R., Mathur, V., Gupta, AK. Ludwig's angina: Pediatric case report and literature review. *J Mahatma Gandhi Inst Med Sci [serial online]* 2018 [cited 2022 Jun 13]; 23: 89-91. Available from: <https://www.jmgims.co.in/text.asp?2018/23/2/89/243125>
- [12] Britt, JC., Josephson, GD., Gross, CW. Ludwig's angina in the pediatric population: Report of a case and review of the literature. *Int J Pediatr Otorhinolaryngol.* 2000; 52: 79-87.
- [13] Lin, HW., O'Neill, A., Cunningham, MJ. Ludwig's angina in the pediatric population. *Clin Pediatr (Phila).* 2009; 48: 583-7.
- [14] David, M., Lemonick, DM. (2002). Ludwig's angina: Diagnosis and treatment. *Hosp Physician.* 2002; 38: 31-7.
- [15] Srirompotong, S., Art-Smart, T. (2003). Ludwig's angina: A clinical review. *Eur Arch Otorhinolaryngol.* 2003; 260: 401-3.