

Choroidal Thickness and Correlations with Intraocular Pressure and Spherical Equivalent in Young Myopic Eyes without Maculopathy

Jiarui Xue¹, Xiaoqian Ji², Yan Yu¹, Changfan Wu^{1,*}

¹Department of Ophthalmology, Yijishan Hospital of Wannan Medical College, Wuhu, China

²Department of Ophthalmology, No. 2 People's Hospital of Fuyang City, Fuyang, China

Email address:

wucangfan@sina.com (Changfan Wu)

*Corresponding author

To cite this article:

Jiarui Xue, Xiaoqian Ji, Yan Yu, Changfan Wu. Choroidal Thickness and Correlations with Intraocular Pressure and Spherical Equivalent in Young Myopic Eyes without Maculopathy. *International Journal of Ophthalmology & Visual Science*. Vol. 6, No. 1, 2021, pp. 22-28.

doi: 10.11648/j.ijovs.20210601.14

Received: January 24, 2021; Accepted: February 10, 2021; Published: February 23, 2021

Abstract: Background: Refractive error is one of the causes of visual impairment worldwide, among which myopia is the most common. Myopia is prevalent worldwide, particularly in East and Southeast Asia, which have myopia prevalence rates of approximately 80-90% and high myopia prevalence rates of 10-20% in young adults. High myopia is closely related to a variety of pathological changes and a higher risk of blinding complication. Purpose: To identify the distribution of choroidal thickness (CT) and to determine whether there are associations between subfoveal choroidal thickness (SFCT) and intraocular pressure (IOP) and spherical equivalent (SE) in young healthy myopes without maculopathy. Methods: A total of 116 young subjects without maculopathy were recruited in this study and underwent comprehensive ophthalmic examinations. Enhanced depth imaging spectral domain optical coherence tomography was performed for CT measurement and assessment. SFCT, as well as CT at 3 mm nasal, temporal, superior and inferior to fovea were measured. Univariable linear regression analysis and Multiple regression analysis were used to study the correlation between SFCT and spherical equivalent (SE) as well as IOP. To assess the CT at each location and explore its associated factors. Results: The SFCT of high myopes was notably thinner ($197.00 \pm 35.21 \mu\text{m}$) compared with mild myopes ($287.05 \pm 68.31 \mu\text{m}$) and moderate myopes ($251.13 \pm 64.40 \mu\text{m}$). For all three groups, CT at 3 mm nasal was the thinnest ($195.21 \pm 52.43 \mu\text{m}$, $168.43 \pm 59.24 \mu\text{m}$, $129.56 \pm 30.97 \mu\text{m}$, respectively.) Univariable linear regression analysis indicated that SFCT decreased by $15.49 \mu\text{m}$ per diopter in myopic refractive change ($P < 0.001$, $R^2 = 0.146$) and decreased by $17.87 \mu\text{m}$ per 1mmHg increase in intraocular pressure (IOP) ($P < 0.001$, $R^2 = 0.440$). Multiple regression analysis indicated that there were significant correlations between SFCT and spherical equivalent (SE) as well as IOP in mild myopes and moderate myopes, but not in high myopes. Conclusions: A significant difference of the CT distribution was found in the centre region among myopes. However, nasal choroid thinning was the most obvious in all myopia groups. SFCT was significantly correlated with IOP and SE in the myopic population. However, the same correlation was not observed in young highly myopic eyes.

Keywords: Subfoveal Choroidal Thickness; Intraocular Pressure; Spherical Equivalent; Young Myopic Eyes

1. Introduction

Refractive error is the most common reason of vision disability in the world, among which myopia with great potential to be a leading cause for impairing vision. As everyone knows that the myopia is prevalent around the world, particularly in the Asia [1]. Myopia prevalence is

reported to be up to 80% in Chinese students. High myopia is also more common in Asian population with rate of 9-12% and keeping increasing.[2, 3]. High myopia is closely related to a variety of pathological changes and a higher risk of blinding complication, including cataract and glaucoma [4, 5]. Thus, understanding the risk factors and pathogenesis of myopia is very important for formulating possible prevention

and treatment strategies. The choroid provides nutrition and oxygen for the outer layer of retina and plays a crucial part in the emmetropization of eye [6]. Choroidal thickness is a good indicator for choroidal blood volume, flow, and choroidal function. The choroid important pathological changes include thinning and atrophy, which associated with the Incidence and progress of myopia.

Spectral domain optical coherence tomography (SD-OCT) is able to provide non-invasive, non-contact, high resolution, high sensitivity and depth-resolved optical imaging technology for investigating retinal structure, and plays an important role in diagnosis of ocular diseases. Enhanced depth imaging optical coherence tomography (EDI-OCT) has the capacity to image the choroid in vivo with enhanced visualization of the choroidal anatomy and choroidal thickness measurement [7, 8]. Using this technology, previous studies have found topographic variations of the choroid, and that CT is significantly thinner in myopic eyes than in emmetropic eyes [9-13]. Previous studies have also investigated the relationships between CT and other ocular or systemic variables [11, 14, 15]. Several factors, including age, refractive error and axial length (AL), have been consistently identified to be associated with CT among healthy adults. However, the subjects in lots of these researches are adults with age in a wide range and ametropia [10, 11, 16], whereas youth populations without maculopathy were less investigated [17-19]. Knowledge on the CT among youth populations without myopic macular disease (MMD) is of great value to better understand the normal growth of myopic eyes, and also conducive to diagnosis diseases of macula and choroid, given that evaluation of the macular choroidal thickness in macular diseases is confirmed to be an indispensable part.

Thus, the purpose of this study was to evaluate the distribution of CT and to investigate whether there are associations between CT and potential associated factors in MMD-free youth subjects with mild, moderate and high myopia.

2. Methods

2.1. Study Population

From January 2014 to November 2015, 116 healthy myopic subjects over the age of 17 were recruited in the Ophthalmological excimer optometry clinic of Yiji shan Hospital, Wannan Medical College, Wuhu, China. Subjects had to meet the inclusion criteria which additionally included: 20/25 or better best corrected vision; spherical equivalent (SE) ≥ -0.50 D; The results of three-mirror contact-lens showed normal fundus. The study distributed participants into three groups according to their SE: mild myopia group ($-0.50 \text{D} \leq \text{SE} < -3.00 \text{D}$), moderate myopia group ($-3.00 \text{D} \leq \text{SE} < -6.00 \text{D}$), and high myopia group ($\text{SE} \geq -6.00 \text{D}$). Exclusion criteria included three-mirror contact-lens examination revealed peripheral retinal lesions; Any coexisting or previous eye diseases that may confuse choroidal and scleral measurements in either eye, for instance corneal opacities, dense cataract, diabetic retinopathy, and

other fundus diseases. We also excluded subjects with corneal refractive surgery and ocular trauma or other diseases that may affect refraction, myopic maculopathy including lacquer crack, posterior staphyloma, myopic choroidal neovascularization. All participants known the research details and signed informed consents. The study has obtained approval from the first affiliated hospital of Wannan Medical College ethics committee and research contents conformed to the tenets of the Declaration of Helsinki.

2.2. Clinical and Ocular Examination

A full set of ophthalmic examination were performed on participants, including uncorrected and best-corrected visual acuity measurement, anterior and posterior of ocular segments slit-lamp examination, fundus examination with direct ophthalmoscopy, three-mirror contact-lens examination, objective cycloplegic auto-refraction measurement, and IOP measurements. Blood pressure, body height and weight were also measured by trained nurse per standardized protocol. Refractive error was measured by an autorefractor (KR-8900; Topcon, Tokyo, Japan) at 30 minutes after the third drop of cycloplegic agent (0.5% tropicamide 3 drops, 10-minute interval) was applied. The definition of spherical equivalent is the sum of spherical refractive error and half cylindrical refractive error. Noncontact tonometry (model NT-4000, Nidek) was applied to measure IOP, and the mean value of three measurement was recorded as the final value. Before performing EDI-OCT, the blood pressure of the right arm was measured, and the average value of at least three measurements was recorded. Participants had to rest for at least 5 minutes and performed an electronic sphygmomanometer at seating, resting position (ES-P2000; Terumo, Japan).

Spectral domain optical coherence tomography was performed using SD-OCT (Spectralis, Wavelength: 870 nm; Heidelberg Engineering Co, Heidelberg, Germany) with enhanced depth imaging modality and eye tracking and automated real-time averaging features by the same experienced specialist before pupil dilation. The chorioretinal interface was placed in the adjacency of the zero delay in the EDI option, the images in the vertical direction of retina and choroid were acquired. Scan lengths of 12 mm were used. The measurements of SFCT was performed at the foveal center in the horizontal and vertical line pattern. The above measurements were taken before pupil dilation and between 9 AM and 12 PM to minimize the potential confounding effects of cycloplegia or diurnal variations on choroidal thickness. Choroidal thickness (CT) was measured as the distance between the hyperreflective line corresponding to the Bruch membrane beneath the retinal pigment epithelium and the inner sclera border. The manual segmentation method was performed by a trained grader to manually measure the subretinal region and vertical and horizontal region at 3 mm from the fovea in 5 locations, respectively (Figures 1, 2). The evaluation of intraobserver reliability of choroidal thickness measurements was performed by the same grader who reassessed images of 20 eyes by randomly selected.

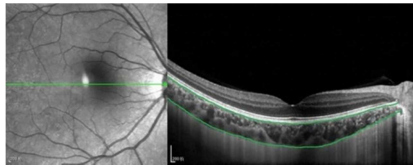


Figure 1. The choroidal thickness was measured at 1,500 lm temporal and nasal to the fovea (left temporal, right nasal).

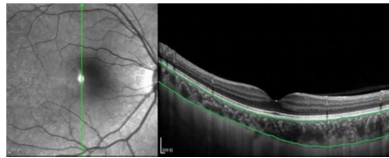


Figure 2. The choroidal thickness was measured at 1,500 lm superior and inferior to the fovea (left inferior and right superior).

2.3. Statistical Analysis

Measurements from the left eye of each participant were used for analysis. All continuous variables were reported as a mean \pm standard error. The Kolmogorov–Smirnov test was used for assessing the distribution of each parameter. For normally distributed variables, one-way analysis of variance (ANOVA) was used for statistical comparisons between groups, and the Bonferroni method was used for post hoc tests. For parameters of non-normal distribution, Kuskal-Wallis test was used for statistical comparisons between groups. The chi-square test was used for categorical variables. We examined the mean CT values of SFCT, and CT at 3 mm nasal, temporal, superior and inferior to fovea locations in three groups. Univariate regression analysis was used to evaluate the correlation between measurements of CT and other ocular or systemic parameters such as body mass index ($BMI = \text{body weight (kg)} / \text{height}^2 \text{ (m)}$), BP, age, and gender. Multiple regression analysis, with CT at five locations as dependent variables and the self parameters, such as BMI, BP, age, SE, and IOP of participants as independent variables, was used to determine the independent association of CT with all parameters in the three study groups. The association between variables was expressed by regression coefficient (r) and determinate coefficient (R^2). All P values were bilateral, and P values of less than 0.05 were considered statistically significance. 95% confidence intervals (CIs) were given. SPSS statistics version 21.0 was used for all analyses.

3. Results

This study analyzed 116 left eyes of 116 subjects (67 males, 49 females). Table 1 shows the demographic and clinical characteristics of enrolled subjects. Significant differences existed among the three groups regarding SE ($P < 0.001$) and SFCT ($P = 0.001$), but no significant difference was observed for age, sex, IOP, systolic blood pressure (SBP) and diastolic blood pressure (DBP) among the three groups.

Table 2 shows the SFCT and CT at 3 mm from the fovea temporally, nasally, superiorly and inferiorly. Among the three subgroups of myopia, mild myopia group's CT ($287.05 \pm 68.31 \mu\text{m}$) was higher than moderate myopia group's CT ($251.13 \pm 64.40 \mu\text{m}$) and high myopia group's CT ($197.00 \pm 35.21 \mu\text{m}$). There were

significant differences for the temporal, nasal, and superior CT among the three groups ($P = 0.04$, $P = 0.03$, and $P = 0.01$, resp.) However, inferior CT was not found to be statistically different among the three groups ($P = 0.1$). The thickest CT was found to be at the temporal location in moderate myopes ($252.75 \pm 58.29 \mu\text{m}$) and high myopes ($232.63 \pm 45.69 \mu\text{m}$), while the CT of the mild myopes was thickest at the SFCT location ($287.05 \pm 68.31 \mu\text{m}$). For mild myopia, moderate and high groups, choroid was thinnest at the nasal location ($195.21 \pm 52.43 \mu\text{m}$, $168.43 \pm 59.24 \mu\text{m}$, $129.56 \pm 30.97 \mu\text{m}$, respectively.)

Univariable linear regression analysis showed that SFCT decreased by approximately $15.49 \mu\text{m}$ with each diopter of myopic SE change ($P < 0.001$, $R^2 = 0.146$) (Figure 3) and decreased by $17.87 \mu\text{m}$ with each 1mmHg of IOP (Figure 4; $P < 0.001$, $R^2 = 0.440$). Results of multiple linear regression analysis is shown in Table 3. At the central foveal region, IOP, SE, weight, height and BMI have significant independent association with CT. Likewise, in the parafoveal regions, there is an independent relationship between SE and IOP and CT.

Furthermore, after stratification of myopic patients, it was found that SE and IOP in mild and moderate myopes were significantly correlated with the central foveal choroidal thickness, while no such relationship was observed in high myopes (Table 4). There was a positive correlation between BMI and SFCT in the mild myopia group (Table 4; $P < 0.05$) but not in the moderate or high myopia group.

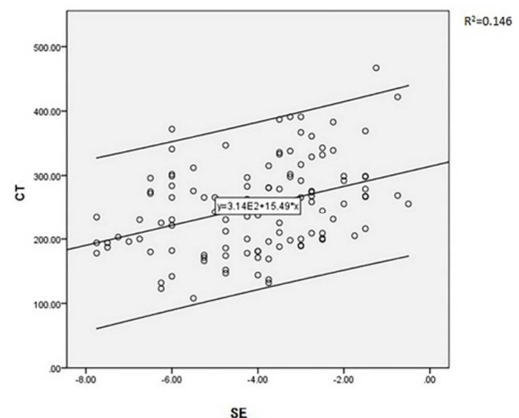


Figure 3. Scatterplot of spherical equivalent (SE) and subfoveal choroidal thickness (SFCT).

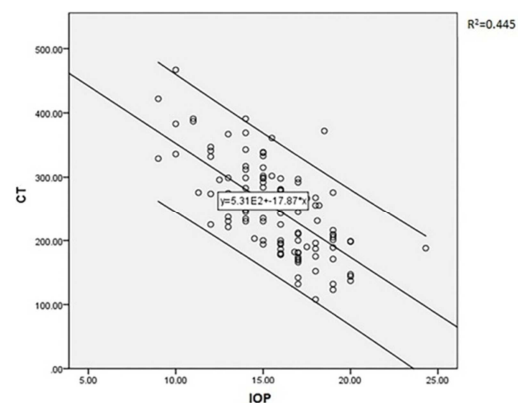


Figure 4. Scatterplot of intraocular pressure (IOP) and subfoveal choroidal thickness (SFCT).

Table 1. General characteristics of the participants among three groups.

	Total	Range	Mild myopia	Range	Moderate myopia	Range	High myopia	Range	P
Gender (M/F)	67/49		14/17		38/21		15/11		0.214 ^a
Age (years)	23.85±3.34	17~35	22.97±3.26	19~34	23.86±3.34	17~35	24.88±3.25	19~31	0.036 ^c
SE (diopters)	-4.06±1.74	-7.75~-0.50	-2.02±0.67	-2.75~-0.50	-4.02±0.76	-5.50~-3.00	-6.57±0.64	-7.75~-6.00	<0.001 ^c
IOP (Hg)	15.67±2.64	9.0~24.3	15.62±3.20	9.0~20.0	15.98±2.52	10.0~24.3	15.01±2.11	12.0~19.0	0.301 ^b
Weight (Kg)	62.81±9.57	44~89	66.31±9.31	50~89	60.45±9.16	46~80	63.98±9.60	44~81	0.011 ^c
Height (cm)	169.64±8.27	147.5~185.5	170.56±6.94	156.0~183.0	169.05±8.46	147.5~185.5	169.86±9.39	154.0~185.0	0.716 ^b
BMI (Kg/m ²)	21.76±2.91	15.73~31.53	22.81±3.31	18.14~31.53	21.06±2.74	15.73~28.23	22.12±2.39	17.19~26.69	0.029 ^c
SBP (Hg)	120.03±13.56	82~155	122.39±11.43	92~140	119.44±14.96	82~155	118.58±12.63	92~140	0.514 ^b
DBP (Hg)	75.98±9.75	41~98	76.55±10.04	54~93	75.44±9.89	41~90	76.53±9.35	60~98	0.889 ^c
SFCT (μm)	251.31±70.78	108~467	287.05±68.31	199~467	251.13±64.40	108~391	197.0±35.21	123~372	0.001 ^b

Abbreviation:

M male; F female; SE spherical equivalent; IOP intraocular pressure; BMI body mass index;

SBP systolic blood pressure; DBP diastolic blood pressure; SFCT subfoveal choroidal thickness.

a Statistical significance was tested using the chisquare test.

b Statistical significance was tested using the one way ANOVA.

c Statistical significance was tested using the Kuskal-Wallis test.

Table 2. Mean± standard error of the choroidal thickness among the three groups.

	Mild myopia	Moderate myopia	High myopia	P
SFCT(μm)	287.05±68.31	251.13±64.40	197.00±35.21	0.001 ^a
T (μm)	283.00±66.08	252.75±58.29	232.63±45.69	0.033 ^a
N (μm)	195.21±52.43	168.43±59.24	129.56±30.97	0.048 ^b
S (μm)	282.87±66.09	249.66±61.00	221.56±38.36	0.013 ^b
I (μm)	271.03±70.32	240.21±68.18	203.50±46.43	0.100 ^b

Abbreviation:

SFCT subfoveal choroidal thickness; T temporal; N nasal; S superior; I inferior.

a Statistical significance was tested using the one way ANOVA.

b Statistical significance was tested using the Kuskal-Wallis test.

Table 3. Multiple regression analysis of associations with choroidal thickness.

		Age	SE	IOP	Weight	Height	BMI	SBP	DBP
SFCT	Coefficients	0.35	16.58	-17.93	7.46	-6.48	-19.48	0.41	-0.02
	(95% CI†)	(-2.12~2.82)	(12.03~21.13)	(-20.91~-14.95)	(1.5~13.42)	(-10.83~-2.13)	(-36.51~-2.45)	(-0.37~1.19)	(-1.06~1.02)
	R ²	0.674							
	P Value	0.784	<0.001	<0.001	0.016	0.004	0.027	0.313	0.964
T	Coefficients	0.72	10.1	-12.99	-4.56	2.33	12.7	0.24	-0.01
	(95% CI†)	(-2.75~4.19)	(3.71~16.49)	(-17.18~-8.8)	(-12.95~3.83)	(-3.8~8.46)	(-11.29~36.69)	(-0.86~1.34)	(-1.48~1.46)
	R ²	0.317							
	P Value	0.686	0.003	<0.001	0.289	0.458	0.302	0.676	0.993
N	Coefficients	-0.34	9.47	-12.87	2.54	-3.13	-6.42	0.28	0.06
	(95% CI†)	(-3.16~2.48)	(4.3~14.64)	(-16.26~-9.48)	(-4.26~9.34)	(-8.09~1.83)	(-25.84~13)	(-0.62~1.18)	(-1.14~1.26)
	R ²	0.431							
	P Value	0.816	0.0005	<0.001	0.466	0.219	0.519	0.544	0.917
S	Coefficients	1.93	11.88	-13.94	1.19	-1.11	-1.69	0.66	-0.76
	(95% CI†)	(-0.91~4.77)	(6.67~17.09)	(-17.35~-10.53)	(-5.65~8.03)	(-6.11~3.89)	(-21.25~17.87)	(-0.24~1.56)	(-1.96~0.44)
	R ²	0.468							
	P Value	0.186	<0.001	<0.001	0.734	0.665	0.866	0.154	0.212
I	Coefficients	-1.09	6.25	-13.23	5.26	-5.03	-12.29	0.75	-0.8
	(95% CI†)	(-4.32~2.14)	0.29~12.21)	(-17.13~-9.33)	(-2.56~13.08)	(-10.75~-0.69)	(-34.67~10.09)	(-0.27~1.77)	(-2.17~0.57)
	R ²	0.385							
	P Value	0.512	0.042	0.031	0.190	0.088	0.284	0.154	0.252

Abbreviation:

SE spherical equivalent; IOP intraocular pressure; BMI body mass index;

SBP systolic blood pressure; DBP diastolic blood pressure; SFCT subfoveal choroidal thickness.

T temporal; N nasal; S superior; I inferior. coefficient of determination.

R² coefficient of determination. CI confidence interval

Table 4. Multiple regression analysis of associations with subfoveal choroidal thickness among three groups.

	Mild myopia			Moderate myopia			High myopia		
	Coefficients (95% CI†)	R ²	P Value	Coefficients (95% CI†)	R ²	P Value	Coefficients (95% CI†)	R ²	P Value
Gender (M/F)	-2.2(-29.99~25.59)	0.840	0.878	-0.03(-24.69~24.63)	0.722	0.998	19.98(-36~75.96)	0.589	0.494
Age (years)	1.64(-2.3~5.58)		0.422	0.7(-2.65~4.05)		0.684	-2.59(-10.74~5.56)		0.541
SE (diopters)	22.26(4.37~40.15)		0.024	25.16(10.62~39.7)		0.001	18.27(-19.42~55.96)		0.356
IOP (Hg)	-16.02(-20.59~-11.45)		<0.001	-18.81(-23.24~-14.38)		<0.001	-7.95(-21.63~5.73)		0.271
Weight (Kg)	29.56(9.55~49.57)		0.009	3(-3.53~9.53)		0.373	27.03(-16.27~70.33)		0.239
Height (cm)	-22.08(-37.58~-6.58)		0.011	-3.64(-8.21~0.93)		0.124	-21.39(-53.79~11.01)		0.214
BMI (Kg/m ²)	-84.79(-142.26~-27.32)		0.009	-5.36(-24.33~13.61)		0.583	-65.79(-190.8~59.22)		0.318
SBP (Hg)	0.81(-0.37~1.99)		0.187	-0.4(-1.6~0.8)		0.511	1.12(-1.58~3.82)		0.430
DBP (Hg)	-0.99(-2.62~0.64)		0.250	1.66(-0.01~3.33)		0.056	-1.39(-6.11~3.33)		0.573

Abbreviation:

M male; F female; SE spherical equivalent; IOP intraocular pressure; BMI body mass index;

SBP systolic blood pressure; DBP diastolic blood pressure;

R² coefficient of determination. CI† confidence interval

4. Discussion

In this research, we made exploration on the distribution of CT in the macular region in young myopic eyes without MMD. We found that CTs in the superior and temporal region were significantly thicker than that of the nasal region. In addition, SE and IOP were found to be significantly associated with SFCT in participants with mild or moderate myopia, but not in high myopes.

Previous studies yielded conflicting data on CT in myopes. Reported average subretinal CT of young myopic participants was between 241 μ m and 322 μ m [14, 17-19]. In this research, the young myopic eye's mean SFCT was 251.13 \pm 70.78 μ m. Variations in reported CT may be attributed to differences in participants' characteristics such as age and refractive error, measurement methods and fluctuations of CT. Meanwhile, our study showed that the subfoveal choroid was much thinner in the high myopic group than in the mild and moderate myopic groups, which is consistent with prior studies. Distribution of CT among people with different refractive status had been reported but with inconsistent findings. Our study found that CT was largest at 3mm temporal in moderate and highly myopic eyes, whereas the greatest CT in mild myopia eyes was observed at the fovea. These results were consistent with the findings of the current study which revealed the choroidal thickness to be higher in superior and temporal regions as compared with inferior and nasal. These findings were supported by Zhang et al. who conducted a similar study found that the greatest choroidal thickness was under fovea in low myopic eyes, but the greatest choroidal thickness of moderate and high myopic eyes was in the temporal region [13]. Several studies on choroidal thickness in young myopes, the nasal CT was reported to be significantly lower than the temporal, superior, and inferior choroid thickness measured at a distance of 3 mm from the fovea [17-20]. Differences in population characteristics may lead to different CT and make comparisons between these studies much more difficult. The nasal thickness has been reported to be the thinnest in most studies. The reason is not fully understood, but may be associated to the staphylomatous pathologic changes which include the regions of macular and optic nerve as a result of

increasing axial elongation of common myopic changes.

In our study, SFCT decreased with larger BMI, higher IOP and more myopic SE, but association between CT and age, gender and BP were not statistically significant at all measured locations. An age-related decline in SFCT has been well established by previous studies with a wide range of age [21-23]. The narrow age range, 20-25 years, may explain the lack of association between age and CT in our study. Associations of CT with gender were inconsistent among previous studies [14]. Our study did not find a gender difference, which is similar to the other studies investigating pediatric populations [18]. Previous studies found that the choroidal blood flow was associated with SBP [24, 25], but BP was not associated with CT in our study, which may be due to that our study participants were mostly young and healthy with a limited range of BP. Kim et al. showed no correlation between CT and BMI in young, healthy subjects aged 22.3 \pm 3 years [18]. Yilmaz et al. reported that obesity had a significant impact on CT of healthy individuals using OCT among 160 healthy individuals aged 26.5 \pm 6.9 years [26]. It is suggested with microvascular changes in retinal vessels could be affected by obesity and increased BMI. In our study, a positive association between SFCT and BMI was found, and this may be secondary to microvascular changes associated with obesity.

Most researchers found a significant negative correlation between SFCT and SE [18, 21, 27, 28]. Ikuno et al. presented important contacts between choroidal thickness, SE, CT, and posterior staphyloma height [21]. Chen et al. found a correlation between CT and SE [28]. In our study, CT was also found to be strongly associated with SE, with a decrease in CT of 15.49 μ m for each diopter of myopic shift. Reported SFCT/D refraction change increment was 6.205-13.6 μ m in previous studies [21, 23, 29, 30]. Fujiwara et al. discovered a highly association between CT and SE, per negative D decreased by 8.7 μ m. Similarly, Xiong et al. found a reduction of 7.6 μ m per negative D [30]. Ho et al found a decrease of 6.205 μ m for each diopter of myopia [23]. But they had no significant correlations with adjusting for any potential compounding factors in some studies [31, 32]. No conclusions had been reached regarding the relationships between CT and IOP [20, 24]. Some researches have indicated IOP change as a potential

mechanism for choroidal regulation of retinal temperature, but not generally accepted. It is believed that IOP induces choroidal tissue changes through an autoregulatory mechanism. We found a positive association between IOP and SFCT, which was consisted with some previous studies [18, 20]. Duan et al. reported that IOP was the strongest factor for CT under the fovea in patients with mild to moderate myopia among 307 Chinese medical students aged 18.8 ± 2.3 years [20]. Kim et al. also found an association between CT and IOP in young, healthy subjects with myopia of <-6.0 D [18]. Potential mechanism included decreased pressure of external scleral vein and increased outflow of aqueous humor with higher IOP. However, Pekel et al. found no association between SFCT and IOP in a study including 106 eyes of 106 healthy adult subjects aged 42.0 ± 15.7 years [33]. A meta-analysis study also found that there was no significant association between SFCT and IOP [34].

Interestingly, the significant correlation between SE, IOP and SFCT only existed in the mild and moderate myopia groups, but not in the high myopia group in our study. Most previous studies also found no significant association between SE and SFCT in high myopic groups [12, 32, 35, 36]. They found that choroidal thickness in the macula had a negative correlation with axial length, whereas it had no correlation with refractive error, indicating AL to be better predictable ability for CT than SE. Considering this difference, Over axial extension of the eyeball in high myopia will stretch and thin the biomechanics of choroid, retina and sclera.

The study has a few limitations. First, the correlation of SFCT with other factors, such as AL, visual acuity and retinal thickness, was not analyzed, which might be worthy of further investigation. Second, our study population included only myopic subjects, thus the study conclusion could not be directly generalized to hyperopic and emmetropic subjects. The hospital-based design and relatively small sample size in this study all weakened the representativeness of the study. Finally, CT was measured manually and by only one examiner due to unavailability of automated analysis software in our clinic. However, the results of manual assessments have been shown to have perfect reproducibility and reliability.

5. Conclusion

In conclusion, we found that the more central regions of myopic patients are more different. We showed that high myopic young's eyes had significantly thinner choroids in SFCT and nasal than mild and moderate myopia. The thickest choroidal area in moderate myopia was temporal region, and it higher than mild myopia emporal region. The nasal CT was thinnest in all eyes. In the myopic population IOP influence overall CT in negative correlation, and SE influence overall CT in positive correlation. However, SFCT in young highly myopic eyes was no correlated with increasing IOP, and SE. These findings will provide baseline information before the formation of myopic maculopathy and controbute to further understanding the development and mechanism of myopia.

Financial Support

No.

Conflict of Interest

All the authors do not have any possible conflicts of interest.

Acknowledgements

This research was completed using data collected through choroidal thickness and associated factors in young myopic eyes without maculopathy. The young myopic eyes without maculopathy study is managed by the Department of Ophthalmology, Yijishan Hospital of Wannan Medical College. We thank the many hundreds of people participating in the young myopic eyes without maculopathy study.

References

- [1] Holden, B. A., T. R. Fricke, D. A. Wilson, M. Jong, K. S. Naidoo, P. Sankaridurg, T. Y. Wong, T. J. Naduvilath, and S. Resnikoff, *Global Prevalence of Myopia and High Myopia and Temporal Trends from 2000 through 2050*. Ophthalmology, 2016. 123 (5): p. 1036-42.
- [2] He, M., Y. Zheng, and F. Xiang, *Prevalence of myopia in urban and rural children in mainland China*. Optom Vis Sci, 2009. 86 (1): p. 40-4.
- [3] Chen, M., A. Wu, L. Zhang, W. Wang, X. Chen, X. Yu, and K. Wang, *The increasing prevalence of myopia and high myopia among high school students in Fenghua city, eastern China: a 15-year population-based survey*. BMC Ophthalmol, 2018. 18 (1): p. 159.
- [4] Saw, S. M., G. Gazzard, E. C. Shih-Yen, and W. H. Chua, *Myopia and associated pathological complications*. Ophthalmic Physiol Opt, 2005. 25 (5): p. 381-91.
- [5] Lai, T. Y., D. S. Fan, W. W. Lai, and D. S. Lam, *Peripheral and posterior pole retinal lesions in association with high myopia: a cross-sectional community-based study in Hong Kong*. Eye (Lond), 2008. 22 (2): p. 209-13.
- [6] Nickla, D. L. and J. Wallman, *The multifunctional choroid*. Prog Retin Eye Res, 2010. 29 (2): p. 144-68.
- [7] Spaide, R. F., H. Koizumi, and M. C. Pozzoni, *Enhanced depth imaging spectral-domain optical coherence tomography*. Am J Ophthalmol, 2008. 146 (4): p. 496-500.
- [8] Fujiwara, T., Y. Imamura, R. Margolis, J. S. Slakter, and R. F. Spaide, *Enhanced depth imaging optical coherence tomography of the choroid in highly myopic eyes*. Am J Ophthalmol, 2009. 148 (3): p. 445-50.
- [9] Deng, J., X. Li, J. Jin, B. Zhang, J. Zhu, H. Zou, X. Xu, J. Xie, L. Wang, S. Zhu, and X. He, *Distribution Pattern of Choroidal Thickness at the Posterior Pole in Chinese Children With Myopia*. Invest Ophthalmol Vis Sci, 2018. 59 (3): p. 1577-1586.

- [10] Wei, W. B., L. Xu, J. B. Jonas, L. Shao, K. F. Du, S. Wang, C. X. Chen, J. Xu, Y. X. Wang, J. Q. Zhou, and Q. S. You, *Subfoveal choroidal thickness: the Beijing Eye Study*. *Ophthalmology*, 2013. 120 (1): p. 175-80.
- [11] Qi, Y., L. Li, and F. Zhang, *Choroidal Thickness in Chinese Children Aged 8 to 11 Years with Mild and Moderate Myopia*. *J Ophthalmol*, 2018. 2018: p. 7270127.
- [12] Wang, S., Y. Wang, X. Gao, N. Qian, and Y. Zhuo, *Choroidal thickness and high myopia: a cross-sectional study and meta-analysis*. *BMC Ophthalmol*, 2015. 15: p. 70.
- [13] Zhang, Q., M. Neitz, J. Neitz, and R. K. Wang, *Geographic mapping of choroidal thickness in myopic eyes using 1050-nm spectral domain optical coherence tomography*. *J Innov Opt Health Sci*, 2015. 8 (4): p. 1550012.
- [14] Li, X. Q., M. Larsen, and I. C. Munch, *Subfoveal choroidal thickness in relation to sex and axial length in 93 Danish university students*. *Invest Ophthalmol Vis Sci*, 2011. 52 (11): p. 8438-41.
- [15] Hsu, C. C., S. J. Chen, A. F. Li, and F. L. Lee, *Systolic blood pressure, choroidal thickness, and axial length in patients with myopic maculopathy*. *J Chin Med Assoc*, 2014. 77 (9): p. 487-91.
- [16] Zhang, J. M., J. F. Wu, J. H. Chen, L. Wang, T. L. Lu, W. Sun, Y. Y. Hu, W. J. Jiang, D. D. Guo, X. R. Wang, H. S. Bi, and J. B. Jonas, *Macular Choroidal Thickness in Children: The Shandong Children Eye Study*. *Invest Ophthalmol Vis Sci*, 2015. 56 (13): p. 7646-52.
- [17] Harb, E., L. Hyman, J. Gwiazda, W. Marsh-Tootle, Q. Zhang, W. Hou, T. T. Norton, K. Weise, K. Dirkes, L. M. Zangwill, and C. S. Group, *Choroidal Thickness Profiles in Myopic Eyes of Young Adults in the Correction of Myopia Evaluation Trial Cohort*. *Am J Ophthalmol*, 2015. 160 (1): p. 62-71 e2.
- [18] Kim, M., S. S. Kim, H. J. Kwon, H. J. Koh, and S. C. Lee, *Association between choroidal thickness and ocular perfusion pressure in young, healthy subjects: enhanced depth imaging optical coherence tomography study*. *Invest Ophthalmol Vis Sci*, 2012. 53 (12): p. 7710-7.
- [19] Tan, C. S., K. X. Cheong, L. W. Lim, and K. Z. Li, *Topographic variation of choroidal and retinal thicknesses at the macula in healthy adults*. *Br J Ophthalmol*, 2014. 98 (3): p. 339-44.
- [20] Duan, F., Z. Yuan, J. Deng, Y. L. Wong, A. C. Yeo, and X. Chen, *Choroidal Thickness and Associated Factors among Adult Myopia: A Baseline Report from a Medical University Student Cohort*. *Ophthalmic Epidemiol*, 2019: p. 1-7.
- [21] Ikuno, Y., K. Kawaguchi, T. Nouchi, and Y. Yasuno, *Choroidal thickness in healthy Japanese subjects*. *Invest Ophthalmol Vis Sci*, 2010. 51 (4): p. 2173-6.
- [22] Liu, B., Y. Wang, T. Li, Y. Lin, W. Ma, X. Chen, C. Lyu, Y. Li, and L. Lu, *Correlation of subfoveal choroidal thickness with axial length, refractive error, and age in adult highly myopic eyes*. *BMC Ophthalmol*, 2018. 18 (1): p. 127.
- [23] Ho, M., D. T. Liu, V. C. Chan, and D. S. Lam, *Choroidal thickness measurement in myopic eyes by enhanced depth optical coherence tomography*. *Ophthalmology*, 2013. 120 (9): p. 1909-14.
- [24] Maul, E. A., D. S. Friedman, D. S. Chang, M. V. Boland, P. Y. Ramulu, H. D. Jampel, and H. A. Quigley, *Choroidal thickness measured by spectral domain optical coherence tomography: factors affecting thickness in glaucoma patients*. *Ophthalmology*, 2011. 118 (8): p. 1571-9.
- [25] Polak, K., E. Polska, A. Luksch, G. Dorner, G. Fuchsjager-Mayrl, O. Findl, H. G. Eichler, M. Wolzt, and L. Schmetterer, *Choroidal blood flow and arterial blood pressure*. *Eye (Lond)*, 2003. 17 (1): p. 84-8.
- [26] Yilmaz, I., A. Ozkaya, M. Kocamaz, S. Ahmet, H. M. Ozkaya, D. Yasa, A. Agca, A. T. Yazici, and A. Demirok, *Correlation of Choroidal Thickness and Body Mass Index*. *Retina*, 2015. 35 (10): p. 2085-90.
- [27] Ding, X., J. Li, J. Zeng, W. Ma, R. Liu, T. Li, S. Yu, and S. Tang, *Choroidal thickness in healthy Chinese subjects*. *Invest Ophthalmol Vis Sci*, 2011. 52 (13): p. 9555-60.
- [28] Chen, W., Z. Wang, X. Zhou, B. Li, and H. Zhang, *Choroidal and photoreceptor layer thickness in myopic population*. *Eur J Ophthalmol*, 2012. 22 (4): p. 590-7.
- [29] Shin, J. W., Y. U. Shin, H. Y. Cho, and B. R. Lee, *Measurement of choroidal thickness in normal eyes using 3D OCT-1000 spectral domain optical coherence tomography*. *Korean J Ophthalmol*, 2012. 26 (4): p. 255-9.
- [30] Xiong, S., X. He, J. Deng, M. Lv, J. Jin, S. Sun, C. Yao, J. Zhu, H. Zou, and X. Xu, *Choroidal Thickness in 3001 Chinese Children Aged 6 to 19 Years Using Swept-Source OCT*. *Sci Rep*, 2017. 7: p. 45059.
- [31] Ozdogan Erkul, S., Z. Kapran, and O. M. Uyar, *Quantitative analysis of subfoveal choroidal thickness using enhanced depth imaging optical coherence tomography in normal eyes*. *Int Ophthalmol*, 2014. 34 (1): p. 35-40.
- [32] Hirata, M., A. Tsujikawa, A. Matsumoto, M. Hangai, S. Ooto, K. Yamashiro, M. Akiba, and N. Yoshimura, *Macular choroidal thickness and volume in normal subjects measured by swept-source optical coherence tomography*. *Invest Ophthalmol Vis Sci*, 2011. 52 (8): p. 4971-8.
- [33] Pekel, G., S. Acer, R. Yagci, S. Ozdemir, H. Kaya, M. C. Hiraali, and E. N. Cetin, *Relationship Between Subfoveal Choroidal Thickness, Ocular Pulse Amplitude, and Intraocular Pressure in Healthy Subjects*. *J Glaucoma*, 2016. 25 (7): p. 613-7.
- [34] Wang, W. and X. Zhang, *Choroidal thickness and primary open-angle glaucoma: a cross-sectional study and meta-analysis*. *Invest Ophthalmol Vis Sci*, 2014. 55 (9): p. 6007-14.
- [35] Gupta, P., S. M. Saw, C. Y. Cheung, M. J. Girard, J. M. Mari, M. Bhargava, C. Tan, M. Tan, A. Yang, F. Tey, G. Nah, P. Zhao, T. Y. Wong, and C. Y. Cheng, *Choroidal thickness and high myopia: a case-control study of young Chinese men in Singapore*. *Acta Ophthalmol*, 2015. 93 (7): p. e585-92.
- [36] Chen, W., H. Song, S. Xie, Q. Han, X. Tang, and Y. Chu, *Correlation of macular choroidal thickness with concentrations of aqueous vascular endothelial growth factor in high myopia*. *Curr Eye Res*, 2015. 40 (3): p. 307-13.