

Case Report

Vogt-Koyanagi-Harada Disease and Vogt-Koyanagi-Harada Resembling Syndrome

Deepesh Arora^{1,*}, Kanika Gupta², Ankit Parasher³, Deepak Anthwal⁴, Niyaz Ahmad⁵,
Dinesh Sharma⁶

¹Department of Vitreo-retina, Amritsar Eye clinic, Dehradun, India

²Department of Paediatric Ophthalmology, Amritsar Eye Clinic, Dehradun, India

³Department of MRI and CT Imaging, Suri Diagnostic and Imaging Centre, Dehradun, India

⁴Department of Vitreo-retina, Arvind Eye Hospital, Coimbatore, India

⁵Department of Medicine, Shri Guru Ram Rai Institute of Medical and Health Sciences and Shri Mahant Indires Hospital, Dehradun, India

⁶Amritsar Eye Clinic, Dehradun, India

Email address:

drda198591@gmail.com (D. Arora), dr.kanika_021987@yahoo.com (K. Gupta), docankitparashar@gmail.com (A. Parasher),
deepakanthwal2008@gmail.com (D. Anthwal), niyazahmad5419@gmail.com (N. Ahmad), drdineshsharma@rediffmail.com (D. Sharma)

*Corresponding author

To cite this article:

Deepesh Arora, Kanika Gupta, Ankit Parasher, Deepak Anthwal, Niyaz Ahmad, Dinesh Sharma. Vogt-Koyanagi-Harada Disease and Vogt-Koyanagi-Harada Resembling Syndrome. *International Journal of Ophthalmology & Visual Science*. Vol. 6, No. 1, 2021, pp. 29-40. doi: 10.11648/j.ijovs.20210601.15

Received: February 5, 2021; Accepted: February 14, 2021; Published: February 26, 2021

Abstract: Background: To present myriad and unique presentation of Vogt-Kayanagi-Harada Disease (VKHD) and Vogt-Koyanagi-Harada (VKH) resembling syndrome. Methods: This is observational series of four cases of VKH disease with variable unique visual presentation which ranged from blurring of vision, tinnitus, hot flushes on face and abdomen, presence of floaters with headache, breathlessness and history of weight loss. The patient age ranged from 14-56 years. Symptoms developed acutely ranging from 4-12 weeks. Visual acuity varied from 1/60 to 6/6 on Snellen chart. A detailed ophthalmic evaluation, radio imaging and neuroimaging were done as needed on patients. FFA confirmed disc leakage, subretinal pooling of dye in posterior pole and pin point leaks in three cases. The fourth case revealed dilated capillaries, pin point leaks outside zone of hyperfluorescence and presence of leopard spots. USG B-scan in same case showed choroidal thickening and an oval hypointense juxtapapillary lesion. OCT-macula revealed a convex retinal profile, thickening of retinal pigment epithelium choriocapillaries complex, multiple subretinal low reflective areas consisting with serous neurosensory detachment and hyper reflective spots in inner retinal areas consistent with findings suggestive of metastasis. All four patients presented in acute uveitic stage. Barring one patient, three patients had bilateral disease. Incomplete VKH disease was diagnosed in three cases. Metastatic intraocular carcinoma with multiorgan involvement with primary in cervix was diagnosed in one case. Two cases of VKH disease were in remission having responded well to oral steroids and immunosuppressive therapy. One case passed to chronic stage with visual deterioration. One case with multi-organ metastasis went on to receive chemotherapy, brachytherapy, whole body and pelvic radiation. Conclusions: VKH disease has variable presentation and a high degree of suspicion is needed to differentiate it from similar occurring malignant and non-malignant intraocular inflammation. Early staging of VKH disease helps in planning adequate treatment leading to greater improvement in disease outcome and simultaneously preventing progression to chronic stage.

Keywords: VKHD, Adolescent, Uveitis, Tinnitus, Revised Diagnostic Criteria, FFA, Immunosuppression, Choroid, Metastasis

1. Introduction

Vogt-Koyanagi-Harada (VKH) disease is a bilateral granulomatous uveitis often associated with exudative retinal detachment and with extraocular manifestations, such as pleocytosis in the cerebrospinal fluid and in some cases vitiligo,

poliosis, alopecia and dysacusis [1]. Revised Diagnostic criteria (RDC) given by first International VKH group in 1999 classifies VKH disease into complete, incomplete and probable on the basis of presence of ocular and extraocular features with emphasis on former for diagnosis of disease [2].

Table 1. Revised Diagnostic criteria for VKH [2].

Complete VKH: Criteria 1–5 must be present
Incomplete VKH: Criteria 1–3 and either 4 or 5 must be present
Probable VKH (isolated ocular disease): Criteria 1–3 must be present
1. No history of penetrating ocular trauma or surgery preceding the initial onset of uveitis
2. No clinical or laboratory evidence suggestive of other ocular disease entities
3. Bilateral ocular involvement (a or b must be met, depending on the stage of disease when the patient is examined)
a) Early manifestations of disease (1) Evidence of diffuse choroiditis (with or without anterior uveitis, vitreous inflammatory reaction, or optic disk hyperaemia) which may manifest as (a) focal areas of subretinal fluid, or (b) bullous serous retinal detachments
b) Late manifestations of disease (1) History suggestive of prior presence of early findings noted in 3a and either (2) or (3) below, or multiple signs from 3. (2) Ocular depigmentation: either (a) sunset glow fundus or (b) Sugiura's sign (3) Other ocular signs including (a) nummular chorioretinal depigmented scars, or (b) retinal pigment epithelium clumping and/or migration, or recurrent or chronic anterior uveitis
4. Neurological/auditory findings (may resolve by time of evaluation) a) Meningismus (malaise, fever, headache, nausea, abdominal pain, stiffness of the neck and back, or a combination of these factors); note that headache alone is not sufficient to meet the definition of meningismus b) Tinnitus c) Cerebrospinal fluid pleocytosis
5. Integumentary finding (not preceding onset of central nervous system or ocular disease) a) Alopecia, or b) Poliosis, or c) Vitiligo

2. Case Series Report

We present a series of four cases diagnosed with incomplete VKH disease (as per revised diagnostic criteria) in our hospital with variable clinical features described in detail (Table 1). Slit lamp examination confirmed panuveitis in all four cases with case one having granulomatous uveitis. Fundus photos depict both acute and recovery phases of case one to three. Acute phase showed presence of right eye splinter haemorrhages in case one (Figure 1, Figure 2) and both eyes optic disc swelling in case one (Figure 1, Figure 2), case four (Figure 24, Figure 25) and left eye in case three (Figure 16, Figure 17) along with disc hyperaemia in case two (Figure 9, Figure 10). Case three which initially presented with unilateral left eye disc swelling developed right eye optic disc swelling within one month of presentation in other eye (Figure 16, Figure 17, Figure 20, Figure 21). Severe serous retinal detachment involving posterior pole and periphery were seen in cases one (Figure 1, Figure 2) and four (Figure 24, Figure 25). Focal areas of subretinal fluid confined to posterior pole only were seen in case two (Figure 9, Figure 10) and three (Figure 17). On sixth month follow up case one presented with optic disc pallor with presence of retinal pigment epithelium clumping at macula and periphery, chorioretinal depigmentation scars along

with orange red glow fundus (Figure 5, Figure 6). Fundus fluorescein angiography (FFA) of case one (Figure 3, Figure 4) and four (Figure 26, Figure 27, Figure 28, Figure 29) showed both eyes diffuse optic nerve head leakage and large placoid areas of hyperfluorescence with pooling of dye in posterior pole and periphery. Case four (Figure 26, Figure 27, Figure 28) distinctively showed presence of point leakage outside pooling areas, dilated capillaries and leopard spots. Case two (Figure 11, Figure 12, Figure 13) and three (Figure 18, Figure 19) showed moderate disc leakage, few multifocal areas of pinpoint leakage involving posterior pole with late phase hyperfluorescence and minimal pooling of dye. Follow up FFA of case one showed peripapillary loss of retinal pigment epithelium with ring of hyperfluorescence, staining of depigmented chorioretinal peripheral scars and areas of pigment migration with minimal leakage (Figure 7, Figure 8). Acute and chronic phase colour photos of case one (Figure 1, Figure 2, Figure 5, Figure 6) depict the change in fundus picture over time. Acute and recovery phase colour photos of case two (Figure 9, Figure 10, Figure 14, Figure 15) depict the fundus change pre and post immunosuppressive therapy. Fundus photos of case three (Figure 16, Figure 17, Figure 20, Figure 21, Figure 22, Figure 23) depict the initial unilateral (left eye) disease, evolving to bilateral involvement and finally undergoing resolution.

Table 2. Patient profile, treatment with outcome details of four VKH disease and VKH like syndrome cases.

case	Clinical presentation				
	Age/Sex	Symptoms	Duration	BCVA	Slit lamp examination
1.	38/M	Blurred vision BE, Tinnitus	eight weeks	OD: 6/24 OS: 6/18 Follow up Va at six months OD: 6/60 OS: 6/36	Granulomatous anterior uveitis OU: vitritis and optic disc swelling OD: splinter haemorrhages on disc
2.	14/F	Blurred vision BE, hot flushes after swim	four weeks	OD 6/18 OS 6/9	Anterior uveitis cells two + Vitritis two+, Optic disc hyperemia, focal areas of subretinal fluid collection over posterior pole.

case	Clinical presentation				
	Age/Sex	Symptoms	Duration	BCVA	Slit lamp examination
3.	15/M	Inability to focus on fine tools, blurred vision OS tinnitus	four weeks	OD6/6 OS6/18	Anterior uveitis two+ Vitreitis two+, focal areas of subretinal fluid collection over posterior pole with OS optic disc swelling Anterior uveitis two+ OD and one+ OS OD vitritis three+, optic disc swelling with retinal detachment and dilated tortuous veins OS: vitritis one+, creamy white lesion seen at posterior pole, localised subretinal fluid involving posterior pole, disc margins blurred
4.	56/F	Eye pain, floaters and flashes, headache, breathlessness and weight loss	twelve weeks	OD 1/60 OS 6/24	

Table 2. Continued.

case	Clinical presentation			
	Investigation	Diagnosis	RX	Follow up
1.	FFA: OU multifocal pin point areas of leak, large placoid areas of hyperfluorescence, pooling of dye in subretinal space, optic disc staining FFA after six months follow up: stain with minimal leak from RPE clumps	OU VKHD incomplete	Oral steroids Cyclosporine three-five mgm/kg/bwt Dose steroids one mg/kg/bwt	Lost to follow up, on re-follow up after 6 months: chronic anterior uveitis with pale disc, peripapillary atrophy (ppa), RPE clumping/migration, sunset glow fundus
2.	FFA OD: delayed choroidal perfusion, multifocal areas of pin point leak, pooling of dye in subretinal space and disc staining OS: minimal pinpoint leak at posterior pole FFA: OS multifocal pin point areas of leak with pooling of dye within subretinal space.	OU VKHD incomplete	Oral steroids/Azathioprine Induction 25mgm bid	In remission at one year follow up.
3.	Optic nerve head staining OU FFA: pin point leaks outside pooling areas, dilated capillaries, leopard spots, optic disc leakage	OS VKHD incomplete	Oral steroid /Azathioprine Induction: 50 mgm bid	In remission at one year follow up.
4.	OCT OS: convex profile, thickening of RPE choriocapillaris complex, Hyperreflective spots in inner retinal layers, multiple subretinal low reflective areas consistent with serous neurosensory detachment USG-Bscan: hypointense oval juxta papillary lesion with Increased chorioretinal thickness.	choroidal metastasis (OU) Brain and lung metastasis	Extended field radiation therapy with chemotherapy /Cisplatin five cycles, brachytherapy	Patient died after four months of therapy

2.1. Case 1

A 38 year old North Indian male presented for the first time with history of tinnitus followed by bilateral decrease in vision of eight weeks duration. Best corrected visual acuity (BCVA) was 6/24 in the right eye (RE) and 6/18 in the left eye (LE). Intraocular pressure was 16 mmHg bilaterally. He had bilateral granulomatous anterior uveitis and minimal cells in anterior vitreous of each eye. Posterior segment examination showed presence of vitreous cells with presence of splinter haemorrhage over right disc along with bilateral disc swelling, bilateral serous retinal detachment and presence of retinal folds extending from disc involving macula of left eye (Figure 1, Figure 2). Fundus fluorescein angiography revealed blurred optic disc margins with late phase hyperfluorescence, large placoid areas of hyperfluorescence in periphery with adjacent pin point leaks, large pooling of dye in subretinal space and juxtapapillary area (Figure 3, Figure 4). Patient was diagnosed with VKH disease and was started on high dose oral corticosteroid and immunosuppressive therapy (Tablet methotrexate 25 milligram loading and thereafter 17.5 mgm single dose once weekly). He followed up in the clinic for one month and was thereafter lost to follow up. He presented again at six months with BCVA of 6/60 in RE and 6/24 in LE with findings of chronic anterior uveitis, disc pallor, retinal pigment

epithelial clumping, nummular chorioretinal depigmentation scar and sunset glow fundus (Figure 5, Figure 6). FFA showed peripapillary loss of retinal pigment epithelium which appeared as ring of hyperfluorescence along with staining with leakage from peripheral depigmentation areas and areas of pigment migration (Figure 7, Figure 8). His diagnosis was confirmed as late stage (Table 2) of VKH disease and he was restarted on intensive topical steroids, cyclosporine (3-5mg/kg/day) and oral corticosteroids. He received oral corticosteroids for 12 weeks and induction of cyclosporine at 180 mg twice daily with maintenance at 100 milligram twice daily for 13 months. He has been asymptomatic for last 6 months with final visual recovery in RE 6/24p and LE 6/12. He continues to have colour and contrast sensitivity issues.

2.2. Case 2

A 14 year old dark skinned girl from Eastern part of India presented with distinct hot flushes, abdominal cramps and decrease in bilateral vision of four weeks duration. She was an amateur swimmer. Her BCVA in RE was 6/9 and LE was 6/18. Her IOP was 18 mmHg bilaterally. Anterior segment examination showed bilateral two plus cells in anterior chamber. Posterior segment examination of both eyes revealed two plus cells in posterior vitreous, bilateral disc hyperemia and focal areas of subretinal fluid collection over posterior

pole with choroidal and retinal folds (Figure 9, Figure 10). FFA of RE revealed optic disc staining with confluence of pin point leaks and pooling of dye within subretinal space involving macula (Figure 11, Figure 12). LE revealed few pin point leaks involving foveal avascular zone (Figure 13). She was diagnosed as bilateral VKH disease, with asymmetrical fundus picture presentation. She responded well to oral corticosteroids and immune suppressive therapy and was in remission at one year follow up. She received oral corticosteroids for 8 weeks (1 milligram/kilogram body weight). Induction for azathioprine was 50 milligrams twice daily and maintenance was 50 milligrams once daily for 12 months. Her BCVA returned to 6/6 in both eyes and her fundus picture (Figure 14, Figure 15) taken four months after starting immunosuppressive therapy revealed normal disc and posterior pole with complete resolution of subretinal fluid.

2.3. Case 3

A 15 old year young boy working at mechanical repair shop complained of inability to focus on fine tools along with bilateral decrease in vision of four weeks duration. His BCVA was RE 6/6 and LE 6/18. His IOP was 14 mmHg in both eyes. Anterior segment revealed two plus cells in LE anterior chamber. Posterior segment revealed LE scattered vitreous cells with RE disc hyperemia and LE disc swelling with serous macula detachment (Figure 16, Figure 17). FFA of BE revealed disc staining with LE revealing distinct pin point leaks, large placoid area of hyperfluorescence and pooling of dye with in macula in the late phase (Figure 18, Figure 19). B-scan ultrasonography showed choroidal thickening with serous retinal detachment with absence of bilateral T sign. He was diagnosed as case of unilateral VKHD and started on oral steroids. He complained of defective vision in RE one month from onset in left eye. Fundus picture revealed distinct RE disc hyperemia with blurred margins (Figure 20, Figure 21). He was diagnosed as case of VKHD with delayed fellow eye involvement. Immune suppressive therapy was added to the ongoing oral steroids. Follow up revealed resolution of optic disc swelling and posterior pole serous retinal detachment responding well to treatment (Figure 22, Figure 23). He received oral corticosteroids for 10 weeks. Induction for azathioprine was 50 milligrams twice daily and maintenance at one year was 50 milligrams once daily. He has stayed asymptomatic for last 7 months. His final bilateral BCVA was 6/6.

2.4. Case 4

A 56 year old lady presented with eye pain, bilateral floaters and flashes, headache, breathlessness and with history of weight loss over 12 weeks duration with worsening of symptoms. She gave history of having visited multiple physician over this time period. Her BCVA in RE was 1/60 and LE was 6/24. Her IOP were 17 mmHg both eyes. Anterior segment revealed three plus cells in RE and one plus cells in LE. Her posterior segment revealed two plus vitreous cells in both eyes. RE retina had a yellow glow and revealed optic disc oedema with loss of details, diffuse bullous retinal detachment

and dilated tortuous venous tree (Figure 24). Her LE revealed a hyperaemic disc, presence of creamy white deep-seated lesions in posterior pole along with bullous retinal detachment (Figure 25). FFA of RE revealed disc leakage with diffuse leakage seen from four retinal quadrants along with active vascular leak (Figure 26). Retinal periphery showed areas of patchy hyperfluorescence with confluent pin point leak and dilated capillaries (Figure 27). Also seen were round lesions with peripheral dark spots constituting leopard-spot pattern (Figure 28). Her LE revealed optic disc leakage and patchy leakage relating to areas denoted by creamy white lesion (Figure 29). B-scan ultrasonography showed choroidal thickening and an oval hypointense lesion (Figure 30). OCT-macula revealed a convex retinal profile, thickening of retinal pigment epithelium choriocapillaries complex, multiple subretinal low reflective areas consisting with serous neurosensory detachment and hyper reflective spots in inner retinal areas (Figure 31). Though the patient had been diagnosed as a case of VKH disease, her presenting symptoms along with poor general health and fundus with imaging results, drew our suspicion to rule out presence of malignancy. An oncologist opinion was sought where an MRI brain and CT with contrast were advised. CT with contrast of lung showed multiple hyperintense lesion suggestive of metastasis (Figure 32). Metastatic lesions in lung were also well demarcated with post contrast enhancement (Figure 33). T2 contrast on MRI of brain revealed multiple iso to hypointense foci suggestive of metastasis surrounded by oedema (Figure 34). As eye disease was bilateral and multifocal, she was advised chemotherapy. She underwent extended field radiation therapy followed by five cycles of chemotherapy with cisplatin 50 milligram/m² followed by ovoid intracavitary brachytherapy. She died four months after her first presentation in eye clinic.

3. Discussion

VKHD tends to affect more pigmented races and is mainly seen in people of Asian, Hispanic, Middle Eastern and Asian Indians [1, 3]. Incidence of VKHD in Japan accounts for 6.7% of all uveitis referral [4]. Incidence of VKH in an institutional based study in north east India was 2.2% of all uveitis referrals [5]. Women may be more frequently affected than men between second to fifth decade of life though Japanese studies have differed and the disease is also visible in children [1, 3, 6]. Our four patients were all of Asian descent, aged between 14-56 years, equal gender distribution with three having bilateral and one unilateral presentation. VKHD is commonly bilateral though unilateral cases or delayed involvement of other eye can occur rarely as was seen in case three [7]. Similar atypical unilateral presentation have been reported previously in a young boy aged 7 years with unilateral VKH disease who showed contralateral eye findings of thickening of choroid on B-scan ultrasonography [6]. In another atypical presentation a 6 year old Hispanic boy presented with high intraocular pressure, cataracts, bilateral granulomatous panuveitis and hypopigmented patches over mid-lumbosacral back. A biopsy for the lesions showed low melanocyte count

and mild lymphocytic infiltrate confirming the disease [8]. Though VKH disease is typically bilateral, unilateral delayed presentations may be seen. Also cutaneous lesions may present in unusual sites requiring a thorough examination. Unusual presentation as Uhthoff's phenomenon presenting as hot flushes after exercise and hot swim was seen in case two along with presence of panuveitis needing further evaluation. A normal MRI brain ruled out the possibility of underlying neurological disorder of multiple sclerosis [9]. Smith et al reported the presence of neurological disease to the extent of 7.9% in a large series of patients with uveitis in whom 1.1% cases were of VKH disease and 1.0% of multiple sclerosis [10]. In a study by Reiff et al to assess the long term safety and efficacy of disease-modifying antirheumatic drugs (DMARDs) and biologics for treatment of paediatric and adolescent patients with pars planitis (PP), panuveitis (PU) and VKHD, they found 98% of patients required additional DMARDs and 73% required therapy with biologics. At the end of study 35% patients across all groups had significant visual loss or were blind. They concluded that as all three groups involve a high risk of permanent visual loss they should be managed by skilled rheumatologist early and aggressively [11]. In another study by Albaroudi et al on paediatric VKHD, they concluded that life expectancy justifies early initiation of immunosuppressive or even biological therapy to achieve better steroid sparing and most importantly preserve visual function [12]. Hence it is imperative that all suspicious cases should be investigated to rule out simillar occurring inflammatory and noninflammatory diseases. The above two cases (Case 2 and 3) depict the variability of presentation of VKH disease seen in children making us aware of the fact that VKH disease may have more modes of presentation then documented and early treatment carries favourable outcome. Case one revisited with presence of bilateral disc palor along with presence of peripapillary atrophy and sunset glow fundus strongly indicative of chronic disease where immunosuppressive treatment had been discontinued. Jap et al have reported the correlation between the development and extent of peripapillary atrophy being largely determined by amount and timing of immunosuppressant therapy [13]. Recent studies support the fact that first line use of corticosteroids in combination with immunosuppressive agents decreases the late complications and recurrence of VKH disease, promising better outcome of long term vision and desirable control over tapering of oral steroids [7, 14, 15] as seen in case one which received and responded well to cyclosporine an immunosuppressive agent in chronic phase of disease [15]. Other immunosuppressive agents as mycophenolate mofetil (MMF) have been reported to show great results when used in combination with systemic corticosteroids in patients with initial-onset acute VKH disease thereby preventing progression to chronic recurrent granulomatous inflammation and development of sunset glow fundus [16]. Herbot Jr et al have mentioned regarding presence of substantial window of opportunity in initial onset acute VKD disease. They were of the view that timely and adequate treatment lead to greater improvement in disease outcome and simultaneously

prevented chronic evolution and sunset glow fundus [17]. It has been documented that chronic recurrent VKH disease presentations with development of complications and sunset glow fundus are associated with worse retinal sensitivity outcome [18]. Hence we believe that it is extremely important to separate and clearly establish the type of VKH disease into two separate entities of initial onset acute or chronic refractory so as to plan management and simultaneously be aware of potential refractoriness or expected clinical outcomes. VKH disease may also present as uveitis masquerade syndrome as seen in case four. The term masquerade was first used in 1967, is now applied to range of disorders of intraocular inflammation which may be malignant or non-malignant [19]. In a study at National Eye Institute (NEI), Bethesda, neoplastic masquerade syndromes were found to be prevalent in 2.5% of their patients, their average age at presentation being 57 years, 48% being female and 9% of their patients with masquerade syndrome were African-Americans. The most commonly identified neoplasm among masquerade syndrome were primary intraocular/vitreoretinal lymphoma, chronic lymphocytic leukaemia, human T-lymphotropic virus T cell leukaemia and non-Hodgkin's lymphoma [20]. Among the primary cancers with intraocular metastasis, breast and lung comprise for two thirds of cases. Among the other sites for primary, carcinoma of cervix has also been documented which also happens to be the most common gynecologic malignancy and also the fourth most common type of cancer in women [21]. In literature 13 cases of documented cervical carcinoma metastasizing to the eye have been reported, spreading via local extension, lymphatics and haematogenous route [22]. Metastasis tends to affect the choroid maximally, with post equatorial site being most common, hence patients tend to present early with blurring of vision as seen in case four. Most patients with choroidal metastasis are known to have systemic carcinoma and in 50% cases primary site is never found [23]. Presence of choroidal metastasis which frequently occur in late stages of disseminated disease is considered a poor prognostic sign.

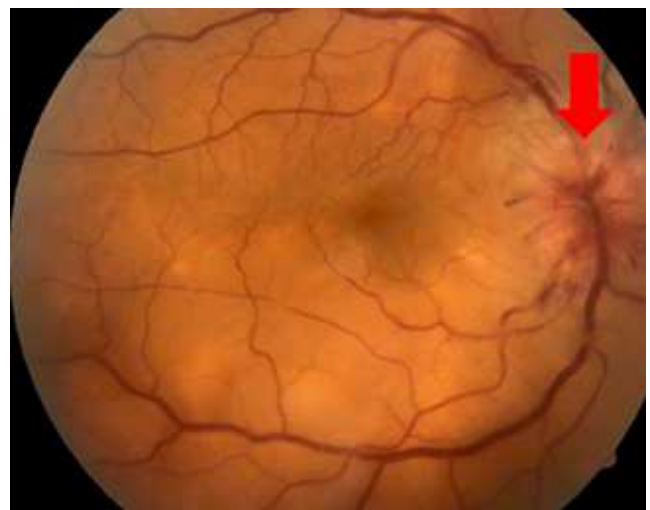


Figure 1. Fundus photo right eye depicting optic disc swelling with splinter haemorrhage (red arrow) with bullous serous retinal detachment.

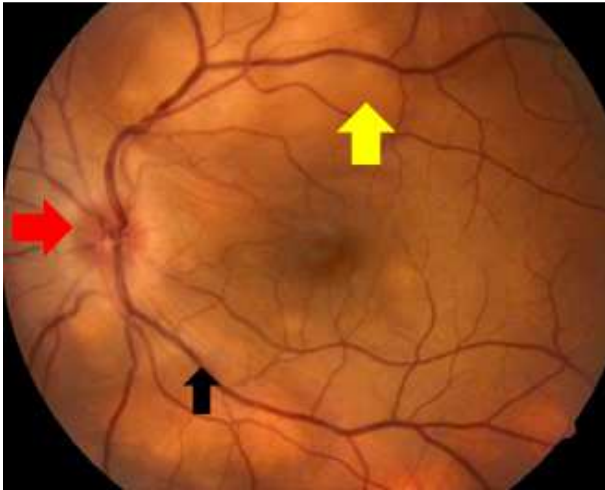


Figure 2. Fundus photo left eye depicting optic disc swelling (solid red arrow) with retinal folds (black arrow) with bullous serous retinal detachment (solid yellow arrow).

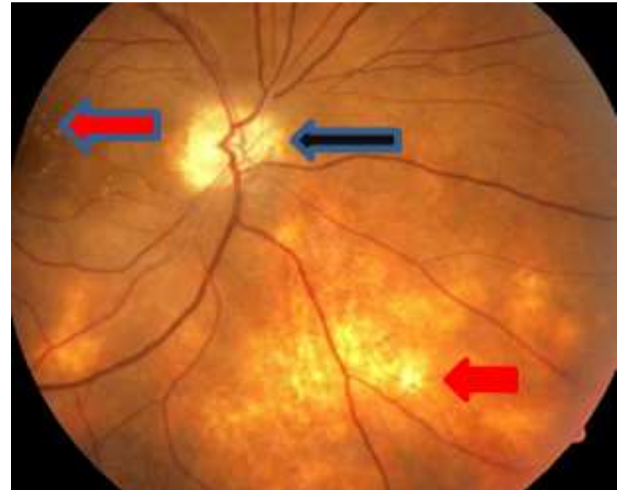


Figure 5. Fundus photo right eye shows optic disc pallor (black arrow) retinal pigment epithelium clumping in macula and periphery (horizontal blue red arrow) and "sunset glow fundus" (solid red arrow).

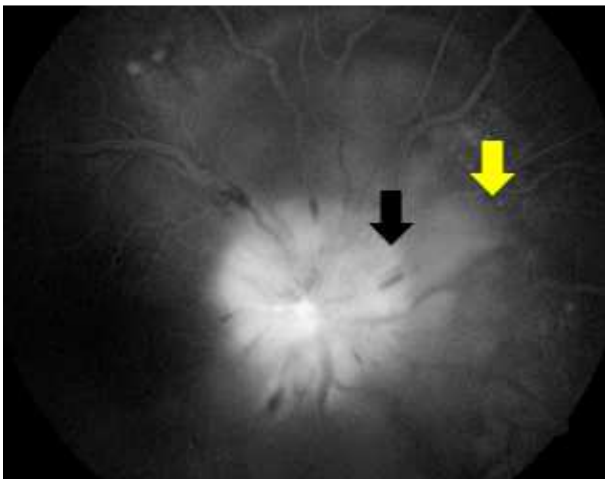


Figure 3. FFA right eye shows blurred optic disc details with staining (black arrow), large placoid areas of hyperfluorescence with adjacent pin point leaks, large pooling of dye in posterior pole and juxtapapillary area (yellow arrow).

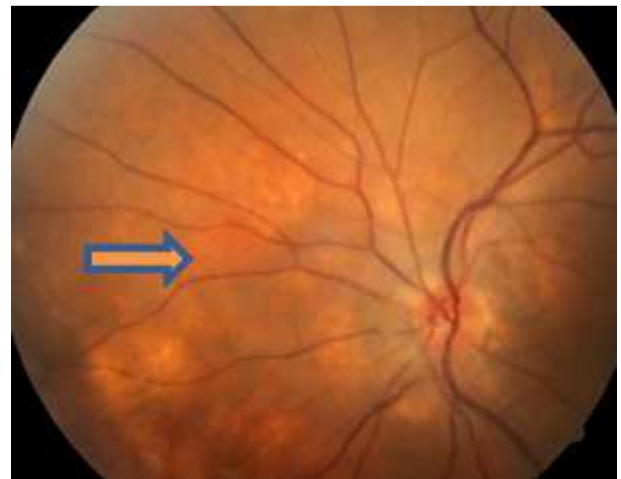


Figure 6. Fundus photo left eye shows optic disc hyperaemia with sunset glow fundus (blue orange arrow).

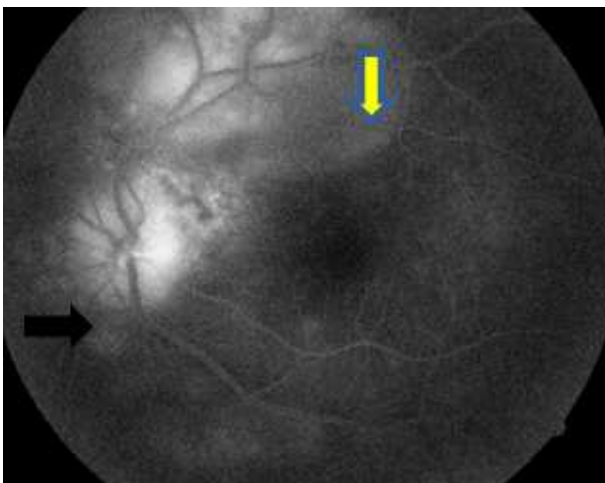


Figure 4. FFA left eye shows staining of optic disc (black arrow) with large areas of hyperfluorescence and pooling of dye in subretinal space (yellow arrow).

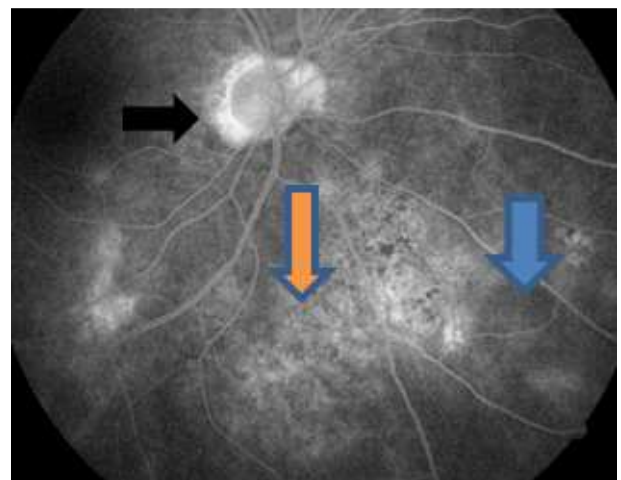


Figure 7. FFA right eye shows peripapillary loss of RPE appearing as ring of hyperfluorescence (black arrow), active leaks seen in periphery (blue arrow), staining of chorioretinal depigmented scars and areas of migration (vertical blue orange arrow).

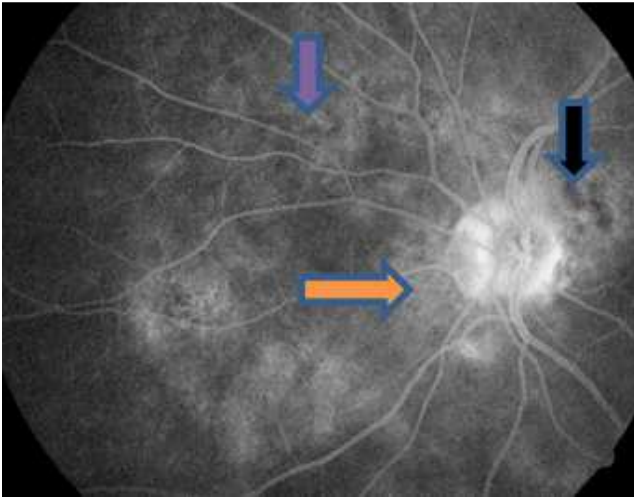


Figure 8. FFA left eye shows: staining around disc (horizontal blue orange arrow), active leaks in periphery (vertical blue arrow) and distinct chorioretinal depigmentation scar seen nasal to disc (blue black arrow).

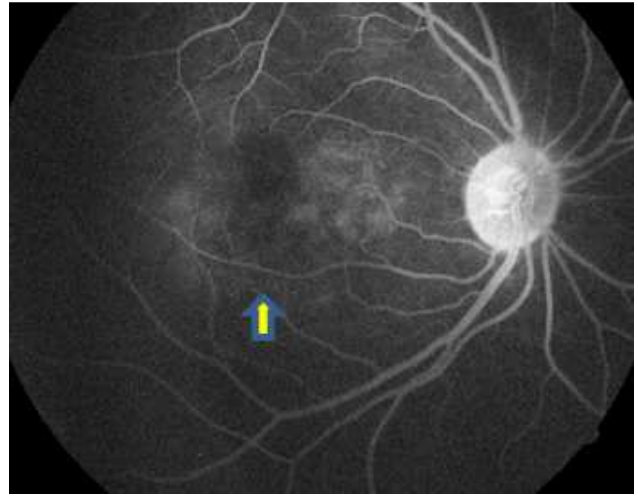


Figure 11. FFA right eye show focal areas of choroidal fluorescence (vertical blue yellow arrow).

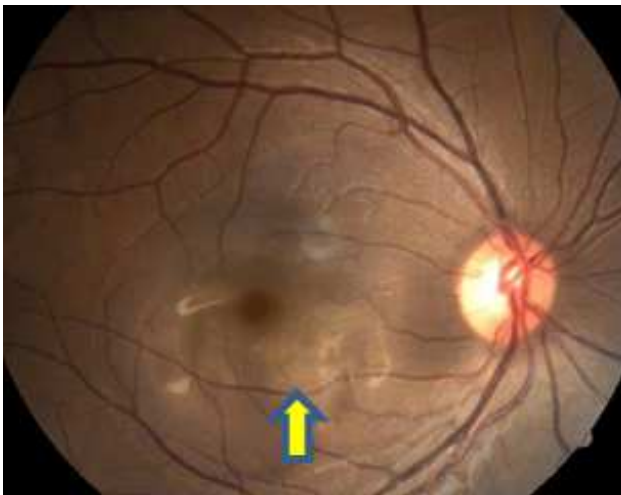


Figure 9. Fundus photo right eye shows disc hyperemia and focal areas of subretinal fluid (yellow blue arrow).

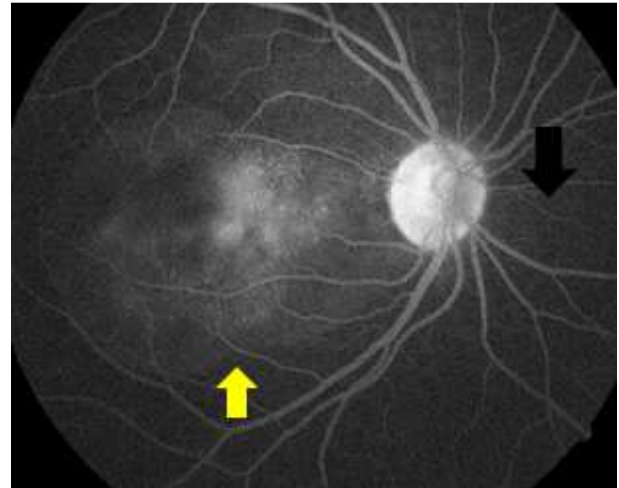


Figure 12. FFA right eye shows optic disc staining (black arrow) with confluence of pin point leaks and pooling of dye within subretinal space (yellow arrows).

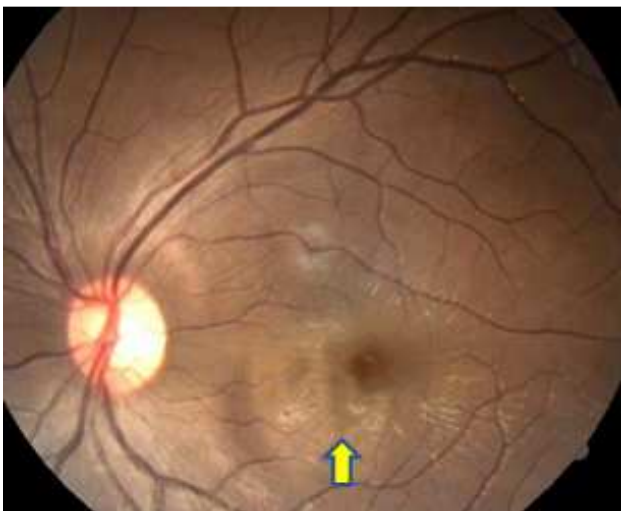


Figure 10. Fundus photo left eye show disc hyperaemia and focal areas of subretinal fluid (vertical yellow blue arrow).

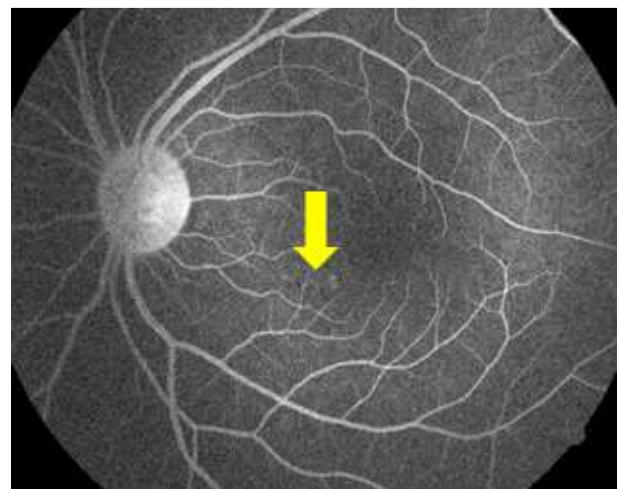


Figure 13. FFA left eye shows optic disc stain with minimal pin point leak at FAZ (yellow arrow).

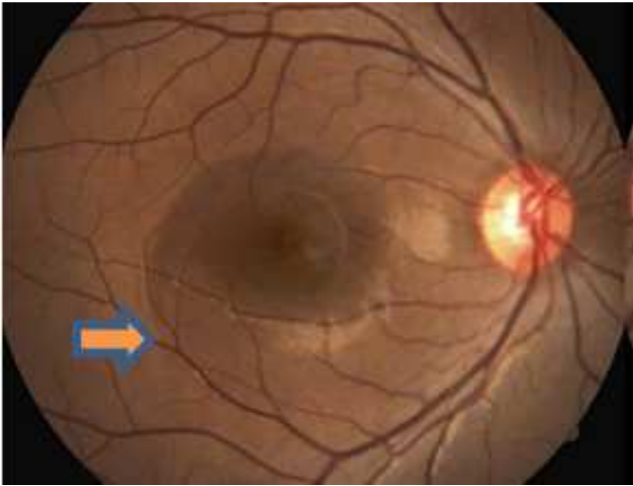


Figure 14. Fundus photo shows resolution of subretinal fluid in right eye (blue orange arrow) after 4 months of immunosuppressive therapy (In comparison to Figure 9 with active disease shown with yellow blue arrow).

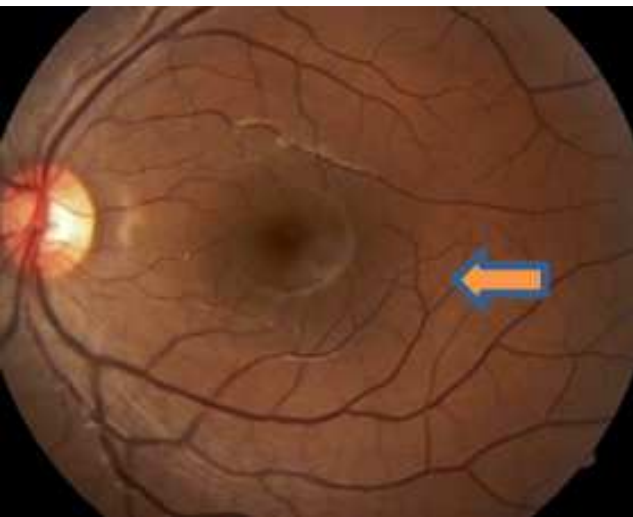


Figure 15. Fundus photo shows resolution of subretinal fluid in left eye (blue orange arrow) after 4 months of immunosuppressive therapy (In comparison to Figure 10 with active disease depicted by horizontal blue yellow arrow).

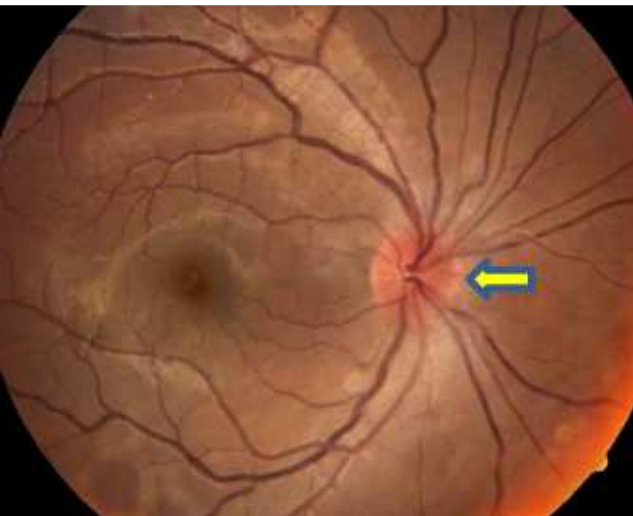


Figure 16. Fundus photo right eye shows optic disc hyperaemia (yellow arrow).

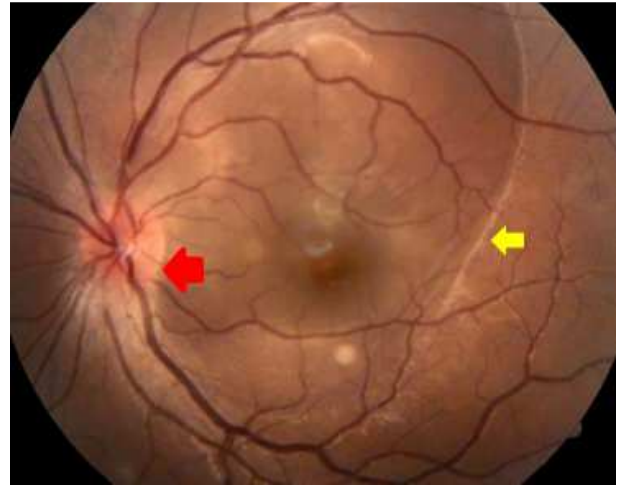


Figure 17. Fundus photo left eye shows optic disc swelling (red arrow) and bullous serous retinal detachment at posterior pole (yellow arrow).

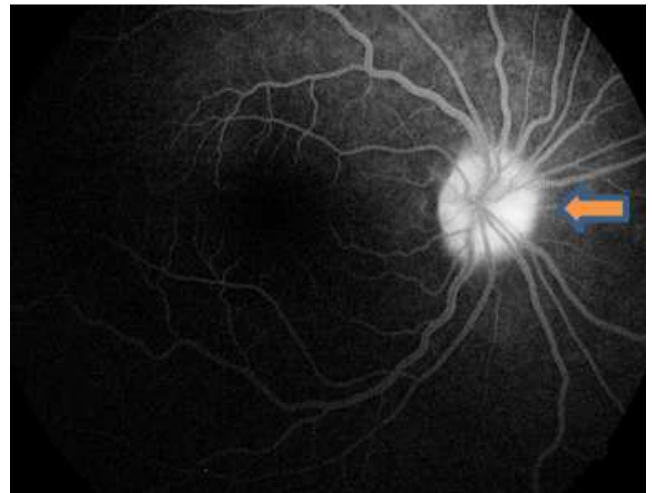


Figure 18. FFA right eye shows disc staining (horizontal blue orange arrow).

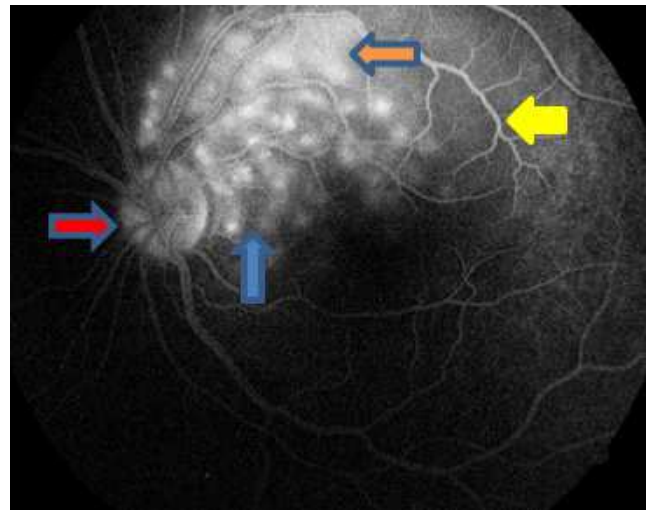


Figure 19. FFA left eye shows optic disc staining (red blue arrow), distinct pin point leaks (solid blue arrow), large placoid area of hyperfluorescence (horizontal orange blue arrow) and pooling of dye within subretinal fluid in late phase (solid yellow arrow).

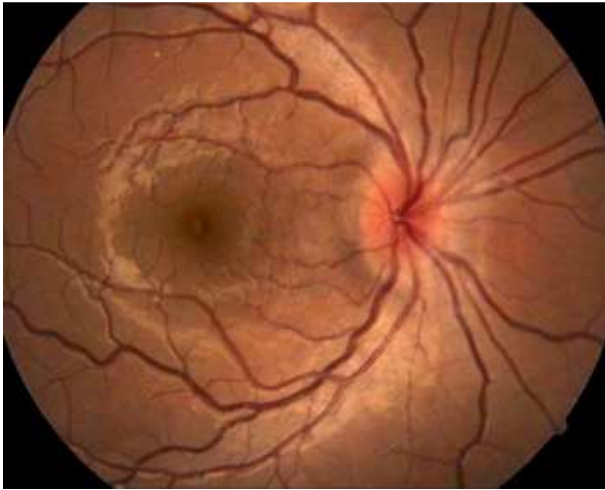


Figure 20. Fundus picture of patient 30 days after 1st visit revealing delayed involvement of right eye with disc oedema in asymmetrical VKH disease (unilateral disease as seen in Figure 16).

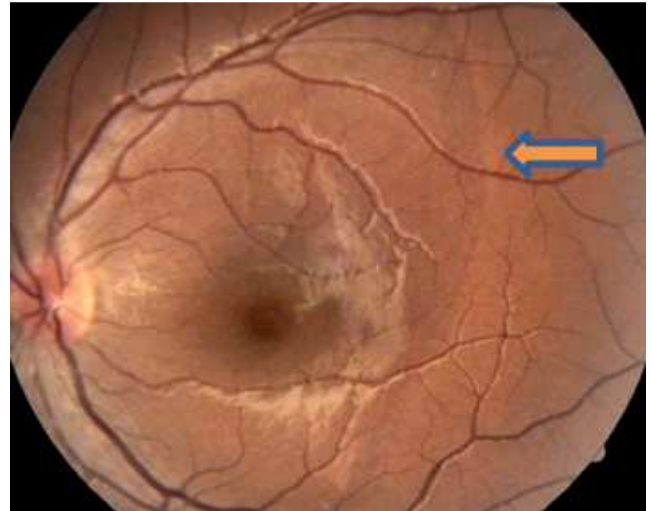


Figure 23. Fundus Image of patient after immunosuppressive therapy with total resolution of subretinal fluid with retention of fluid demarcation line seen in left eye (blue orange arrow) and resolution of disc oedema. (Comparison seen in Figure 21).

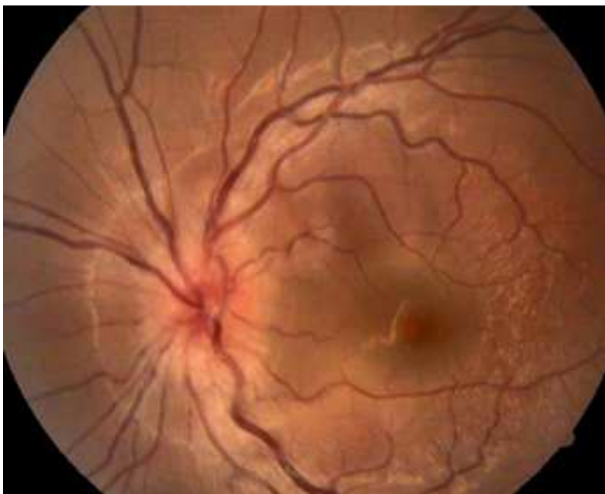

Figure 21. Fundus picture of patient's Left eye 30 days after 1st visit showing increase in disc oedema with increased posterior pole subretinal fluid confirming progressive involvement of left eye. (Fundus photo seen in comparison in Figure 17).

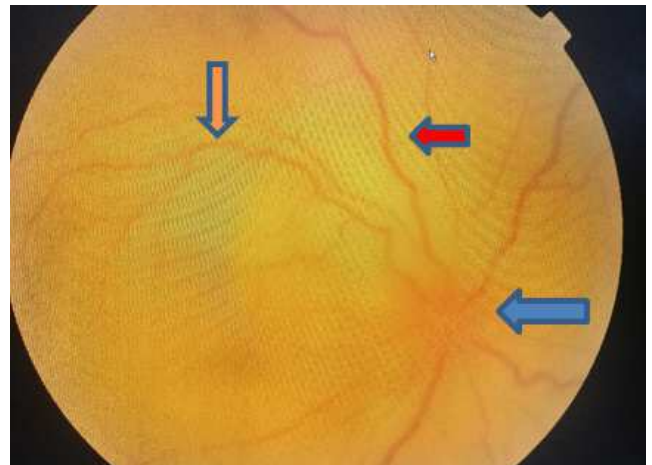


Figure 24. Right Eye optic disc oedema (solid blue arrow) with loss of details, diffuse bullous retinal detachment (red blue arrow) and dilated tortuous venous tree (vertical orange blue arrow).

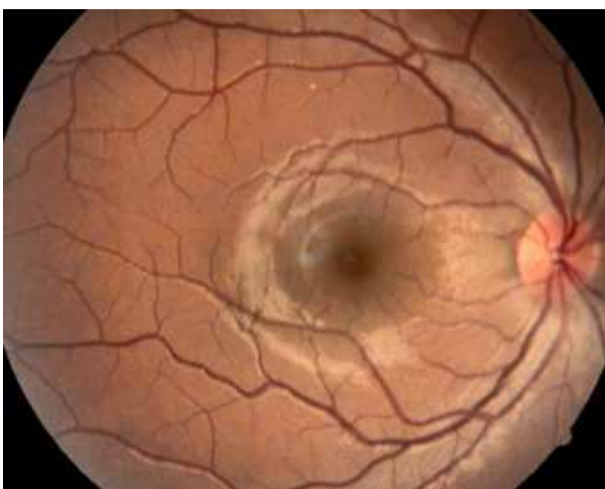


Figure 22. Fundus image of right eye of patient after immunosuppressive therapy with complete resolution of subretinal fluid. (Fundus photo comparison as seen in Figure 20).

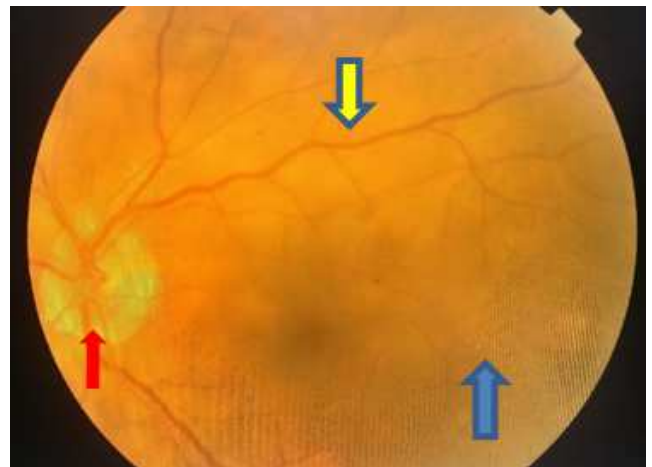


Figure 25. Fundus photo left eye shows hyperaemic disc (red arrow), creamy white deep-seated lesions (vertical yellow blue arrow) in posterior pole along with bullous retinal detachment (solid blue arrow).

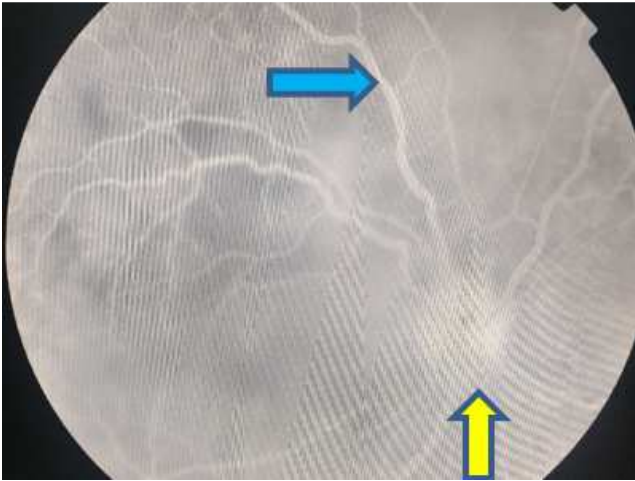


Figure 26. FFA right eye shows right eye optic disc leakage (yellow arrow) with loss of details and diffuse retinal leakage (blue arrow).

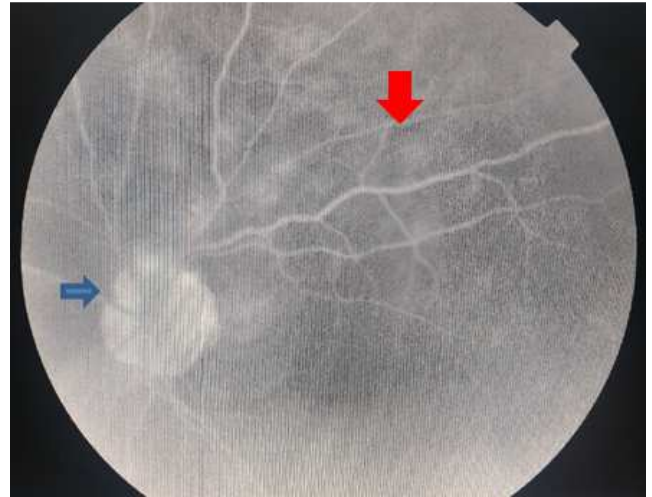


Figure 29. FFA left eye shows optic disc (blue arrows) and patchy (red arrows) leakage relating to areas denoted by creamy white lesion (Figure 25).

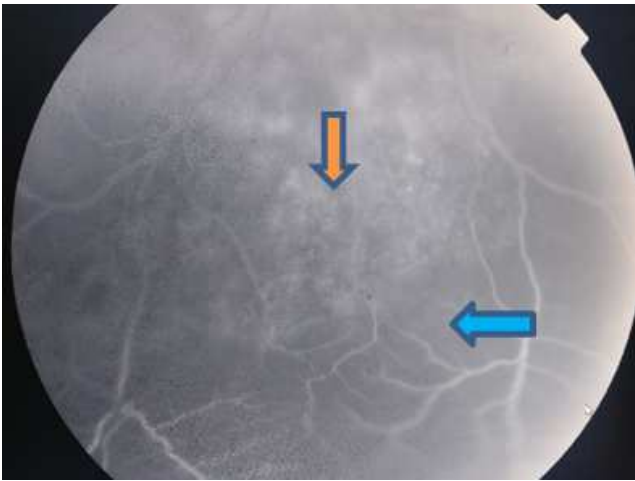


Figure 27. FFA right eye shows point leakage outside zone of patchy hyperfluorescence (vertical blue orange arrow) and dilated capillaries (blue arrow) in inferior periphery.

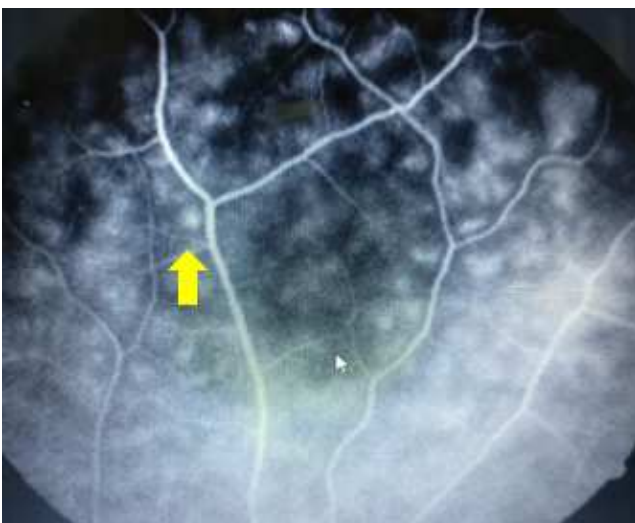


Figure 28. FFA right eye depicts round lesion with peripheral dark spots constituting leopard-spot pattern (yellow arrows).

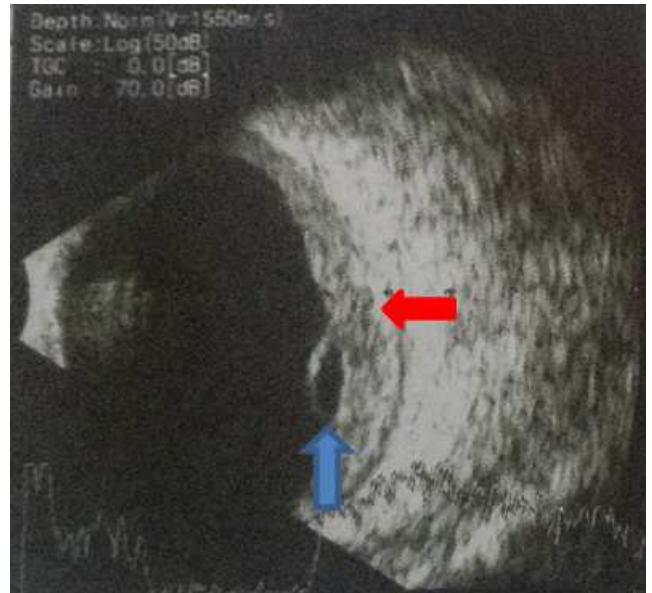

Figure 30. Shows B scan right eye with oval hypointense juxta papillary lesion (blue arrows) with increased chorioretinal thickness (red arrows).

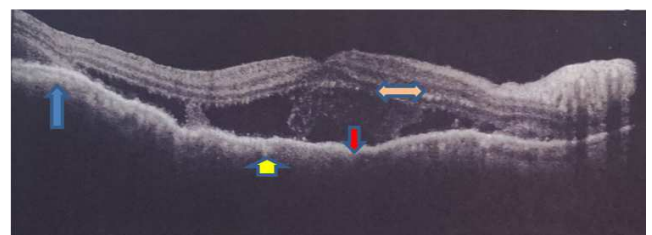


Figure 31. OCT OS shows (a) convex retinal profile (blue vertical up arrow) (b) thickening of Retinal pigment epithelium Choriocapillaris complex (yellow vertical up arrow) (c) multiple subretinal low reflective areas consisting with serous neurosensory detachment (red down arrow) (d) hyper reflective spots in inner retinal areas (horizontal blue orange arrow).

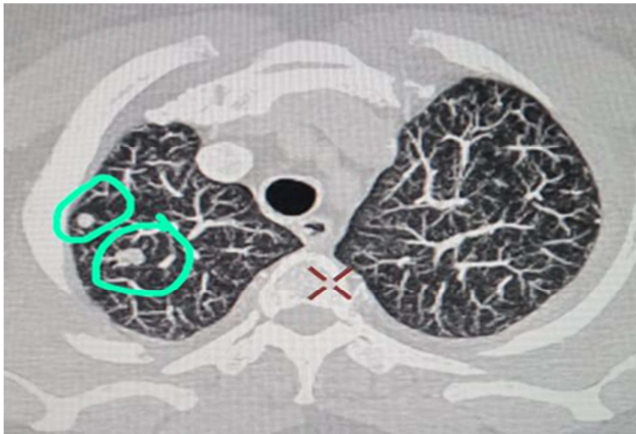

Figure 32. Computerized Tomography scan of lung with contrast shows multiple hyperintense lesion (marked by green circle) suggestive of metastasis.

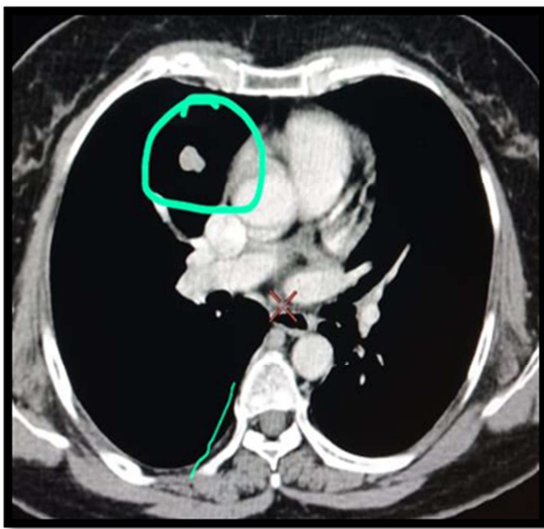


Figure 33. Lung metastatic lesion (green circle) with post contrast enhancement on computerized tomography scan.

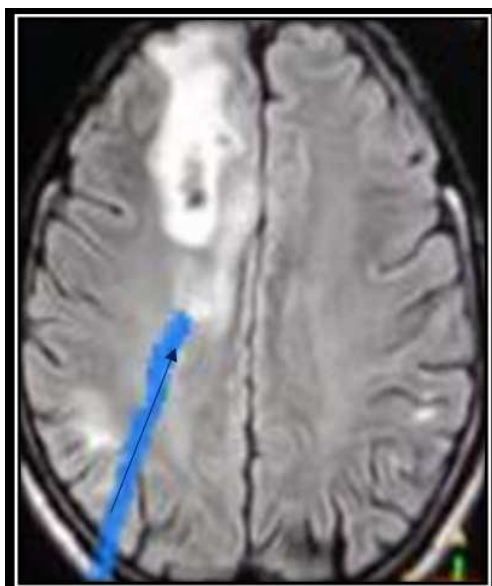

Figure 34. Iso-Hypointense foci in white matter (marked blue arrow) with surrounding oedema suggestive of metastasis seen on T2 contrast of Magnetic Resonance Imaging involving brain.

4. Conclusion

VKH disease involve variable age groups and may present differently. Early staging of VKH disease helps in planning adequate treatment leading to greater improvement in disease outcome and simultaneously preventing progression to chronic stage. Changing trends have shown greater availability and use of newer immunosuppressants in treatment of VKH disease thereby bringing greater stability to results.

We must also remember that due to its overlapping symptoms and ocular presentation a high index of suspicion is crucial in diagnosing VKHD and differentiating it from similar occurring non-malignant and malignant intraocular inflammation and hence the management of the disease.

Acknowledgements

We wish to extend thanks to Dr. Andrew Chang for his guidance on VKH disease in initial years of learning which formed the basis for this research and paper.

References

- [1] Moorthy RS, Inomata H, Rao NA. Vogt –Koyanagi-Harada syndrome. *Surv Ophthalmol* 1995; 39: 265-92. <https://pubmed.ncbi.nlm.nih.gov/7725227/>
- [2] Read RW, Holland GN, Rao NA, Tabbara KF, Ohno S, Arrellanes-Garcia L, et al. Revised diagnostic criteria for Vogt–Koyanagi–Harada Disease: report of an international committee on nomenclature. *Am J Ophthalmol*. 2001; 131: 647–652. <https://pubmed.ncbi.nlm.nih.gov/11336942/>
- [3] Shimizu K. Haradas, Behcets, Vogt-Koyanagi-syndromes: are they clinical entities? *Trans Am Acad Ophthalmol Otolaryngol* 1973; 77: 281-90. <https://pubmed.ncbi.nlm.nih.gov/4731490/>
- [4] Goto H, Mochizuki M, Yamaki K, Kotake S, Usui M, Ohno S. Epidemiological survey of intraocular inflammation in Japan. *Jpn J Ophthalmol*. 2007; 51 (1): 41-44. <https://pubmed.ncbi.nlm.nih.gov/17295139/>
- [5] Das D, Bhattacharjee H, Bhattacharyya PK, Jain L, Panicker MJ, Das K, et al. Indian journal of ophthalmology. Patterns of uveitis in north east India: A tertiary eye care centre study. 2009; 57 (2): 144-6. <https://pubmed.ncbi.nlm.nih.gov/19237790/>
- [6] Forster DJ, Green RL, Rao NA. Unilateral manifestation of Vogt-Koyanagi-Harada syndrome in a 7 year old child. *Am J Ophthalmol* 1991; 111: 380-2. <https://pubmed.ncbi.nlm.nih.gov/2000916/>
- [7] Cunningham ET, Jr, Rathinam SR, Tugal-Tutkun I, Muccioli C, Zierhut M. Vogt Koyanagi-Harada disease. *Ocul Immunol Inflamm*. 2014; 22: 249-252. <https://pubmed.ncbi.nlm.nih.gov/25014114/>
- [8] Hernandez C, LePoole C, Tessler HH. Vogt-Koyanagi-Harada syndrome in a 6-year-old Hispanic boy. *Pediatr Dermatol*. 2012 Mar-Apr; 29 (2): 191-4. <https://pubmed.ncbi.nlm.nih.gov/21995870/>
- [9] Tsolaki F, Tagarakis GI, Karangelis D, Gogaki EG, Stojanovic N, Trantou V, et al. Uthoff phenomenon-a rare manifestation of a rare disease. *J Paediatric Child Health* 2011. Jun; 47 (6): 396. <https://pubmed.ncbi.nlm.nih.gov/21649754/>

- [10] Smith JR, Rosenbaum JT. Neurological concomitants of uveitis. *Br J Ophthalmol.* 2004; 88: 1498–1499. <https://pubmed.ncbi.nlm.nih.gov/15548797/>
- [11] Reiff A. Clinical Presentation, Management, and Long-Term Outcome of Pars Planitis, Panuveitis, and Vogt-Koyanagi-Harada Disease in Children and Adolescents. *Arthritis Care Res (Hoboken).* 2020 Nov; 72 (11): 1589-1596. <https://pubmed.ncbi.nlm.nih.gov/3144459/>
- [12] Albaroudi N, Tijani M, Boutimzine N, Cherkaoui O. Clinical and therapeutic features of pediatric Vogt-Koyanagi-Harada disease. *J Fr Ophtalmol.* 2020 May; 43 (5): 427-432. <https://pubmed.ncbi.nlm.nih.gov/32115269/>
- [13] Jap A, Luu CD, Yeo I, Chee SP. Correlation between peripapillary atrophy and corticosteroid therapy in patients with vogt-koyanagi-harada-disease. *Eye (Lond).* 2008 Feb; 22 (2): 240-5. <https://pubmed.ncbi.nlm.nih.gov/16980924/>
- [14] Paredes I, Ahmed M, Foster CS. Immunomodulatory therapy for Vogt-Koyanagi-Harada patients as first-line therapy. *Ocul Immunol Inflamm.* 2006; 14 (2): 87-90. <https://pubmed.ncbi.nlm.nih.gov/16597537/>
- [15] Cuchacovich M, Solanes F, Diaz G, Cermenati T, Avila S, Verdager J, et al. Comparison of clinical efficacy of two different immunosuppressive regimens in patients with chronic Vogt-Koyanagi-Harada disease. *Ocul Immunol Inflamm.* 2010; 18: 200-20 <https://pubmed.ncbi.nlm.nih.gov/20482399/>
- [16] Abu El-Asrar AM, Dosari M, Hemachandran S, Gikandi PW, Al-Muammar A. Mycophenolate mofetil combined with systemic corticosteroids prevents progression to chronic recurrent inflammation and development of 'sunset glow fundus' in initial-onset acute uveitis associated with Vogt-Koyanagi-Harada disease. *Acta Ophthalmol.* 2017 Feb; 95 (1): 85-90. <https://pubmed.ncbi.nlm.nih.gov/27535102/>
- [17] Herbolt CP Jr, Abu El Asrar AM, Takeuchi M, Pavésio CE, Couto C, Hedayatfar A, Maruyama K, Rao X, Silpa-Archa S, Somkijrungrroj T. Catching the therapeutic window of opportunity in early initial-onset Vogt-Koyanagi-Harada uveitis can cure the disease. *Int Ophthalmol.* 2019 Jun; 39 (6): 1419-1425. <https://pubmed.ncbi.nlm.nih.gov/29948499>
- [18] Abu El-Asrar AM, Al Mudhaiyan T, Al Najashi AA, Hemachandran S, Hariz R, Mousa A, Al-Muammar A. Chronic Recurrent Vogt-Koyanagi-Harada Disease and Development of 'Sunset Glow Fundus' Predict Worse Retinal Sensitivity. *Ocul Immunol Inflamm.* 2017 Aug; 25 (4): 475-485. <https://pubmed.ncbi.nlm.nih.gov/27003480/>
- [19] Saha S, Graham E. M. (2009) Masquerade Syndrome. In: *Uveitis and Immunological Disorders. Essentials in Ophthalmology.* Springer, Berlin, Heidelberg. pp: 97-115. https://link.springer.com/chapter/10.1007/978-3-540-69459-5_10
- [20] Grange LK, Kouchouk A, Dalal MD, Vitale S, Nussenblatt RB, Chan C et al. Neoplastic masquerade syndromes in patients with uveitis. *Am J Ophthalmol.* 2014; 157 (3): 526-31. <https://pubmed.ncbi.nlm.nih.gov/24211361/>
- [21] Uhrinak AN, Tierney KE, Duncan KL, Matsuo K. Intraocular metastasis from primary cervical cancer: A case report and review of literature. *Gynecol Oncol Rep.* 2015; 12: 61-63. <https://pubmed.ncbi.nlm.nih.gov/26076161/>
- [22] Nair AG, Asnani HT, Mehta VC, Mehta SV, Pathak RS. Metastatic adenocarcinoma of cervix presenting as choroidal mass: A case report and review of literature of cervical metastasis to the eye. *Indian J Ophthalmol.* 2015; 63 (8): 674-678. <https://pubmed.ncbi.nlm.nih.gov/26576527/>
- [23] Arepalli S, Kalki S, Shields CL. Choroidal metastasis: origin, features and therapy. *Indian J Ophthalmol.* 2015; 63 (2): 122-127. <https://pubmed.ncbi.nlm.nih.gov/25827542/>