

Case Report

A Rare Presentation of Bilateral Vogt-Koyanagi-Harada (VKH) Disease in a Patient with Unilateral Limbal Stem Cell Deficiency (LSCD) with Corneal Perforation

Shreesha Kumar Kodavoor^{1,*}, Soundarya Balajee², Ramamurthy Dandapani³,
Muralidhar Rajamani⁴, Thenarasun Seethalakshmi Asaithambi⁵

¹Cornea Services, The Eye Foundation, Coimbatore, India

²Cornea, Refractive and Cataract Surgery, The Eye Foundation, Coimbatore, India

³Refractive and Cataract Surgery, The Eye Foundation, Coimbatore, India

⁴Glaucoma, Neuro Ophthalmology, Paediatric Ophthalmology and Squint, The Eye Foundation, Coimbatore, India

⁵Vitreoretina Services, the Eye Foundation, Coimbatore, India

Email address:

eskay_03@rediffmail.com (S. K. Kodavoor), soundslikeme@gmail.com (S. Balajee), drramamurthy@theeyefoundation.com (R. Dandapani),
rajamanimurali@hotmail.com (M. Rajamani), arasun.then@gmail.com (T. S. Asaithambi)

*Corresponding author

To cite this article:

Shreesha Kumar Kodavoor, Soundarya Balajee, Ramamurthy Dandapani, Muralidhar Rajamani, Thenarasun Seethalakshmi Asaithambi. A Rare Presentation of Bilateral Vogt-Koyanagi-Harada (VKH) Disease in a Patient with Unilateral Limbal Stem Cell Deficiency (LSCD) with Corneal Perforation. *International Journal of Ophthalmology & Visual Science*. Vol. 6, No. 2, 2021, pp. 72-74.

doi: 10.11648/j.ijovs.20210602.12

Received: March 8, 2021; Accepted: March 30, 2021; Published: April 16, 2021

Abstract: Purpose-To report a rare presentation of Vogt-Koyanagi-Harada (VKH) disease in a 55 year old female patient with unilateral limbal stem cell deficiency (LSCD) with corneal perforation. Observations-Patient presented to the out patient department with recurrent episodes of watering, pain, redness in the left eye. Examination revealed LSCD with areas of pannus and infiltration. She was treated medically. Patient came back after a year with a corneal perforation in her left eye. The perforation was sealed using cyanoacrylate glue. Six weeks later, she presented with a drop in vision in both eyes. Optical Coherence Tomography (OCT) in both eyes showed multiple sub retinal fluid pockets and Fundus Fluorescein Angiography (FFA) revealed multiple pinpoint leakages typical of Harada disease. The patient was investigated for systemic associations, which were found to be normal. She was managed with tapering doses of oral steroids. OCT showed resolution of fluid pockets at one month. There was a good control of the disease, with no signs of recurrence at 6 months follow up. Conclusion-The clinical association between the two entities has not been published in literature till date. Further data or reports on such cases would help throw light on any possible association between LSCD and VKH disease.

Keywords: Vogt-Koyanagi Harada Disease, Limbal Stem Cell Deficiency, Corneal Perforation

1. Introduction

Vogt-Koyanagi-Harada (VKH) disease is a multiple system involving inflammatory granulomatous autoimmune condition which presents as panuveitis along with serous retinal detachments and diffuse choroidal edema. [1] It can be associated with cutaneous, neurological and inner ear manifestations due to the increased melanocyte density in

these organs. [2]

Limbal stem cell deficiency (LSCD) can be caused by congenital or acquired factors which lead to direct injury to the limbal stem cells or the limbal stem cell niche. [3] Common acquired etiologies include chemical/thermal burns, previous ocular surgeries, contact lens use, and ocular surface inflammatory diseases. [4-8]

This is a case report of a clinical presentation of VKH in a

patient with unilateral LSCD with no predisposing factors.

2. Case Report

55 year old female patient presented to our OPD with complaints of redness, pain and watering in the left eye for 1 week. Past history revealed similar recurrent episodes in the past for many years. She did not have any known systemic comorbidities and did not give any history of trauma/chemical injury. On examination her uncorrected visual acuity (UCVA) was 6/6 parts in the right eye and 6/15 in the left eye. Slit lamp examination showed normal anterior and posterior segment examination of the right eye. The left eye had a picture of total limbal stem cell deficiency (LSCD) with severe pannus extending from 3-9 o'clock positions associated with 2 dense infiltrates at 4 o'clock (3x2 mm) and 7 o'clock (2x1 mm) positions [Figure 1a]. The patient was started on topical antibiotics, steroids, cycloplegics and lubricants. On subsequent follow up after 20 days, her symptoms had reduced and the infiltrates were seen healing. Steroid tapering was advised after which she was lost to follow up.

She presented to our OPD again after a year with complaints of redness and pain in the left eye. Her visual acuity was 6/6 in the right eye and 6/24 in the left eye. Examination revealed normal findings in the right eye with a 1.5 mm corneal perforation and iris prolapse at 4 o'clock position in the left eye [Figure 1b]. She underwent iris tissue abscission and perforation closure with cyanoacrylate glue and bandage contact lens application. On post operative day 1, the perforation was well sealed with a formed anterior chamber [Figure 2a]. She was put on topical antibiotics and steroids (Loteprednol 0.5%). Follow up visit 1 month post operatively showed a quiet eye with sealed perforation [Figure 2b]. Visual acuity was 6/18 in the left eye. Evaluation for systemic collagen vascular disorders was done and was found to be normal.

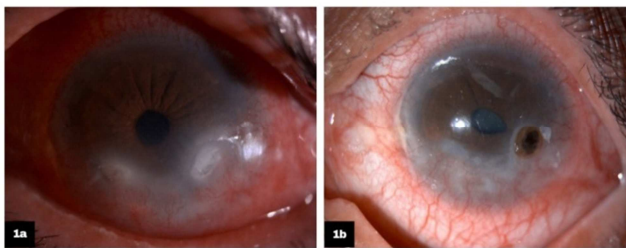


Figure 1. a-LSCD with inferior pannus and infiltration; b-Perforation with iris prolapse.

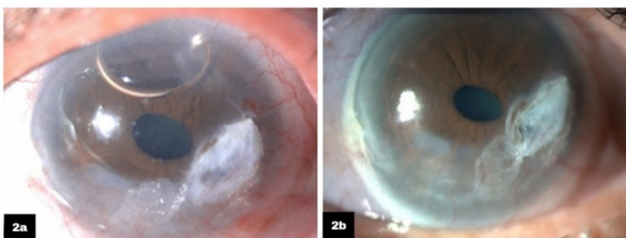


Figure 2. a-Post operative day 1-Perforation repair with tissue adhesive and BCL in situ; b-Post operative-1 month follow up.

She presented thirteen days later with complaints of blurring of vision in her right eye for two days. Her best corrected visual acuity (BCVA) was 6/60 in the right eye with a correction of +2.0 D and left eye was 6/18 with a correction of +2.25 DS and -3.5 D cyl @ 160 degrees. On slit lamp examination, anterior chamber was found to be shallow with a VH grading of 1 in right eye and 2 in the left eye. Patient underwent a YAG laser peripheral iridotomy in the right eye. Subsequently two days later dilated fundus examination of both eyes showed features of Harada disease with fluid pockets in the posterior pole. Both eyes Optical Coherence Tomography (OCT) showed multiple sub retinal fluid pockets [Figure 3a and 3b], while Fundus Fluorescein Angiography (FFA) showed multiple pinpoint leakages typical of Harada disease [Figure 3c]. She did not have any other systemic features of VKH syndrome.

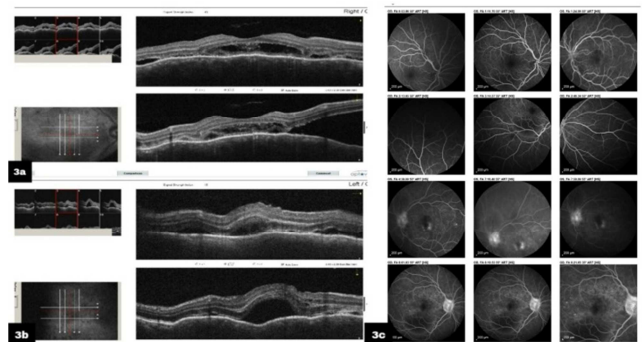

Figure 3. a and b-OCT image of right eye and left eye respectively showing multiple sub retinal fluid pockets; c-FFA images showing multiple pinpoint leakage points, typical of Harada disease.

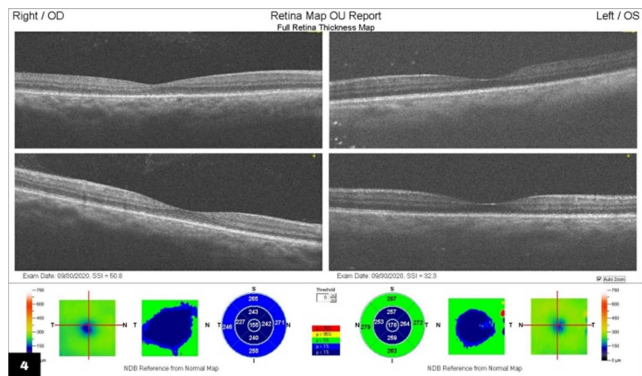


Figure 4. One month following initiation of systemic steroids-OCT images showing resolved fluid pockets.

Patient was started on oral steroids (Prednisolone 60mg/day) and on follow up after one month, she showed a good response to steroids with resolution of fluid pockets on OCT [Figure 4] and a improvement in visual acuity to 6/6 with +0.5DS/-0.5 Dcyl @180 in the right eye and to 6/12 with +1.5DS/-3.5 Dcyl @160 in the left eye. The corneal perforation had stabilized. Topical medication was tapered. Oral steroid tapering was advised and she was asked to follow up. On 6 months follow up, patient's visual acuity was maintained, with not relapse of the disease. She was maintained on low dose oral steroids. Her perforation was sealed well. She was put on a long term BCL and lubricants.

3. Discussion

Diagnosis of VKH is done by looking for the following features in the absence of ocular trauma -bilateral chronic iridocyclitis; posterior uveitis; Neurological and ENT symptoms like tinnitus, meningismus and skin manifestations like alopecia, poliosis/vitiligo. [9] This patient did not have any associated systemic manifestations. The stages of the disease include prodromal, acute uveitis, convalescent and chronic/recurrent uveitis. [10-12] Our patient presented in the acute phase with uveitis and a shallow anterior chamber angle. Acute angle closure/narrowing of anterior chamber angles has been reported by many. This may be due to choroidal effusion/inflammation, which can sometimes be associated with ciliary body rotation/ciliary edema and ciliochoroidal detachment, thus leading to narrowing of AC angles. [13]

Management regimens for VKH vary. However the mainstay treatment in the acute phase remains systemic corticosteroids. Some studies have found that the route of steroid administration did not alter the clinical outcomes. [14] IV methyl prednisolone was not started in this patient considering the vision drop was not severe. IVMP may preferably be started in cases with severe bilateral visual loss. [15] Some studies have reported that immunomodulatory therapy may be more effective in the acute phase. [15] However, in practice, immunomodulatory therapy is usually considered after a course of systemic steroids, in case of non resolution or recurrence or for maintenance. Thus it was not considered in the acute phase in this patient.

Sympathetic ophthalmitis (SO) was considered as a differential diagnosis. However, certain findings pointed more towards the diagnosis of VKH. The simultaneous presentation of both eyes was more in favour of VKH, unlike in SO, where the contralateral eye is affected before the eye with the insult. Also, the presence of a typical OCT picture- serous fluid pockets with multiple fibrous septae which are characteristic of VKH was present in this case. [16]

There have been no reports showing any typical corneal manifestations of the disease except for the presence of keratic precipitates [17] and corneal anaesthesia [18] in some cases.

4. Conclusion

This case report shows a rare presentation of VKH in a case with unilateral LSCD, which had lead to a corneal melt and perforation, with no identifiable positive systemic association for the condition. The clinical association between the two entities has not been published in literature till date. Further data or reports on such cases would help throw light on any possible association between LSCD and VKH disease.

References

- [1] Marcelo TT, Iguban EB. A case report on Vogt-Koyanagi-Harada disease seen at a tertiary hospital in the Philippines. *Ophthalmol Open J*. 2018; 3 (1): 1-4.

- [2] Sheriff F, Narayanan NS, Huttner AJ, Baehring JM. Vogt-Koyanagi-Harada syndrome: A novel case and a brief review of focal neurologic presentations. *Neurol Neuroimmunol Neuroinflamm*. 2014; 1 (4).
- [3] Kunjal Sejjal, Pejman Bakhtiari, and Sophie X. Deng. Presentation, Diagnosis and Management of Limbal Stem Cell Deficiency. *Middle East Afr J Ophthalmol*. 2013 Jan-Mar; 20 (1): 5-10.
- [4] Puangsricharern V, Tseng SC. Cytologic evidence of corneal diseases with limbal stem cell deficiency. *Ophthalmology*. 1995; 102: 1476-85.
- [5] Sangwan VS, Jain V, Vemuganti GK, Murthy SI. Vernal keratoconjunctivitis with limbal stem cell deficiency. *Cornea*. 2011; 30: 491-6.
- [6] Bhatia RP, Srivastava R, Ghosh A. Limbal stem cell study in contact lens wearers. *Ann Ophthalmol (Skokie)* 2009; 41: 87-92.
- [7] Sridhar MS, Vemuganti GK, Bansal AK, Rao GN. Impression cytology-proven corneal stem cell deficiency in patients after surgeries involving the limbus. *Cornea*. 2001; 20: 145-8.
- [8] Dua HS, Azuara-Blanco A. Autologous limbal transplantation in patients with unilateral corneal stem cell deficiency. *Br J Ophthalmol*. 2000; 84: 273-8.
- [9] Read RW. Vogt-Koyanagi-Harada Disease. *Ophthalmol Clin N Am* 15. 2002; 333-341.
- [10] Olivier Calveti, Caroline Laurent-Coriat, Michel Paques. Vogt-Koyanagi-Harada disease. *Orphanet*. 2009.
- [11] Rao NA, Gupta A, Dustin L, et al. Frequency of distinguishing clinical features in Vogt-Koyanagi-Harada disease. *Ophthalmology*. 2010; 117 (3): 591-599.
- [12] Castillo TR, Noche RR, Fajardo RV. Vogt - Koyanagi - Harada disease in the Philippines. *Philippine Journal of Ophthalmology*. 1998; 23 (4): 159-162.
- [13] Yao J, Chen Y, Shao T, et al. Bilateral acute angle closure glaucoma as a presentation of vogt-koyanagi-harada syndrome in four chinese patients: a small case series. *Ocul Immunol Inflamm* 2013; 21: 286-291.
- [14] Read RW, Yu F, Accorinti M, et al. Evaluation of the effect on outcomes of the route of administration of corticosteroids in acute Vogt-Koyanagi-Harada disease. *Am J Ophthalmol*. 2006; 142: 1191-24.
- [15] Fang W, Yang P, Vogt-Koyanagi-Harada Syndrome. *Current Eye Research*, 2008; 33 (7): 517-523.
- [16] Lin, D., Chen, W., Zhang, G. *et al.* Comparison of the optical coherence tomographic characters between acute Vogt-Koyanagi-Harada disease and acute central serous chorioretinopathy. *BMC Ophthalmol*. 2014; 87.
- [17] Nicula C, Szabo I. Vogt-Koyanagi-Harada syndrome Case report. *Rom J Ophthalmol*. 2016; 60 (3): 181-183.
- [18] Brouzas D, Chatzoulis D, Galina E, Liaskou A, Koukoulomatis P. Corneal anesthesia in a case with Vogt-Koyanagi-Harada syndrome. *Acta Ophthalmol Scand*. 1997 Aug; 75 (4): 464-5.