

**Case Report**

# Macular Hole Following Retained Subfoveal PFCL

**Navneet Mehrotra<sup>\*</sup>, Gayathri Mohan, Manish Nagpal, Sham Talati, Akansha Sharma**

Department of Retina and Vitreous, Retina Foundation, Ahmedabad, India

**Email address:**

navneetmeh@yahoo.com (N. Mehrotra), gmohan145@gmail.com (G. Mohan), drmanishnagpal@yahoo.com (M. Nagpal), sakt96@gmail.com (S. Talati), akansharma1993@gmail.com (A. Sharma)

<sup>\*</sup>Corresponding author**To cite this article:**Navneet Mehrotra, Gayathri Mohan, Manish Nagpal, Sham Talati, Akansha Sharma. Macular Hole Following Retained Subfoveal PFCL. *International Journal of Ophthalmology & Visual Science*. Vol. 6, No. 3, 2021, pp. 172-175. doi: 10.11648/j.ijovs.20210603.14**Received:** July 18, 2021; **Accepted:** August 3, 2021; **Published:** August 24, 2021

---

**Abstract:** *Introduction:* Perfluorocarbon liquids (PFCLs) were first developed in 1970s as possible substitutes to erythrocytes because of their capacity to dissolve relatively large amounts of oxygen. Based on their properties, PFCL are widely used in complex retinal detachments, but they can cause complications in cases of subretinal retention. Migration of peripherally located subretinal PFCL towards the fovea is well established, but spontaneous resolution of sub-foveal PFCL without surgical evacuation or displacement has rarely been described. *Case report:* We report a case of a 48 year old male on whom a vitrectomy was performed for a retinal detachment with scleral tear following trauma. PFCL was used for ten days as a temporary intraocular tamponade for retinal flattening. A second vitrectomy was done to replace the PFCL with silicone oil, following which retained sub-foveal PFCL was noted. *Result:* Fourteen months later, a macular hole developed and PFCL disappeared. Slight superior displacement of the macular area was observed due to contraction of fibrous proliferation superiorly. There was no decrease in visual acuity. Patient was advised to undergo silicon oil removal. **CONCLUSION:** In the future, improved understanding of the mechanisms of spontaneous resolution may enable the development of non-surgical methods to displace sub-foveal PFCL.

**Keywords:** PFCL, Sub Retinal, Macular Hole

---

## 1. Introduction

Perfluorocarbon liquids (PFCLs) were first developed in 1970s as possible substitutes to erythrocytes [1, 2] because of their capacity to dissolve relatively large amounts of oxygen. Initial trials with these compounds focused on their feasibility to be used as blood substitutes. These experiments proved the biocompatibility of these compounds. Based on their properties, they were then introduced for intraocular use, in what has become a milestone in vitreoretinal surgery.

After animal studies confirmed the safety of PFCL compounds as vitreous substitutes, Chang et al in 1987 first described the successful intraocular use of low viscosity liquid fluorocarbons (per-fluoro-tributylamine and per-fluoro-decalin) in four patients with complicated retinal detachments. [3, 4]. Long-term tamponade in animal models demonstrated retinal atrophy and retinal necrosis at the perfluorocarbon aqueous interface after 4 weeks even when highly purified PFCL compounds (per-fluoro-decalin) were used. [5]

PFCL has important properties, including high specific gravity, low viscosity, optical clarity, a refractive index different from that of saline, a boiling point higher than that of water, low surface tension, high interfacial tension, and immiscibility with water, blood, and silicone oil. PFCL is being used with increased frequency for retinal tamponade during vitreous surgery for complicated retinal detachments. PFCL is labeled for use in primary or recurrent retinal detachment (RD) complicated by giant retinal tear, proliferative vitreoretinopathy, and penetrating ocular trauma. It is also used in other conditions to stabilize the retina and to identify breaks in regular RD, to float a dislocated crystalline lens or intraocular lens, and to evacuate hemorrhage from the subretinal or suprachoroidal space. [6]

Despite their advantages, they cause complications in cases of inadvertent retention of PFCL droplets in the subretinal space. [2] Various studies report the incidence of subretinal PFCL to occur in zero to more than 10% of cases. [7-9] Risk factors for retained subretinal PFCL include small bubbles of PFCL, large retinal

breaks or retinotomies, a high velocity of infusion, retinal traction, and failure to perform saline rinsing during fluid-air exchange. [6] Although the mechanism of toxicity remains controversial, hypotheses have been proposed. [10, 11] Firstly, inflammatory response to retained PFCL has been suggested with histopathological evidence of macrophages with intracellular vacuoles of PCFL. [10] Secondly, in a porcine model, it has been proposed PCFL leads to disruption to retinal buffering thus leading to an accumulation of potassium and subsequent neurodegeneration and reactive gliosis. [11]

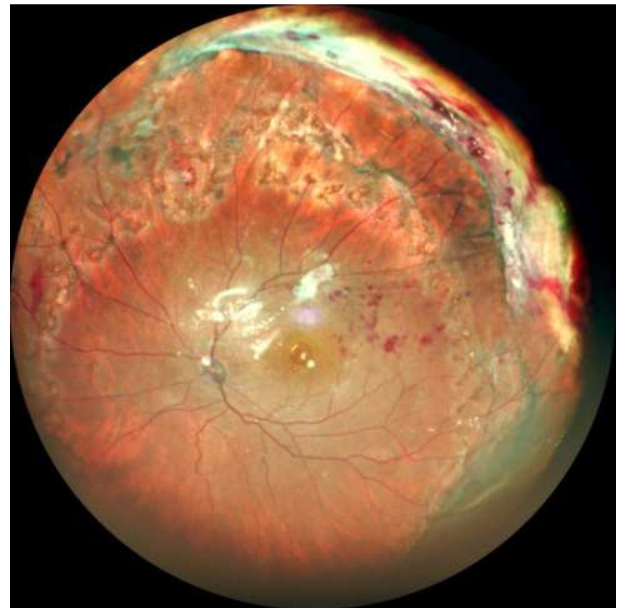
Migration of peripherally located subretinal PFCL towards the fovea is well established, but spontaneous resolution of sub-foveal PFCL without surgical evacuation or displacement has rarely been described. [12] Although the preferred management strategy for retained sub-macular PFCL is surgical intervention, at least four cases of spontaneous resolution of sub-macular PFCL, with associated improvement in visual acuity have been reported in the literature. [13-16] Recently, it is been hypothesised that due "Laplace's law", a relatively small sub-retinal PFCL droplet if connected to a relatively larger supra-retinal PFCL droplet in the vitreous could be attracted to join the larger droplet thus facilitating spontaneous resolution [17].

We present a case of a large single retained sub-foveal PFCL droplet following vitrectomy that demonstrated spontaneous evacuation with macular hole formation.

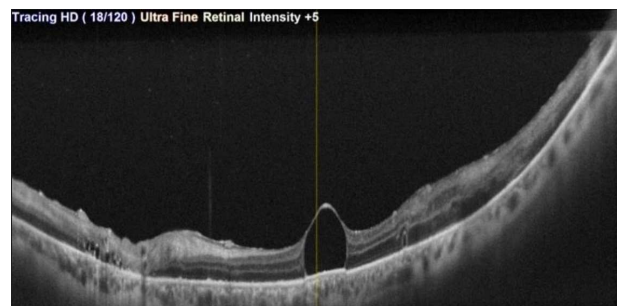
## 2. Case Report

A 48 year old gentleman presented to us with diminution of vision in his left eye (LE) following blunt trauma. His best corrected visual acuity (BCVA) was 20/20 in the right eye (RE) and perception of light in the left eye (LE). In the left eye a temporal scleral tear was noted extending posteriorly, 8 mm from limbus. A full chamber hyphaema was present. Retinal details could not be assessed. Ultrasound sonography revealed a RD with vitreous haemorrhage (VH), along with a choroidal detachment (CD). The examination of the right eye was within normal limits.

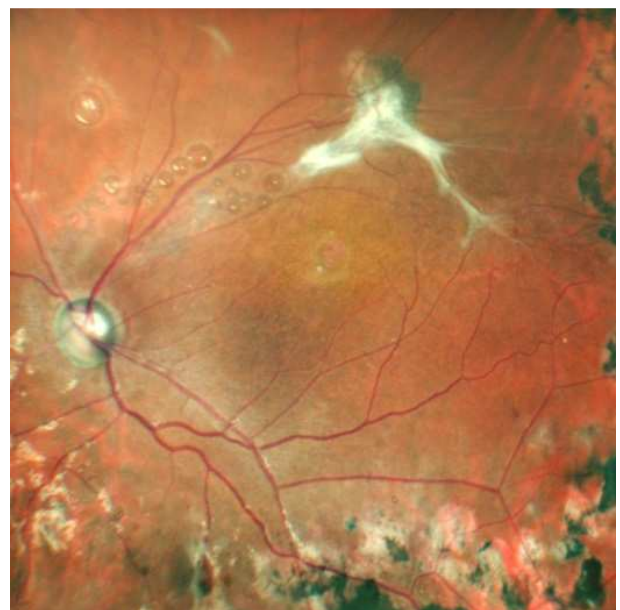Scleral tear repair with lensectomy and pars plana vitrectomy was done. PFCL was injected into the vitreous cavity as a temporary tamponade. Ten days later, PFCL was replaced with silicone oil tamponade. Post operatively, retina was well attached, a large sub-foveal PFCL was noted along with multiple subretinal small PFCL globules in the posterior pole (Figures 1 and 2). A fibrous proliferation along the supero-temporal vascular arcade with branch retinal vein occlusion was noted. One month post-surgery he regained visual acuity of 20/120. Patient was on regular follow up with no deterioration in vision. He was advised silicone oil removal but he refused. Sub-foveal PFCL was present till one year of follow up. Fourteen months later on routine examination no sub-foveal PFCL was noted but instead a macular hole had formed (Figures 3 and 4). Slight superior displacement of the macular area was observed due to contraction of fibrous proliferation superiorly. There was no decrease in visual acuity. Patient was once again been advised to undergo silicone oil removal.



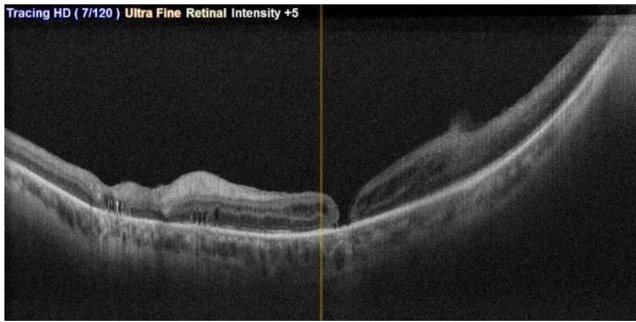
**Figure 1.** Color fundus photograph of the silicon oil filled left eye with a large sub-foveal PFCL globule. Multiple small PFCL globules also noted. A fibrous proliferation along the supero-temporal vascular arcade with branch retinal vein occlusion was present.



**Figure 2.** OCT image of the left eye showing Subfoveal PFCL globule at macula.



**Figure 3.** Color fundus photograph of the left eye showing full thickness macular hole with dragging of macula superiorly.



**Figure 4.** OCT image of the left eye showing Full thickness macular hole with disappearance of large subfoveal PFCL globule.

### 3. Discussion

A known risk of using PFCL as an adjunct in vitrectomy is that few residual bubbles may be retained in the sub retinal space and they may migrate toward the foveal region. It is ideal to note the PFCL bubbles intraoperatively and remove subretinal PFCL immediately. However, subretinal retention of PFCL cannot be detected in 0.9 to 11.1% of cases until follow-up visits. [7]

In 2009, Tewari et al. [18] suggested that retained PFCL causes chemical toxicity due to its high oxygen carrying capacity and direct mechanical compression on the retina leading to irreversible damage to retinal pigment epithelium. Mirshahi et al. [19] and Tewari agree to its prompt removal to avoid permanent loss of visual function. PFCL in the sub-foveal region may cause visual deterioration due to mechanical compression and chemical toxicity. It has to be removed if the patient complains of progressive visual deterioration. Our patient had reduced vision due to sub-foveal PFCL for which he was advised re-surgery which he refused. But he was regularly followed up. Cohen et al reported formation of retinal hole extra foveally following long term retention of PFCL. [20] Spontaneous extrusion of sub-foveal PFCL into the vitreous cavity has been described by Oellers et al. [13] They hypothesized that the PFCL droplet spontaneously extruded through a transient hole created in the thinned retina overlying the droplet following which the hole spontaneously closed. Tanabu et al also reported a case where a macular hole was caused by a retained sub foveal PFCL and it spontaneously closed. [14]

Methods of subfoveal PFCL removal described in literature are limited. Ojhi and colleagues have described its passive aspiration with flute needle by making a small retinotomy adjacent to the PFCL bleb which may result in sub-retinal haemorrhage. [6] Direct active aspiration by connecting a 27G cannula to vitrector as suggested by Mirshahi et al. [19] can result in enlargement of retinotomy, macular hole formation, microstructural damage, subretinal fibrosis and RPE atrophy. [21] A retinal detachment at the posterior pole and inferior periphery can be created by injecting balanced salt solution in the subretinal space through a retinotomy near the inferotemporal vessels. Variable success has been reported with this method. [22]

Kim et al., [23] had attempted creation of therapeutic

macular hole with bent tip of a 23G machinery vapor re-compressor blade and passive removal of PFCL with variable results. This procedure required maintaining prone position which is cumbersome to the patient and lacks co-operation. Besides, the use of gas may lead to raised intraocular pressure and delayed visual rehabilitation.

In the future, improved understanding of the mechanisms of spontaneous resolution may enable the development of non-surgical methods to displace sub-foveal PFCL.

### 4. Conclusion

In our case, the retained PFCL was observed following a traumatic detachment. We hypothesize that the traction caused by the fibrous proliferation superiorly, led to macular hole formation over the thinned retina which subsequently led to the escaping of the PFCL bubble into the vitreous cavity.

### References

- [1] Sloviter HA. Perfluoro compounds as artificial erythrocytes. *Fed Proc.* 1975; 34 (6): 1484-7.
- [2] Geyer RP. "Bloodless" rats through the use of artificial blood substitutes. *Fed Proc.* 1975; 34 (6): 1499-505.
- [3] Chang S, Zimmerman NJ, Iwamoto T, et al. Experimental vitreous replacement with perfluorotributylamine. *Am J Ophthalmol.* 1987; 103 (1): 29-37.
- [4] Chang S. Low viscosity liquid fluorochemicals in vitreous surgery. *Am J Ophthalmol.* 1987; 103 (1): 38-43.
- [5] Velikay M, Wedrich A, Stolba U, et al. Experimental long-term vitreous replacement with purified and nonpurified perfluorodecalin. *Am J Ophthalmol.* 1993; 116 (5): 565-70.
- [6] Ohji M. Perfluorocarbon Liquid: Handle with Care: A quick guide to avoiding retained subretinal PFCL and removing it when it occurs. *Retina Today.* March 2016; 26-27.
- [7] Garcia-Valenzuela E, Ito Y, Abrams GW. Risk factors for retention of subretinal perfluorocarbon liquid in vitreoretinal surgery. *Retina.* 2004; 24 (5): 746-752.
- [8] Garg SJ, Theventhiran AB. Retained subretinal perfluorocarbon liquid in microincision 23-gauge versus traditional 20-gauge vitrectomy for retinal detachment repair. *Retina.* 2012; 32 (10): 2127-2132.
- [9] Shulman M, Sepah YJ, Chang S, et al. Management of retained subretinal perfluorocarbon liquid. *Ophthalmic Surg Lasers Imaging Retina.* 2013; 44 (6): 577-583.
- [10] Elsing SH, Fekrat S, Green WR, Chang S, Wajer SD, Haller JA. Clinicopathologic findings in eyes with retained perfluoro-n-octane liquid. *Ophthalmology.* 2001; 108 (1): 45-48.
- [11] Winter M, Eberhardt W, Scholz C, Reichenbach A. Failure of potassium siphoning by Muller cells: a new hypothesis of perfluorocarbon liquid-induced retinopathy. *Invest Ophthalmol Vis Sci.* 2000; 41 (1): 256-261.
- [12] Yiu G, Fekrat S, Hahn P. Spontaneous peripheral migration of subfoveal perfluorocarbon. *Retina.* 2014; 34 (11): 2315-2316.

- [13] Oellers P, Charkoudian LD, Hahn P. Spontaneous resolution of subfoveal perfluorocarbon. *ClinOphthalmol*. 2015; 9: 517–519. [PMC free article][PubMed] [Google Scholar].
- [14] Tanabu R, Suzuki Y, Suzuki K, et al. Macular Hole Caused by Retained Subfoveal Perfluorocarbon that Subsequently Closed After Its Spontaneous Resolution: A Case Report. *Ophthalmology and therapy*. 2107; 6 (2): 381–384.
- [15] Baumann C, Cheng C, Jalil A, Patton N. Spontaneous Resolution of Submacular Perfluorocarbon Liquids. *Retin Cases Brief Rep*. 2019.
- [16] Sandinha MT, Chan YK, Steel DH, Wong D. Spontaneous resolution of submacular perfluorocarbon liquids; Absorption or Evacuation? *Retin Cases Brief Rep*. 2020.
- [17] Chan YK, Laybourne JP, Ng CO, et al. An in-vitro study of subretinal perfluorocarbon liquid (PFCL) droplets and the physics of their retention and evacuation. *Acta Ophthalmol*. 2021.
- [18] Tewari A, Elliott D, Singh CN, Garcia-Valenzuela E, Ito Y, Abrams GW. Changes in retinal sensitivity from retained subretinal perfluorocarbon liquid. *Retina*. 2009; 29 (2): 248–50.
- [19] Mirshahi A, Ghasemi F, Zarei M, Karkhaneh R, Ahmadraji A, Polkinghorne PJ. Removal of subfoveal perfluorocarbon liquid: Report of 3 cases. *J Curr Ophthalmol*. 2017; 29 (4): 324-8.
- [20] Cohen SY, Dubois L, Elmaleh C. Retinal Hole as a Complication of Long-Standing Subretinal Perfluorocarbon Liquid, *Retina*: 2006; 26 (7): 843-844.
- [21] Lesnoni G, Rossi T, Gelso A. Subfoveal liquid perfluorocarbon. *Retina*. 2004; 24: 172–6.
- [22] Tien LV, Pie rre-Kahn V, Azan F, et al. Displacement of retained subfoveal perfluorocarbon liquid after vitreoretinal surgery. *Arch Ophthalmol*. 2008; 126: 98–101.
- [23] Kim JM, Woo SJ, Park KH, Chung H. Surgical removal of retained subfoveal perfluorocarbon liquid through a therapeutic macular hole with intravitreal PFCL injection and gas tamponade. *Korean J Ophthalmol*. 2013; 27 (5): 392-5.