

Nodular Posterior Scleritis: A Clinical Case Report

Armando Bautista-Barba¹, Erick Andres Quiroz-Gonzalez¹, Miguel Angel Quiroz-Reyes^{2,*}, Jhoana Sanchez-Ruiz¹, Rafael Valdez-Sosa³, Gerardo Ledesma-Gil², Miguel Pedroza-Seres³, Federico Graue-Wiechers²

¹Ophthalmology Department, Institute of Ophthalmology Conde de Valenciana Foundation, National Autonomous University of Mexico, Mexico City, Mexico

²Retina Service, Institute of Ophthalmology Conde de Valenciana Foundation, National Autonomous University of Mexico, Mexico City, Mexico

³Uvea Department, Institute of Ophthalmology Conde de Valenciana Foundation, National Autonomous University of Mexico, Mexico City, Mexico

Email address:

drquiroz@prodigy.net.mx (M. A. Quiroz-Reyes)

*Corresponding author

To cite this article:

Armando Bautista-Barba, Erick Andres Quiroz-Gonzalez, Miguel Angel Quiroz-Reyes, Jhoana Sanchez-Ruiz, Rafael Valdez-Sosa, Gerardo Ledesma-Gil, Miguel Pedroza-Seres, Federico Graue-Wiechers. Nodular Posterior Scleritis: A Clinical Case Report. *International Journal of Ophthalmology & Visual Science*. Vol. 7, No. 1, 2022, pp. 1-5. doi: 10.11648/j.ijovs.20220701.11

Received: December 17, 2021; **Accepted:** January 4, 2022; **Published:** January 12, 2022

Abstract: *Background:* Scleritis is a rare inflammation of the outer coat of the eye, which is often characterized by pain and redness and may be associated with visual loss and blindness. Posterior scleritis may lead to the formation of a choroidal mass which is often confused with choroidal tumors. A delayed and an inaccurate diagnosis may lead to devastating outcomes, that including unnecessary enucleation. Therefore, a prudent clinical judgement is necessary. *Objective:* To report clinical characteristics of an outstanding posterior scleritis which required a multidisciplinary collaboration for its management. *Method:* A young man presented with redness and diminished vision in his right eye for 5 days. A detailed ophthalmological examination was completed, which suggested a final diagnosis of posterior nodular scleritis that was presumed to occur secondary to anti-neutrophil cytoplasmic antibodies-associated granulomatosis with polyangiitis. A multimodal imaging workup suggested posterior nodular scleritis and laboratory investigation confirmed positive antineutrophil cytoplasmic antibodies (C-ANCA). All other infectious and immunological tests came negative. The patient was subsequently treated with systemic steroids and immunomodulatory therapy, with an excellent visual recovery. Best-corrected visual acuity improved from 20/200 at presentation to 20/25 at eight months after the therapy, and there was no evidence of disease recurrence. *Conclusion:* Nodular posterior scleritis is an important but benign disease that may mimic an intraocular tumor. Multimodal imaging studies and detailed laboratory investigations are essential for its correct diagnosis and appropriate management.

Keywords: Nodular Posterior Scleritis, Granulomatosis with Polyangiitis, C-ANCA, Ultrasonography, Intraocular Mass

1. Introduction

Scleritis is an inflammatory disease of the outer coat of the eye, which is characterized by pain and redness. The disease may also cause significant visual loss and blindness of the affected eye [1]. The prevalence of the disease is rare, with an estimated incidence rate lying at 4 per 100,000 person-years, and mostly affecting females [2] and middle-aged populations although it may occur at all ages [1, 3]. Watson (1976) classified scleritis as anterior and posterior types, with the

anterior type being further classified into diffuse, nodular, or necrotizing, depending on the clinical presentation [4].

Posterior scleritis (PS) can result from infections, trauma, systemic diseases (e.g., rheumatoid arthritis), or can be idiopathic [5]. The disease may lead to the development of a choroidal mass that may be confused for choroidal tumors. PS is also frequently associated with anterior scleritis. McCluskey and colleagues (1999) reported a large dataset of PS consisting of 137 patients over a period of 22 years, in which 34% patients had associated anterior scleritis and 13%

had subretinal localized granuloma [3]. Since the disease presents with similar signs and symptoms to other clinical conditions, diagnosis can be delayed and treatment is often inappropriately instituted, and may also lead to unnecessary clinical decisions that including enucleation. Therefore, it is important to distinguish the disease from other pathologies before making final clinical decisions. While working up for the disease diagnosis, a variety of clinical and laboratory tests are mandatory that include tests for anti-nuclear antibodies and antineutrophil cytoplasmic antibodies.

In the present paper, an unusual case of posterior scleritis is presented and relevant literature is reviewed. As far as we know, this is the first report of posterior nodular scleritis associated with positive antineutrophil cytoplasmic antibodies (C-ANCA) in young male. We describe the appropriate clinical approach and helpful diagnostic techniques to diagnose posterior scleritis in a clinically confusing case.

2. Case Presentation

A 25-year-old man, student by profession, presented to the emergency department at the Institute of Ophthalmology Conde de Valenciana Foundation with redness and diminished vision in his right eye for 5 days. The patient did not complain of any pain or double vision. He drank 2–3 beers on weekends, smoked 2–3 packs of cigarettes weekly, but denied illicit drug use. The family history did not reveal any significant ophthalmic disease association. On physical examination, there was no sign of proptosis, diplopia, or restricted mobility. His vital signs were normal, and physical examination was unremarkable with a normal body temperature. The patient reported allergic rhinitis.

His best-corrected visual acuities (BCVA) on presentation were 20/200 and 20/25 in the right and left eyes, respectively. Intraocular pressure was 14 mm Hg in each eye (Goldman Applanation Tonometer). Slit-lamp examination revealed mild episcleritis, scleromalacia, and bilateral peripheral lipid corneal deposition as well as cellularity in the anterior chamber of right eye (Figure 1). Fundus examination of the right eye revealed vitreous cellularity (2+) and a dome-shaped choroidal mass associated with serous retinal detachment (Figure 2). The assessment of the left eye was unremarkable, with clear media, healthy optic disc head, as well as no morphological or vascular abnormalities of the retina or macula.

B-scan ultrasonography of the right eye revealed vitreous cellularity, retinal detachment, subretinal fluid, and a nodular lesion of irregular thickness with heterogeneous characteristics. Calcifications were present in the temporal sector and sound waves were absorbed towards its base (Figure 3).

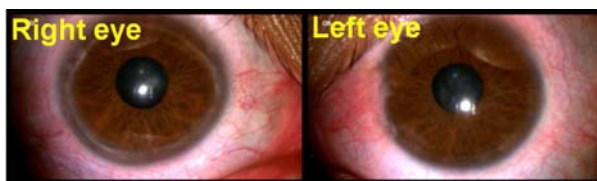


Figure 1. Slit-lamp examination of both eyes showing mild episcleritis, scleromalacia, peripheral lipid corneal deposition.

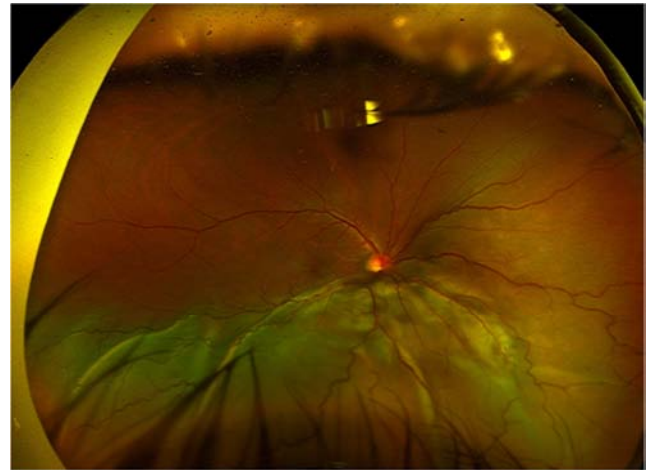


Figure 2. Right eye fundus examination revealed vitreous cellularity 2+ and a dome-shaped choroidal mass associated with serous retinal detachment.

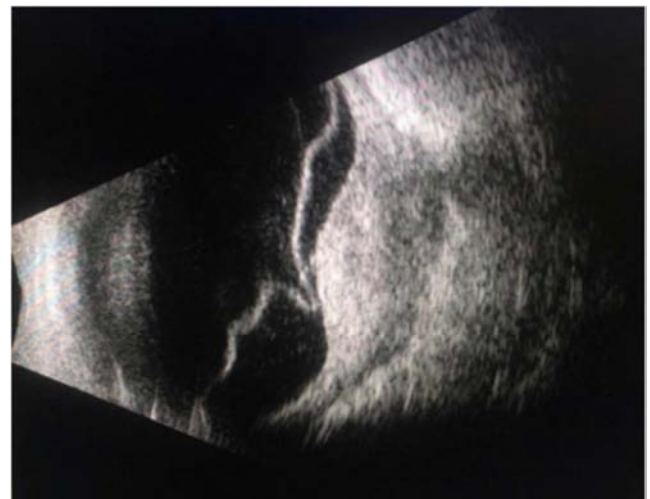

Figure 3. B-scan ultrasonography revealed vitreous cellularity, retinal detachment, subretinal fluid, and a nodular lesion of irregular thickness.

A detailed systematic evaluation was completed which included: tests for antinuclear antibodies, anti-double-stranded DNA, antineutrophilic cytoplasmic antibodies (C-ANCA); and rheumatoid factor. Further tests included tuberculin skin test, syphilis serology and chest computed tomography (CT). All the test results were unremarkable.

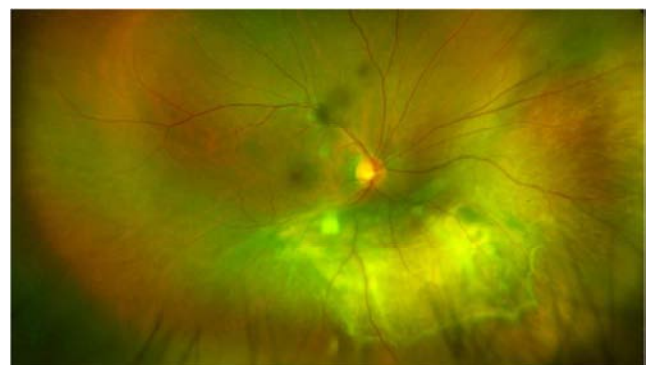


Figure 4. Right eye fundus examinations revealing an amelanotic subretinal mass.

The initial course of the treatment included methylprednisolone (1 g) for 3 days, followed by a combination of oral prednisolone (1 mg/kg/day) along with one bolus of cyclophosphamide (1 g) and methotrexate PO 20 mg weekly. There was a rapid visual improvement which was associated with decreased subretinal fluid. At one month after the therapy initiation, the amelanotic choroidal mass was still persistent (Figure 4).

On Optical coherence tomography (Spectralis OCT; Heidelberg Engineering, Heidelberg, Germany), multiple chorioretinal folds, intraretinal fibrous material, and pseudocystic spaces were identified (Figure 5).

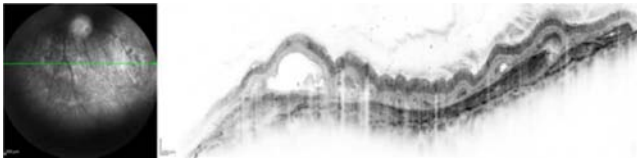


Figure 5. Right eye OCT revealing irregularity of the internal retinal layers in association with intraretinal fibrosis and pseudocystic spaces with choroidal folds.

B- and A-scan ultrasonography were repeated, which revealed a nodular hyperechogenic lesion associated with scleral thickening and medium-to-high reflectivity, respectively (Figure 6).

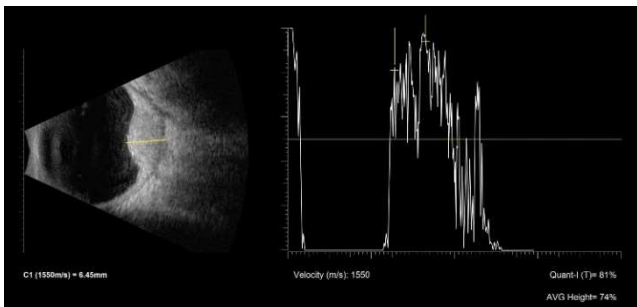


Figure 6. B and A-scan ultrasonography were repeated, revealing a nodular hyperechogenic lesion associated with scleral thickening and medium to high reflectivity, respectively.

Indocyanine green angiography (ICGA) revealed diffuse hypofluorescence corresponding to the mass area, with pinpoint hyperfluorescence in the late phases (Figure 7).

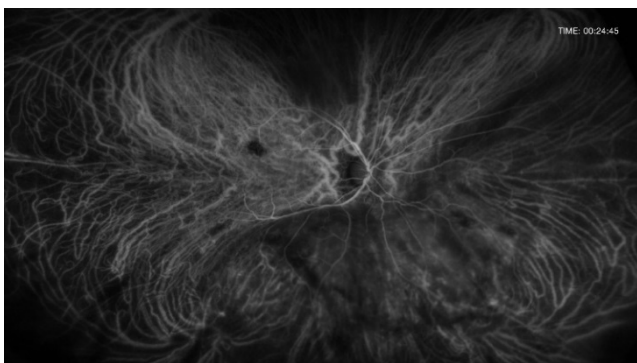


Figure 7. Indocyanine green angiography (ICGA) showing diffuse hypofluorescence corresponding to the mass area.

A multimodal imaging workup was suggestive of posterior nodular scleritis. Further investigation revealed positive antineutrophil cytoplasmic antibodies (C-ANCA), and all other laboratory results for the tests of the infectious and immunological came negative. BCVA improved from 20/200 at presentation to 20/25 at eight months after therapy initiation. There was no evidence of recurrence on subsequent follow up visits.

3. Discussion

The historical data suggest the incidence of posterior scleritis to be within 3.4-4.1 per 100,000 person-years [6]. Although the disease is more common in middle aged people, it affects all ages and is mostly diagnosed in the fourth to fifth decade of life with a mean age of around 50 years [2, 3, 7, 8]. The nodular form of the disease is more common in older population which occurs mostly in the sixth decade of life [8]. The disease is rarely reported in the literature and to our knowledge there has been no previous report of posterior nodular scleritis associated with C-ANCA antibodies in young individuals [2]. We report an unusual presentation of posterior nodular scleritis, presumably secondary to C-ANCA-associated granulomatosis with polyangiitis (GPA), that affected a young man. Proper treatment with systemic steroids and immunomodulatory therapy, particularly during long-term management, carries an excellent prognosis with almost no recurrence and a rapid remission of the mass thickness with visual recovery, as observed in this case report.

Due to similar clinical presentations, it is important to distinguish nodular posterior scleritis from other clinical conditions which are the harbingers of intraocular tumors such as choroidal melanoma, lymphoma, metastatic deposits, and hemangioma. Features that help distinguish posterior scleritis from an amelanotic choroidal mass include the presence of a single, strictly unilateral, orange-yellow pale mass without the presence of lipofuscin or drusen and light transmission on transillumination [5, 8]. Pain is the most frequent symptom in anterior scleritis [9] but patients usually present without symptoms of pain in posterior scleritis and scleromalacia perforation [10].

The pain in posterior scleritis is minimal as compared to the severity of tissue inflammation, especially when the disease occurs on its own without anterior segment involvement [3]. Therefore, the diagnosis of the disease may be particularly challenging as only about one third of patient have associated anterior scleritis, which is a painful condition [3].

Literature suggests that one of posterior scleritis are associated with systemic diseases that include vasculitides, autoimmune diseases, and lymphoma [3]. A large retrospective cohort reported bilateral disease in 15.8% of their patients [2]. Although, the disease largely presents on its own without marked anterior segment disease symptoms, several clinical characteristics that are suggestive of posterior scleritis are reported by Lavric *et al.* [2]. The clinical signs that have been reported in posterior scleritis include periocular

pain, conjunctival chemosis, conjunctival hyperemia, and anterior chamber reaction. These signs are reported to be present in 25-30% of patients [2]. Associated posterior segment findings observed in posterior scleritis are choroidal folds, serous retinal detachment, macular edema, optic disc edema, vitreous cells, and a subretinal mass [2, 6]. Similar clinical signs have also been reported by Agrawal *et al.* in their case series consisting of 11 patients with nodular posterior scleritis [5].

Several case reports have mentioned association of posterior nodular scleritis with amelanotic choroidal melanoma [11-13]. Additionally, there have been reports of clinical decision to enucleate the inflamed eye due to strong suspicion of malignant choroidal melanoma [14, 15]. To avoid inappropriate clinical decision and to provide the optimal management, a thorough clinical assessment accompanied with multimodal imaging studies are important as observed in the present case report. On B-scan ultrasonography, posterior nodule scleritis is reported as a sessile and single-lobed mass with medium-high internal reflectivity, as opposed to melanoma, which generally has a dome or collar stud shape and a low-to-medium homogeneous reflectivity [5, 8]. There is also no choroidal excavation seen unlike in melanoma.

An amelanotic choroidal mass with high internal reflectivity on a B-scan should be differentiated from choroidal metastasis and choroidal hemangiomas. The use of ICGA is helpful to distinguish between these conditions; choroidal metastasis is usually hypo fluorescent at all phases on an underlying background and it exhibits a larger area of choroidal involvement than that adjudged by clinical examinations [16, 17]. ICGA is the most helpful study to display the intrinsic vascular pattern of a circumscribed choroidal hemangioma [13]. In the early phases, brilliant hyper fluorescence is observed, while in late phases, a washout effect with a reduction of the initial hypo fluorescence [13, 17].

Scleritis can be caused by several causally related disorders, which account for approximately 36% to 44% of patients, for which an underlying autoimmune disease, generally rheumatoid arthritis, is mostly reported [5, 6]. In the present case report, we observed an association of posterior scleritis with a systemic autoimmune disease. Other reported associations vary from ANCA-associated granulomatosis with polyangiitis (GPA), relapsing polychondritis, inflammatory bowel disease, and systemic lupus erythematosus [6]. Our patient did not present with additional systemic manifestations of GPA. Nonetheless, C-ANCA antibodies were positive upon further testing. Systemic vasculitis is the second most common autoimmune group of diseases associated with scleritis [18], specifically GPA, where ocular involvement occurs in 14% to 60% of patients [19].

The aim of the treatment in posterior scleritis is to halt disease activity, induce remission and obtain visual recovery. Nodular posterior scleritis can be treated with a variety of agents, including systemic nonsteroidal anti-inflammatory agents, systemic steroids (local, oral, or intravenous forms),

and immunomodulatory therapy. Most cases of nodular posterior scleritis respond well to systemic corticosteroids [7] and the prognosis is excellent. In our case, the treatment resulted in rapid remission of the disease.

4. Conclusion

Posterior scleritis is a rare inflammatory disease, which may lead to the development of choroidal mass that may look like a choroidal tumor. This complexity of the diagnosis often leads to inappropriate clinical decisions, which may include enucleation of the affected eyeball. The use of multimodal imaging, including SD-OCT, FFA, ICGA, and ultrasonography, aid in the diagnosis of the disease. It is important to consider age of the patients and their systemic history to rule out malignant tumors and to avoid diagnostic errors.

Conflict of Interest

The authors declare that they have no conflicts of interest.

Availability of Data and Materials

Photos and composite figures supporting the findings of this report may be released upon written application to the Photographic Laboratory and Clinical Archives Department at the Institute of Ophthalmology Conde de Valenciana Foundation (non-profit organization). Chimalpopoca 14, Colonia Obrera, Mexico City, Mexico 06800, and the corresponding author upon request.

Code Availability

Not applicable.

Competing Interests

The authors declare that they have no competing interests.

Authors' Contributions

All authors contributed to the study description of the case. The material preparation, data collection, and analysis were performed by Armando Bautista-Barba, Erick Andres Quiroz-Gonzalez, and Miguel Angel Quiroz-Reyes. The first and main draft of the manuscript was written by Armando Bautista-Barba, Erick Andres Quiroz-Gonzalez, Miguel Angel Quiroz-Reyes, and all authors commented on the previous versions of the manuscript. All authors have read and approved the final manuscript for publication.

Co-Authors Affiliation

All co-authors are affiliated to the Faculty of Medicine in the Postgraduate Division at NATIONAL AUTONOMOUS UNIVERSITY OF MEXICO. Mexico City, Mexico.

Consent for Publication

Written informed consent was obtained from the patient for the publication of this report and its accompanying images.

Ethical Approval

All procedures in this study were performed in accordance with the ethical standards of the institutional and/or national research committee and with the Declaration of Helsinki (1964) and its later amendments.

Acknowledgements

We express our deep appreciation to the technical staff of the Institute of Ophthalmology, Conde de Valenciana Foundation, Mexico City, Mexico.

The authors did not receive support from any organization for the submitted work.

References

- [1] Vergouwen, D., et al., *Current insights in the pathogenesis of scleritis*. Experimental Eye Research, 2020. 197: p. 108078.
- [2] Lavric, A., et al., *Posterior scleritis: analysis of epidemiology, clinical factors, and risk of recurrence in a cohort of 114 patients*. Ocular immunology and Inflammation, 2016. 24 (1): p. 6-15.
- [3] McCluskey, P. J., et al., *Posterior scleritis: clinical features, systemic associations, and outcome in a large series of patients*. Ophthalmology, 1999. 106 (12): p. 2380-2386.
- [4] Watson, P. and S. S. Hayreh, *Scleritis and episcleritis*. British Journal of Ophthalmology, 1976. 60 (3): p. 163-191.
- [5] Agrawal, R., et al., *Nodular posterior scleritis: clinico-sonographic characteristics and proposed diagnostic criteria*. Retina, 2016. 36 (2): p. 392-401.
- [6] Nevares, A., et al., *Noninfectious autoimmune scleritis: recognition, systemic associations, and therapy*. Current rheumatology reports, 2020. 22 (4): p. 1-10.
- [7] Alsarhani, W. K. and A. M. A. El-Asrar, *Multimodal imaging of nodular posterior scleritis: Case report and review of the literature*. Middle East African Journal of Ophthalmology, 2020. 27 (2): p. 134.
- [8] Ally, N. and A. Makgotloe, *Nodular Posterior Scleritis Masquerading as a Subretinal Mass*. Middle East African Journal of Ophthalmology, 2020. 27 (4): p. 231.
- [9] Sharma, R., S. Marasini, and B. Nepal, *Tubercular scleritis*. Kathmandu University Medical Journal, 2010. 8 (3): p. 352-356.
- [10] Watson, P. and A. Romano, *The impact of new methods of investigation and treatment on the understanding of the pathology of scleral inflammation*. Eye, 2014. 28 (8): p. 915-930.
- [11] Shukla, D. and R. Kim, *Giant nodular posterior scleritis simulating choroidal melanoma*. Indian journal of ophthalmology, 2006. 54 (2): p. 120-122.
- [12] Liu, A. T., F. O. Luk, and C. K. Chan, *A case of giant nodular posterior scleritis mimicking choroidal malignancy*. Indian journal of ophthalmology, 2015. 63 (12): p. 919.
- [13] Compatible, E. and L. Coroides, *Giant nodular posterior scleritis compatible with ocular sarcoidosis simulating choroidal melanoma*. Arch Soc Esp Oftalmol, 2007. 82: p. 563-566.
- [14] Feldon, S. E., et al., *Clinical manifestations of brawny scleritis*. American journal of ophthalmology, 1978. 85 (6): p. 781-787.
- [15] Finger, P. T., et al., *Posterior scleritis as an intraocular tumour*. British journal of ophthalmology, 1990. 74 (2): p. 121-122.
- [16] Mathis, T., et al., *New concepts in the diagnosis and management of choroidal metastases*. Progress in retinal and eye research, 2019. 68: p. 144-176.
- [17] Arevalo, J. F., et al., *Circumscribed choroidal hemangioma: characteristic features with indocyanine green videoangiography*. Ophthalmology, 2000. 107 (2): p. 344-350.
- [18] Akpek, E. K., et al., *Evaluation of patients with scleritis for systemic disease*. Ophthalmology, 2004. 111 (3): p. 501-506.
- [19] Comarmond, C. and P. Cacoub, *Granulomatosis with polyangiitis (Wegener): clinical aspects and treatment*. Autoimmunity reviews, 2014. 13 (11): p. 1121-1125.