

# Intermediate Term Results with Ahmed Glaucoma Valve Implantation in Refractory Glaucoma with a Modified Surgical Technique

Tanuja Kate\*, Rajiv Choudhary, Divya Patel, Urvija Choudhary

Rajas Eye and Retina Research Centre, Indore, India

## Email address:

[tanuja\\_121@rediffmail.com](mailto:tanuja_121@rediffmail.com) (T. Kate)

\*Corresponding author

## To cite this article:

Tanuja Kate, Rajiv Choudhary, Divya Patel, Urvija Choudhary. Intermediate Term Results with Ahmed Glaucoma Valve Implantation in Refractory Glaucoma with a Modified Surgical Technique. *International Journal of Ophthalmology & Visual Science*.

Vol. 7, No. 2, 2022, pp. 65-72. doi: 10.11648/j.ijovs.20220702.14

Received: April 16, 2022; Accepted: May 3, 2022; Published: May 12, 2022

**Abstract:** *Purpose:* To investigate intraocular pressure (IOP) control, visual acuity, and complications at 1 year after Ahmed Glaucoma Valve (AGV) implantation. *Methods:* This was a retrospective, observational study of 35 AGV implanted patients who were followed up to 1-year post-surgery. The AGV implantation was performed at a tertiary healthcare facility in India. The IOP control, visual acuity status, and safety after AGV implantation with a specific modification of surgical technique were evaluated. *Results:* The study included 35 patients who underwent AGV implantation. The IOP reduced to near-normal levels post-surgery with immediate benefit being seen at Month 1, and the benefit was sustained till Month 12 as measured by the mean IOP. At all-time points post-surgery, patients had stable visual acuity. Post-surgery, the use of medication decreased over time during the study in all patients. There were no new or unexpected complications post-surgery. In most patients, AGV implantation was well-tolerated. *Conclusions:* AGV implantation with modified surgical technique (tube is not anchored to the sclera and partial thickness scleral flap covers the tube) works very well at intermediate term as regard to IOP control and visual acuity and it is an effective way of treating the patients with refractory glaucoma.

**Keywords:** Refractory Glaucoma, AGV, Trabeculectomy, Intraocular Pressure, Visual Acuity

## 1. Introduction

Refractory glaucoma is any kind of glaucoma which has failed medical/surgical interventions, including, one or more incisional intraocular glaucoma surgeries, one or more cilioabative procedures, or have any other condition in which a conventional incisional glaucoma surgery like trabeculectomy would be more likely to fail than for an eye with uncomplicated primary open-angle glaucoma [1]. In these cases with relatively poor outcomes associated with conventional surgical interventions, like trabeculectomy, glaucoma drainage devices (GDDs) are recommended surgical modality [2]. While the use of GDDs is well-known in a secondary setting for refractory glaucoma, trials have established their efficacy and safety as a primary surgical procedure [3-5].

Ahmed glaucoma valve (AGV) implantation has been

shown to result in fewer postoperative complications than valve-less GDDs, with fewer reoperations due to safety concerns 5 years post-surgery [6, 7]. A recent prospective randomized study showed that AGV implantation is effective in reducing intraocular pressure (IOP) and glaucoma medications in patients with refractory glaucoma [8]. Also, many retrospective studies have shown that AGV implantation is safe and effective in Asian population with refractory glaucoma [9-12].

Given the increasing importance of GDDs, especially AGV in the management of glaucoma [13], it is vital that post-surgical clinical outcomes are well-understood to enable their optimal use. In light of this, we report results from the current study which investigated IOP control, visual acuity, and complications 1 year after AGV implantation with a specific modification of surgical technique.

The primary objective of the study was to assess IOP control and visual acuity status. Also, the safety and complications after AGV implantation with a specific modification of surgical technique were evaluated.

## 2. Methods

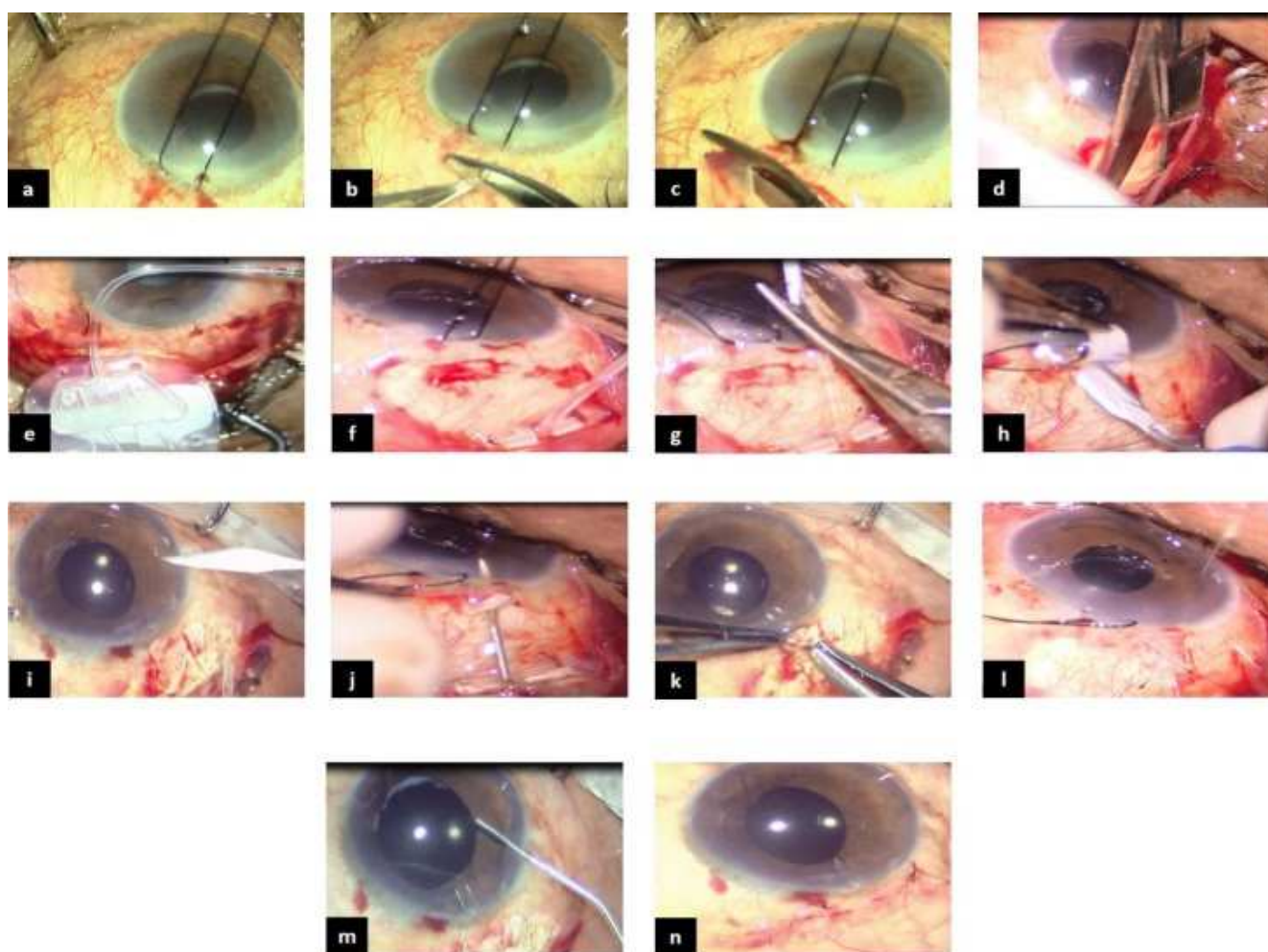
### 2.1. Study Design

This was a retrospective, observational study of 35 patients with AGV implants who were followed up to 1-year post-surgery. The AGV implantation was performed at a tertiary healthcare facility in India. However, patients were assessed for the defined study outcomes (IOP, number of medications, visual acuity, and complications) at Months 1, 6 and 12. No restrictions on medications were applied, except if mandated by clinical need. The conduct of the study was approved and

the need for consent to participate in the study was waived by the Institutional Ethics Committee. The study was held in accordance with the ethical requirements of the Declaration of Helsinki.

### 2.2. Inclusion and Exclusion Criteria

The indications of AGV implantation included refractory glaucoma, such as, neovascular glaucoma, buphthalmos, post keratoplasty glaucoma, chronic angle closure glaucoma, silicone oil-induced glaucoma, and glaucoma due to mixed etiology. All the cases of neovascular glaucoma who were planned for AGV implantation were given intravitreal with/without intracameral Avastin injection (0.05 mL) 5-7 days prior to surgery. Patients with severe scleral or sclero-limbal thinning, extensive fibrosis of conjunctiva, and ciliary block glaucoma were excluded.



AC: anterior chamber; AGV: Ahmed Glaucoma Valve

**Figure 1.** Surgical technique performed as a part of the study. (a): Traction suture. (b): Conjunctival incision. (c): Relaxing incision. (d): Pocket Formation. (e): Priming of the valve. (f): Suturing the valve plate. (g): Trimming the tube. (h): Formation of partial thickness scleral flap. (i): Paracentesis. (j): Formation of needle track. (k): Introduction of AGV tube into AC. (l): Suturing the scleral flap. (m): Washing off the viscoelastic substance. (n): Conjunctival closure.

### 2.3. Surgical Technique

The quadrant selected for AGV implantation was

superotemporal, except in two cases where the eyes were silicone oil filled, and hence AGV was implanted inferotemporally. The cases were operated under peribulbar

or general anesthesia. Corneal traction suture was applied [Figure 1a] to expose the quadrant. A conjunctival incision was made and a deep pocket formed in the quadrant selected [Figures 1b-d]. The valve was primed using 27G cannula mounted on a 2cc fluid (Ringer's lactate) filled syringe [Figure 1e]. The aim of priming was to open up the valve. After priming, the valve plate was glided in the pocket formed taking care to hold the valve plate from the edges and not at the center otherwise, it could damage the valve. The valve plate was sutured to the sclera 8–10 mm from limbus using 9/0 nylon suture [Figure 1f]. The AGV tube was trimmed [Figure 1g] with bevel up in a way that 2–3 mm of it would be in the anterior chamber. A partial thickness scleral flap was dissected in the same manner as we do for trabeculectomy [Figure 1h]. Paracentesis was done [Figure 1i]. Using a 24 G needle, a track was created starting 1–2 mm behind the limbus and entering the anterior chamber parallel to iris [Figure 1j]. Viscoelastic substance was injected in the track formed to facilitate introduction of AGV tube into anterior chamber. Tube was introduced into the anterior chamber in such a way that 2–3 mm of it was inside anterior chamber and well away from cornea and iris [Figure 1k]. The scleral flap was sutured using 9/0 nylon suture [Figure 1l]. Thereafter, viscoelastic substance was washed off from anterior chamber using irrigating solution [Figure 1m]. The conjunctiva was pulled over the valve plate and sutured using 9/0 nylon suture in interrupted fashion [Figure 1n]. The modification in surgical technique included AGV tube not being anchored to sclera and AGV tube was covered by partial thickness rectangular scleral flap. The model FP7 was used in 20 cases and FP8 in 15 cases. The model FP8, the pediatric model was used in one case of juvenile glaucoma, three cases of buphthalmos where trabeculectomy had failed, and 11 cases of refractory glaucoma in adults where either the globe was small or the eyes were deep seated.

#### 2.4. Postoperative Care and Follow up

Postoperative treatment regimen included topical cycloplegic eye drops once daily for 5 days and antibiotic steroid eye drops for 6 weeks in tapering dosage. During the postoperative period, antiglaucoma medication was added depending on IOP level. After AGV implantation, postoperative visual acuity (best corrected), IOP by applanation tonometry and any complications were noted at Months 1, 6 and 12.

#### 2.5. Statistical Analysis

In this study, for estimating the IOP and expecting the error of estimation to be less than 2 of true mean (that is expected difference of IOP to be 2), the sample standard deviation to be 6 with a probability of 95% that is at an error rate of 5%, the sample size was estimated as  $N = (1.96)^2 (6)^2 / 2^2$  and thus it gives the sample of  $34.5 \approx 35$  subjects.

The study data were summarized using descriptive statistics such as mean, range, standard deviation (SD),

frequency, and percentage. Paired T-test or Wilcoxon Signed rank test was performed depending upon the normality of the data to check if there was significant change from baseline to follow up visits. McNemar's test was used to check if the shift in percentages is significant. Shift tables were prepared to represent the changes in the findings pre versus post-surgery. All hypothesis testing was carried out at the 5% (2-sided) significance level i.e.  $\alpha=0.05$ , unless specified otherwise and was performed using SAS® Version 9.3 or higher.

### 3. Results

#### 3.1. Patient Characteristics

The study included 35 patients who underwent AGV implantation. At Month 12, data were available for 32 patients (3 patients were lost to follow-up after 6 months). The mean (SD) age of the patients was 57.8 (19.9) years. There were total 23 male patients (65.7%) and 12 female patients (34.3%). The most common indication for which AGV implantation was carried out was neovascular glaucoma (26 (74.3)), followed by buphthalmos (failed trabeculectomy) (3 (8.6); Table 1).

**Table 1.** Patient baseline characteristics.

Demographic Characteristics	N = 35
Age (years)	
N	35
Mean (SD)	57.8 (19.94)
Median (Min, Max)	64.0 (0.8, 75.0)
Gender, n (%)*	
Male	23 (65.7)
Female	12 (34.3)
Diagnosis, n (%)*	
Juvenile glaucoma (Failed trabeculectomy)	1 (2.86)
Post KP	1 (2.86)
CACG (Failed trabeculectomy)	2 (5.71)
Silicone oil induced glaucoma	2 (5.71)
Buphthalmos (Failed trabeculectomy)	3 (8.57)
NVG	26 (74.3)

\*Percentages are based on the number of subjects in the Analysis Set. CACG, chronic angle closure glaucoma; Post-KP, Post keratoplasty; NVG, neovascular glaucoma; SD, standard deviation.

#### 3.2. Intraocular Pressure

The IOP reduced to near-normal levels post-surgery with immediate benefit being seen at Month 1, and the benefit was sustained till Month 12 as measured by the mean IOP [Figure 2]. The change over time in mean IOP from baseline was 28.3 (13.6) mmHg at Month 1, 28.5 (13.2) mmHg at Month 6, and 27.7 (13.7) at Month 12. The change in IOP was significant at all time-points during the study as demonstrated by the Wilcoxon Signed rank test ( $p<0.0001$ ). The difference in IOP between each time-point post-surgery suggests that the treatment benefit achieved at Month 1 was sustained over time until Month 12 without any significant loss of benefit in patients.

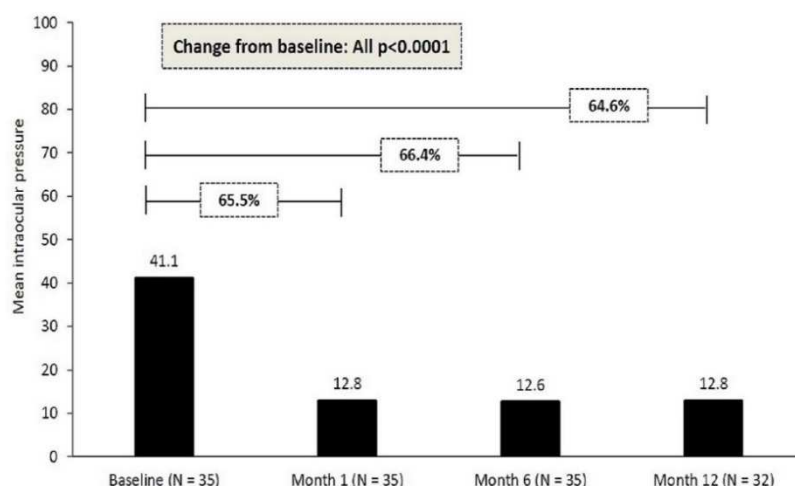


Figure 2. Mean intraocular pressure from baseline up to 12 months post-surgery.

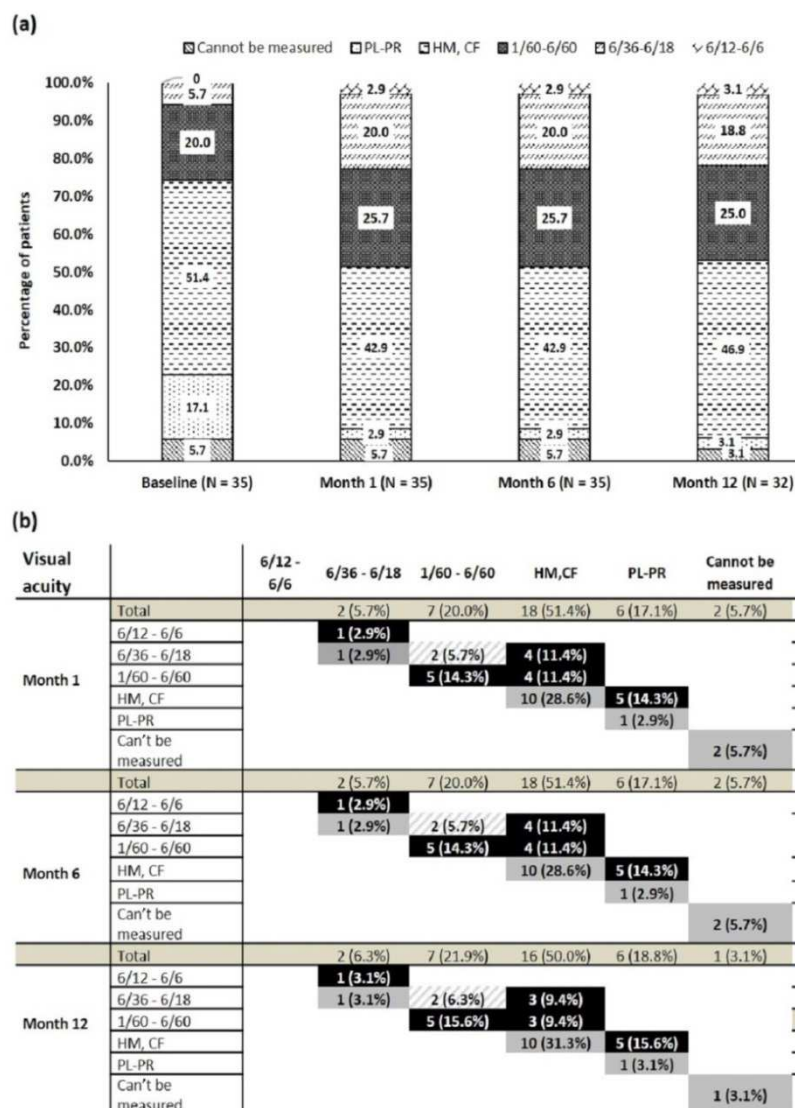


Figure 3. Visual acuity: (a): during the study. (b): shift from baseline to Month 12 post-surgery.

Pattern fill stands for deterioration in visual acuity; black stands for improvement in visual acuity; and grey stands for no change in visual acuity compared to baseline distribution

CF, counting fingers; HM, hand motion; PL-PR, perception of light with projection of rays.

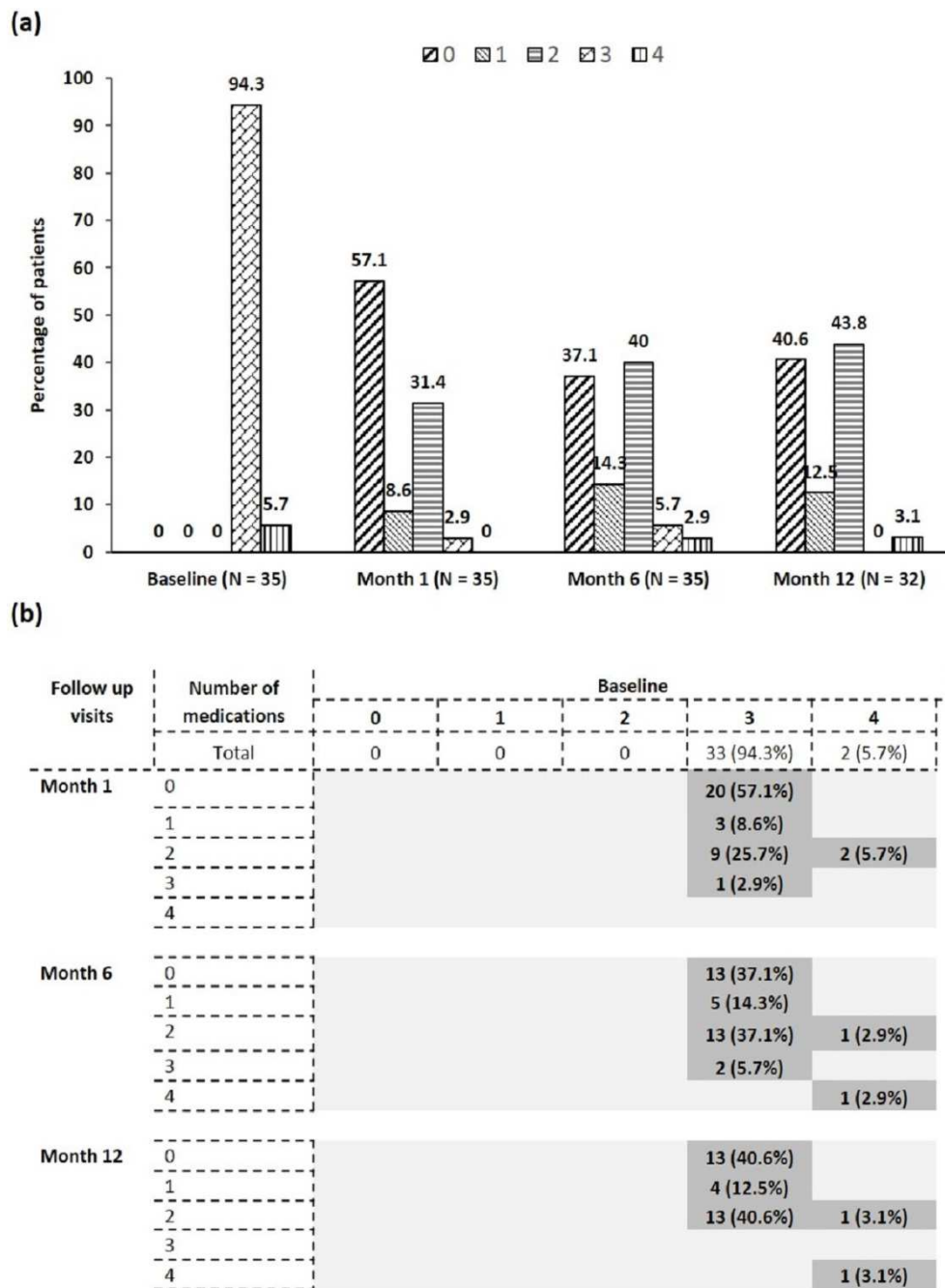
### 3.3. Change in Visual Acuity

At all time-points post-surgery, more patients had stable visual acuity compared to baseline [Figures 3a and 3b]. There were 51.4% patients with visual acuity graded as hand motion (HM) and counting fingers (CF), which reduced to 46.9% until Month 12. However, visual acuity could not be recorded in two patients because of their age (<2 years).

### 3.4. Medication Use

Post-surgery, the use of medication decreased over time

during the study starting at baseline till Month 12 in all patients. At baseline, all patients were on 3 or more medications, which decreased to 2.9% and 5.7% at Month 1 and Month 6, respectively. At Month 12, none of the patients were taking 3 or more medications. Two patients who were on 4 medications at baseline decreased their intake to no medication at Month 1, and one of the 2 patients remained on 2 medications till the end of observation at Month 12, while the other reverted to use of 4 medications. While all patients were on 3 medications or more at baseline, and at Month 12, 97.1% of patients were using 2 or fewer medications [Figures 4a and 4b].



**Figure 4.** Medication use. (a): during the study. (b): shift from baseline to Month 12 post-surgery.

**Table 2.** Safety profile during the study: Incidence of postoperative complication until Month 12 ( $N = 35$ ).

Complication	n (%)*
Long tube	1 (2.86)
Long tube, Hypertensive phase, tube exposure	1 (2.86)
Tenon's cyst, Hypertensive phase, tube exposure	1 (2.86)
Hypertensive phase	1 (2.86)
Tube exposure	1 (2.86)
Hyphema	1 (2.86)
Failed AGV	1 (2.86)
Implant Extrusion	1 (2.86)
Nil	27 (77.1)

AGV, Ahmed glaucoma valve

\*Percentages are based on the number of subjects in the Analysis Set.

### 3.5. Safety Profile

There were no new or unexpected complications post-surgery. In most patients, AGV implantation was well-tolerated with only 3 cases of hypertensive phase. In all, eight of the 35 patients had some adverse events or complications.

Overall, long tube with hypertensive phase, tube exposure, tube exposure related to Tenon's cyst and implant extrusion was seen in 1 case each [Table 2]. Hyphema was encountered only in 1 out of 26 cases of neovascular glaucoma. This can be explained by the fact that in these cases intravitreal with or without intracameral Avastin was injected and surgery was done 5-7 days later.

## 4. Discussion

Refractory glaucoma is the term used for any kind of glaucoma which is refractory to medical and/or surgical treatment. The AGV implantation carried out in this study resulted in considerable benefits to patients who underwent the surgery, and was well-tolerated. The surgical method used in this study differed in the sense that partial thickness scleral flap was used (as in trabeculectomy) to cover the tube and the tube was not anchored to the sclera. Despite this modification there was no tube movement, probably because of the fact that scleral flap keeps the tube very well in place. The use of partial thickness scleral flap of different sizes is also supported by many published reports of surgical modifications for AGV implantation [5, 9, 14]. This technique avoids the additional step of anchoring, while possibly ameliorating the risk of tube migration using partial thickness scleral flap. Thus, this technique provides protection from some of the apparent adverse outcomes due to tubal malfunction/migration, while at the same time minimizing eye trauma.

As reported in literature, AGV is indicated increasingly both as a primary surgical intervention, as well as, being the secondary standard of care in patients with refractory glaucoma [2]. In the current study, AGV was implanted secondarily after the failure of trabeculectomy in 6 cases and in the rest of 29 cases the implantation was done primarily.

The clinical outcomes associated with AGV implantation have largely shown considerable and sustained benefit post-

surgery [6]. In the current study, the mean IOP was  $41.1 \pm 12.50$  mmHg preoperatively which reduced to  $12.8 \pm 4.18$  mmHg at Month 1,  $12.6 \pm 4.05$  mmHg at Month 6 and  $12.8 \pm 3.54$  mmHg at Month 12 of the follow up. This is consistent with other reports from Asian populations. Lai et al reported that mean IOP decreased from  $37.0 \pm 12.1$  mmHg before the implant surgery to  $16.1 \pm 12.4$  mmHg at the last follow up after surgery [15]. In another study from India in 2007, mean IOP reduced from  $36.3 \pm 15.7$  mmHg to  $19.6 \pm 9.2$  mmHg till last follow up [16]. In 2015, an observational study from India reported that mean IOP decreased from  $39.71 \pm 8.99$  mmHg pre-operatively to  $17.52 \pm 5.72$  mmHg at last follow-up ( $p < 0.001$ ) [17]. Thus, the real-world evidence of consistent hypotensive effect in these patients supports the observations in this study [18, 19]. Even in a multicenter randomized controlled clinical trial, at 3 years IOP (mean  $\pm$  SD) was  $14.3 \pm 4.7$  mmHg [6]. In the 5-year extension of the same study, IOP (mean  $\pm$  SD) was  $14.7 \pm 4.4$  mmHg in the AGV group [7]. In a study by García-Delpech et al where Ahmed valve sutureless implantation was done, IOP control ( $\leq 21$  mmHg) with or without antiglaucoma eye drops was achieved in 82.2% patients [20]. In the current study at Month 12, the median IOP was 12.0 mmHg, implying that at least half of all patients were under that level with the lowest IOP at 7.0 mmHg. In fact, in one of the earliest studies on AGV, when used for fluid drainage in postoperative conditions in intractable glaucoma, the cumulative probability of success at 12 months was 78% in a prospective multicenter trial [21].

The use of medication to control IOP was reduced in our study at all time-point post-surgery. At baseline, all patients were on  $\geq 3$  medications, whereas at Month 12, none of the patients were taking  $\geq 3$  medications. This observation concurs with Dubey et al. [17], Elhefney et al. [22], and Lee et al. [23] who reported a significant decline in the number of medications following AGV implantation. In addition, stable visual acuity as observed in this study is also consistent with previous reports [10, 17].

In summary, our findings confirm the trends seen in literature with respect to considerable clinical benefit of AGV implantation. In most patients, AGV implantation was well-tolerated with only 3 cases of hypertensive phase and no new or unexpected complications were noted post-surgery. Overall, eight of the 35 patients had some adverse events or complications and also the rate of complications was lower than that reported earlier. Complication rate reported by Christakis et al was 52% compared to 22.9% in the current study [13]. Parihar et al. (2009) reported that intraoperative hyphema was seen in 6% cases, choroidal detachment in 6%, and shallow anterior chamber with hypotony in 13% cases in an Indian population [16]. Recently, a prospective randomized study of 56 patients with AGV implant, in which a scleral graft was used to cover the limbal portion, early postoperative hyphema was reported in 14.2% (8/56) of patients [8]. However, in our study, where partial thickness scleral flap was used to cover the tube, there were no cases of hypotony/shallow anterior chamber. The use of partial

thickness scleral flap which was of rectangular shape (6×4 mm) was possibly acting as anchoring force and hence reduced the chances of hypotony. Similar finding was reported by a retrospective study, in which the drainage tube was inserted under the partial-thickness scleral flap and then covered with the flap. In this study, a half-thickness, rectangular, 4×4 mm and limbal-based scleral flap was created [24]. In another retrospective study, none of the patients experienced postoperative hypotony, in whom watertight suture on the flap was made along the path of the tube [25].

Dubey et al (2015) reported that post-operative hypotony occurred in 10.90% patients from a tertiary healthcare setting in Northern India [17]. Even in other Asian studies, transient postoperative hypotony with shallow anterior chamber occurred in 10.8% cases [15]. During the early days of use as well, the valve was associated with complications, including, serous choroidal detachments in 13 eyes (22%), blockage of the tube in six eyes (10%), malposition of the tube in four eyes (7%), a suprachoroidal hemorrhage in one eye (2%), and corneal graft rejections in three (19%) of 16 eyes with corneal grafts [21].

There are possibly few limitations of our study that should be noted while interpreting the results. Firstly, there is no control group, which possibly would have reduced the bias. Secondly, the follow-up period of 1 year is relatively short. Thirdly, due to small sample size, the study findings can't be generalized to wide range of patients. Therefore, data should be validated with further long-term and larger studies.

## 5. Conclusion

In the current study, AGV implantation with modified surgical technique (tube is not anchored to the sclera and partial thickness scleral flap covers the tube) resulted in a significant reduction in IOP and medication use, and stability of visual acuity. So, AGV works very well at intermediate term as regard to IOP control and it is an effective way of treating the patients with refractory glaucoma.

## Authors' Contributions

TK: Conception, design, collecting data, analysis, interpretation of data, and drafting the article; RC: Analysis and interpretation of data; DP and UC contributed equally in research planning. All authors contributed to the development of the manuscript, critically reviewed, and approved the final manuscript.

## Declaration of Conflicting Interests

All the authors do not have any possible conflicts of interest.

## Acknowledgements

The authors thank Dr. Nilesh Kumar Jain (Knowledge Shapers, Indore) for medical writing and editorial assistance.

## References

- [1] ANSI Standard for Implantable Glaucoma Devices: A Framework for Clinical Evaluation. <https://www.fda.gov/media/88139/download>. Last accessed on 27 August 2020.
- [2] European Glaucoma Society Terminology and Guidelines for Glaucoma, 4th Edition Chapter 3: Treatment principles and options Supported by the EGS Foundation: Part 1: Foreword; Introduction; Glossary; Chapter 3 Treatment principles and options. *Br J Ophthalmol.* 2017; 101: 130–95.
- [3] Zarei R, Amini H, Daneshvar R, Nabi FN, Moghimi S, Fakhraee G, *et al.* Long-term outcomes of ahmed glaucoma valve implantation in refractory glaucoma at Farabi Eye Hospital, Tehran, Iran. *Middle East Afr J Ophthalmol.* 2016; 23: 104–9.
- [4] Mokbel TH, El Hefney EM, Hagraas SM, Badawi AE, Kasem MA, Al Nagdy AA, *et al.* Launching a paradigm for first and redo-surgery in primary congenital glaucoma: institutional experience. *Int J Ophthalmol.* 2019; 12: 226–34.
- [5] Riva I, Roberti G, Katsanos A, Oddone F, Quaranta L. A Review of the Ahmed glaucoma valve implant and comparison with other surgical operations. *Adv Ther.* 2017; 34: 834–47.
- [6] Barton K, Feuer WJ, Budenz DL, Schiffman J, Costa VP, Godfrey DG, *et al.* Three-year treatment outcomes in the Ahmed Baerveldt comparison study. *Ophthalmology.* 2014; 121: 1547–57.
- [7] Budenz DL, Barton K, Gedde SJ, Feuer WJ, Schiffman J, Costa VP, *et al.* Five-year treatment outcomes in the Ahmed Baerveldt comparison study. *Ophthalmology.* 2015; 122: 308–16.
- [8] Elbaklish KH, Saleh SM, Gomaa WA. Baerveldt glaucoma implant versus ahmed glaucoma implant in a one-year follow up, Comparative Study. *Clin Ophthalmol.* 2020; 14: 29–39.
- [9] Xie Z, Liu H, Du M, Zhu M, Tighe S, Chen X, *et al.* Efficacy of Ahmed glaucoma valve implantation on neovascular glaucoma. *Int J Med Sci.* 2019; 16: 1371–6.
- [10] Ong SC, Aquino MC, Chew P, Koh V. Surgical outcomes of a second Ahmed glaucoma valve implantation in Asian eyes with refractory glaucoma. *J Ophthalmol.* 2020; 2020: 8741301.
- [11] Gebremichael BG, Mohamed A, Chaurasia S, Senthil S. Outcomes of Ahmed glaucoma drainage implant in eyes with glaucoma secondary to iridocorneal endothelial syndrome. *J Glaucoma.* 2020; 29: 567–71.
- [12] Ramyashri S, Raj N, Pradhan A, Ali MH, Rao A. Outcomes of Ahmed glaucoma valve FP8 versus FP7 in adult secondary glaucoma. *Int Ophthalmol.* 2020; 40: 1359–66.
- [13] Christakis PG, Tsai JC, Kalenak JW, Zurakowski D, Cantor LB, Kammer JA, *et al.* The ahmed versus baerveldt study: three-year treatment outcomes. *Ophthalmology.* 2013; 120: 2232–40.
- [14] Pakravan M, Esfandiari H, Yazdani S, Doozandeh A, Dastborhan Z, Gerami E, *et al.* Clinical outcomes of Ahmed glaucoma valve implantation in pediatric glaucoma. *Eur J Ophthalmol.* 2019; 29: 44–51.

- [15] Lai JS, Poon AS, Chua JK, Tham CC, Leung AT, Lam DS. Efficacy and safety of Ahmed glaucoma valve implant in Chinese eyes with complicated glaucoma. *Br J Ophthalmol*. 2000; 84: 718–21.
- [16] Parihar JK, Vats DP, Maggon R, Mathur V, Singh A, Mishra SK. The efficacy of Ahmed Glaucoma Valve drainage devices in cases of adult refractory glaucoma in Indian eyes. *Indian J Ophthalmol*. 2009; 57: 345–50.
- [17] Dubey S, Sharma V, Agrawal A, Chauhan L, Douglas G. Safety and efficacy of Ahmed glaucoma valve implantation in refractory glaucomas in Northern Indian eyes. *Saudi J Ophthalmol*. 2015; 29: 103–8.
- [18] Choudhari NS, George R, Shantha B, Neog A, Tripathi S, Srinivasan B, *et al.* Ahmed Glaucoma valve in eyes with pre-existing episcleral encircling element. *Indian J Ophthalmol*. 2014; 62: 570–4.
- [19] Shah MR, Khandekar RB, Zutshi R, Mahrooqui R. Short term outcome of Ahmed Glaucoma Valve implantation in management of refractory glaucoma in a tertiary hospital in Oman. *Oman J Ophthalmol*. 2013; 6: 27–32.
- [20] García-Delpech S, Sanz-Marco E, Martínez-Castillo S, López-Prats MJ, Udaondo P, Salom D, *et al.* Ahmed valve, sutureless implantation: A new approach to an easier technique. *J Glaucoma*. 2013; 22: 750–6.
- [21] Coleman A, Hill R, Wilson R, Choplin N, Neumann R, Bacharach J, *et al.* Initial clinical experience with the Ahmed Glaucoma Valve implant. *Am J Ophthalmol*. 1995; 120: 23–31.
- [22] Elhefney E, Mokbel T, Abou Samra W, Kishk H, Mohsen T, El-Kannishy A. Long-term results of Ahmed glaucoma valve implantation in Egyptian population. *Int J Ophthalmol*. 2018; 11: 416–21.
- [23] Lee CK, Ma KT, Hong YJ, Kim CY. Long-term clinical outcomes of Ahmed valve implantation in patients with refractory glaucoma. *PLoS One*. 2017; 12: e0187533.
- [24] Lee HY, Park JS, Choy YJ, Lee HJ. Surgical outcomes of different Ahmed Glaucoma Valve implantation methods between scleral graft and scleral flap. *Korean J Ophthalmol*. 2011; 25: 317–22.
- [25] Gedar Totuk OM, Kabadayi K, Colakoglu A, Ekizoglu N, Aykan U. A novel surgical technique for prevention of Ahmed glaucoma valve tube exposure: long scleral flap augmented with Tenon advancement and duplication. *BMC Ophthalmol*. 2018; 18: 226.