

# Long-Term Observation of Intravitreal Injection of Ranibizumab Combined with Ozurdex® in the Treatment of Retinal Vein Occlusion with Macular Edema

Xuemei Liang, Baiyun Shen·Zuguo Ou, Hongmei An, Li Li\*

Department of Fundus Diseases, Nanning Aier Eye Hospital, Nanning, China

## Email address:

lxmyanke@163.com (Li Li)

\*Corresponding author

## To cite this article:

Xuemei Liang, Baiyun Shen·Zuguo Ou, Hongmei An, Li Li. Long-Term Observation of Intravitreal Injection of Ranibizumab Combined with Ozurdex® in the Treatment of Retinal Vein Occlusion with Macular Edema. *International Journal of Ophthalmology & Visual Science*. Vol. 7, No. 4, 2022, pp. 124-138. doi: 10.11648/j.ijovs.20220704.14

**Received:** October 25, 2022; **Accepted:** November 11, 2022; **Published:** November 22, 2022

**Abstract:** Background: To evaluate the duration and long-term efficacy of intravitreal injection of ranibizumab (IVR) combined with Ozurdex® (DEX) in the treatment of retinal vein occlusion with macular edema (RVO-ME). Methods: This retrospective case study included 38 patients with non-ischemic RVO-ME who were initially treated by intravitreal injection of IVR combined with DEX. Patients with recurrence of macular edema continued with IVR+DEX therapy. Data were recorded for all patients at baseline and at 1 week, and 1, 3, 4, 5, 6, 9, and 12 months after treatment. The primary outcome measures were the average reinjection interval and the number of injection needles. Results: The mean interval for reinjection of RVO-ME was  $134.2 \pm 9.1$  days. The average number of injection needles was  $4.2 \pm 1.1$ , and 65.8% of patients received 4 injection needles. There was no significant difference in mean reinjection interval and injection needle between central retinal vein occlusion (CRVO) and branch retinal vein occlusion (BRVO) patients. At the end of follow-up, the mean improvement of BCVA in CRVO and BRVO patients was  $0.29 \pm 0.26$  and  $0.31 \pm 0.33$ , respectively, and 52.6% (20/38) patients experienced visual acuity improvement of  $> 3$  lines. The average decrease in CFT was  $406.0 \pm 272.3 \mu\text{m}$  and  $408.2 \pm 379.9 \mu\text{m}$ , respectively, and there was no significant difference between the two types of RVO-ME in BCVA improvement and CFT reduction ( $p=0.82$  and  $0.98$ ). Conclusions: Intravitreal injection of ranibizumab combined with Ozurdex® led to better efficacy, fewer injections, lower medical burden, and more controllable side effects.

**Keywords:** Retinal Vein Occlusion, Macular Edema, Ranibizumab, Ozurdex®

## 1. Introduction

Retinal vein occlusions (RVOs) are the second most common cause of the retinal vascular disease after diabetic retinopathy. In 2015, the global prevalence of RVO in people aged 30-89 was 0.77% [1]. A community-based cross-sectional study conducted in China revealed that the prevalence of RVO was 0.96%, with an average age of  $52.9 \pm 13.1$  years [2]. Macular edema (ME) is the most common complication of central retinal vein occlusion (CRVO) and branch vein occlusion (BRVO), as well as the main cause of vision loss. Its etiology is complex, the course of the disease is prolonged, and it is prone to repeated episodes. The treatment cycle is also long [3]. The pathogenesis of RVO-ME is not fully understood, and established pathogenic mechanisms include upregulation of

inflammatory factors and vascular endothelial growth factor (VEGF), leading to increased vascular osmolality, fluid leakage, and macular edema [4, 5].

Since 2010, anti-VEGF drugs, such as ranibizumab, have been widely used in the clinical treatment of RVO-ME. In addition, another RVO-ME treatment drug, Ozurdex® (DEX), has been gaining increasing attention from clinicians. It is long-acting dexamethasone that can be sustained-released in the vitreous cavity after injection and exert anti-inflammatory effects. In China, it has been approved for the treatment of RVO-ME [6]. A large number of randomized controlled trials have also demonstrated that both ranibizumab and DEX can significantly improve visual acuity and foveal thickness [7-9]. The 2015 guidelines for the clinical treatment of retinal vein occlusion recommend both anti-VEGF drugs and DEX as

first-line treatments for RVO-ME [10]. Both treatments have certain advantages and disadvantages. The advantage of DEX is fewer injections and longer efficacy; however, it can increase intraocular pressure (IOP) and accelerate the opacity of the lens. On the other hand, ranibizumab has fewer side effects, but it involves frequent injections in order to maintain optimal vision improvement [7, 11]. Some RVO-ME patients treated with anti-VEGF have no obvious effect, and about 30% of RVO-ME patients have vitreal VEGF levels within the normal range, suggesting that anti-inflammatory treatment may be needed [4]. Likewise, not all RVO-ME respond to hormonal therapy [12].

Over recent years, anti-VEGF combined with DEX treatment for RVO-ME has been widely used in clinical practice. RVO-ME patients expect fewer injections while maintaining efficacy. Therefore, the aim of this study was to evaluate the duration of efficacy, long-term efficacy, and safety of intravitreal injection of IVR combined with DEX in the treatment of RVO-ME.

## 2. Materials and Methods

This retrospective case study included 38 eyes of 38 patients diagnosed with non-ischemic RVO-ME in the department of fundus diseases, Nanning Aier Eye Hospital from January 2019 to October 2021. The follow-up period was 12 months. Inclusion criteria were the following: 1)  $\geq 18$  years; 2) non-ischemic CRVO or BRVO confirmed by fluorescein fundus angiography (FFA); 3) untreated or no intraocular injection within 3 months; 4) CFT  $\geq 300$   $\mu\text{m}$  by optical coherence tomography (OCT) and 5) best-corrected visual acuity (BCVA) of 0.05–0.5 (Log MAR 1.3–0.3). Exclusion criteria were: patients with ischemic RVO, diabetes mellitus, glaucoma, and previous macular laser therapy.

A total of 38 enrolled patients were initially treated with intravitreal ranibizumab combined with DEX (IVR+DEX). There were 27 males (71.1%) and 11 females (28.9%) with ages ranging from 19 to 76 years old (average age of  $53.1 \pm 14.2$  years). During the follow-up, patients with ME recurrence continued to receive combined injection therapy. The criteria for reinjection were the CFT  $> 300$   $\mu\text{m}$  or the

presence of subretinal or intraretinal fluid. BCVA was measured using a decimal chart and converted into LogMAR for computing purposes, and the CFT was assessed by optical coherence tomography (Heidelberg, Germany) for macular edema. IOP was measured by CT80A non-contact tonometer (Topcon, Japan). Retinal ischemia was assessed by FFA before treatment and at 6 months after treatment. Clinical efficacy assessments were evaluated at 1 week, and 1, 3, 4, 5, 6, 9, and 12 months after treatment. The measures before treatment were used as a baseline.

### 2.1. Efficacy

The primary outcome measures were the average reinjection interval and the number of injection needles. The secondary outcome measures were BCVA and CFT improvement from baseline at 12 months, high IOP ( $>25\text{mmHg}$ ), and cataract surgery rates.

### 2.2. Statistical Analysis

All statistical analyses were performed using IBM SPSS 22.0. Graphs were made using GraphPad Prism 8.0 software. Image processing using Adobe Photoshop CS 6.0 software. Categorical variables were summarized with frequencies and percentages, and continuous variables were presented as means with standard deviations. BCVA and CFT were compared with baseline using the Wilcoxon rank-sum test for paired data and group comparison using the Wilcoxon rank-sum test of independent samples. Categorical data were analyzed using Fisher's exact test. A  $p < 0.05$  was considered statistically significant.

## 3. Results

### 3.1. Demographic and Baseline Characteristics

According to the extent of RVO involvement, patients were divided into 21 cases in the CRVO group and 17 cases in the BRVO group. There was no significant difference between the two groups in age, gender, course of the disease, baseline visual acuity, and CFT (Table 1).

Table 1. Demographic and baseline characteristics of patients.

	Total n=38	CRVO n=21	BRVO n=17	P
Age, years				0.40
Mean $\pm$ SD	53.1 $\pm$ 14.2	51.3 $\pm$ 16.6	55.3 $\pm$ 10.1	
Range	19~76	19~76	39~74	
Sex, n (%)				0.72
Male	27 (71.1%)	14 (66.7%)	13 (76.5%)	
Female	11 (28.9%)	7 (33.3%)	4 (23.5%)	
Course of disease, days				0.46
Mean $\pm$ SD	48.7 $\pm$ 55.1	42.7 $\pm$ 51.9	56.1 $\pm$ 59.6	
Range	1~180	1~180	3~180	
BCVA (Log MAR)				0.95
Mean $\pm$ SD	0.76 $\pm$ 0.36	0.77 $\pm$ 0.34	0.76 $\pm$ 0.39	
CFT, $\mu\text{m}$				0.97
Mean $\pm$ SD	649.08 $\pm$ 297.63	650.86 $\pm$ 256.79	646.88 $\pm$ 349.87	
Phakic eye, n (%)	23 (60.5%)	12 (57.1%)	11 (64.7%)	0.74
Artificial intraocular lens, n (%)	15 (39.5%)	9 (42.9%)	6 (35.3%)	

BCVA Best-corrected visual acuity; CFT Central foveal thickness.

### 3.2. Reinjection Interval and the Number of Injection Needles

The total number of injection needles in 38 patients was 152, with an average of  $4.2 \pm 1.1$  (range 2 to 6). Most of the patients received 4 injection needles (65.8%), 10.5% patients received 2 injection needles, and 23.7% patients received 6 injection needles. The average number of injection needles in the CRVO group was  $4.4 \pm 1.0$  vs.  $3.9 \pm 1.1$  in the BRVO group. There was no significant difference in the number of injection needles between the two groups ( $p=0.27$ ).

The mean reinjection interval for all RVO-MEs was  $134.2 \pm 9.1$  days (range 112 to 159 days). Further analysis was performed by CRVO and BRVO subgroups. The mean reinjection intervals for CRVO and BRVO groups were  $133.3 \pm 8.2$  days and  $135.6 \pm 10.3$  days, respectively, and there was no statistically significant difference between the groups ( $p=0.43$ ). Treatment intervals in the CRVO group ranged from 112 to 159 days (95% confidence interval was 129.9-136.6 days). Treatment intervals in the BRVO group ranged from 115 to 146 days (95% confidence interval 130.4-140.7 days). There were some individual differences in the interval of reinjection treatment. Only 3 patients received one combined treatment, and there was no recurrence of ME during the 12-month follow-up.

### 3.3. Efficacy and Subgroup Analysis

During the follow-up, Log MAR BCVA improved from  $0.76 \pm 0.36$  to  $0.46 \pm 0.25$ . The CFT decreased from  $649.1 \pm 297.6 \mu\text{m}$  to  $242.07 \pm 130.69 \mu\text{m}$ . The BCVA and CFT in RVO-ME patients were significantly improved compared with the baseline ( $p < 0.001$ ). Further analysis showed that the Log MAR BCVA of CRVO group improved from  $0.77 \pm 0.34$  to  $0.48 \pm 0.23$ , and the CFT decreased from  $650.9 \pm 256.8 \mu\text{m}$  to  $244.8 \pm 145.0 \mu\text{m}$ . Meanwhile, the Log MAR BCVA of BRVO group improved from  $0.76 \pm 0.39$  to  $0.45 \pm 0.27$ , and the CFT decreased from  $646.9 \pm 349.9 \mu\text{m}$  to  $238.7 \pm 114.9 \mu\text{m}$ . The BCVA and CFT were significantly improved in both groups compared with baseline ( $p < 0.001$ ) (Figures 1 and 2). The Log MAR BCVA of the CRVO group and the BRVO group improved by an average of  $0.29 \pm 0.26$  and  $0.31 \pm 0.33$ , respectively. There was no significant difference in the improvement between the two groups ( $p=0.82$ ). BCVA of 20 patients (52.6%) improved by more than 3 lines. Moreover, the CFT of the CRVO group and the BRVO group decreased by an average of  $406.0 \pm 272.3 \mu\text{m}$  and  $408.2 \pm 379.9 \mu\text{m}$ , respectively, and there was no significant difference between the two groups ( $p=0.98$ ). It is worth noting that the most significant efficacy of BCVA and CFT occurred at 1 month and 3 months, respectively.

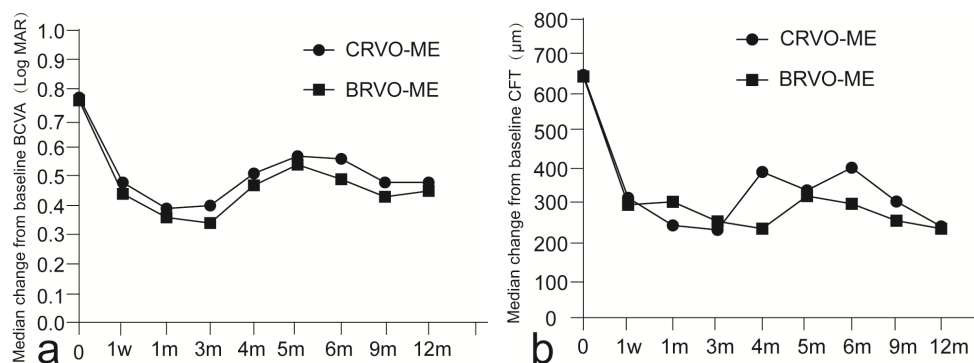


Figure 1. The change of BCVA (a) and CFT (b) during follow-up.

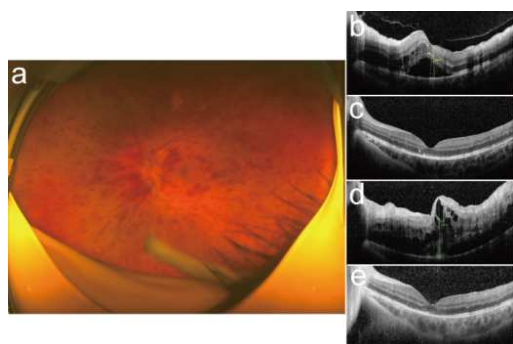


Figure 2. a the fundus of a 19-year-old male patient with CRVO received IVR+DEX treatment; b Before the treatment, decimal BCVA was 0.3; c One month after the first injection, BCVA improved to 0.8; d Recurrence of macular edema and BCVA was 0.05, the reinjection interval was 159 days; e One month after the second injection, BCVA was 0.8 and no further injection during the follow-up.

### 3.4. Safety Analysis

A total of 23 patients had phakic eyes before treatment, among whom 7 cases had cataract deterioration that required surgery (30.4%). Among 10 cases with IOP > 25 mmHg (26.3%), 2 cases had IOP > 35 mmHg (5.3%). The high IOP could be significantly inhibited by topical drugs in patients with IOP > 25 mmHg. Moreover, 90% of high IOP occurred in patients with > 2 injections.

## 4. Discussion

Over recent years, the therapy combining anti-VEGF and Ozurdex® against retinal vein occlusion with macular edema has received increasing attention from ophthalmologists. However, there are still few related studies on combined therapy and a lack of multi-center randomized controlled trials

to guide clinical treatment on the interval of reinjection, the number of injections per year, etc. This study aimed to conduct preliminary discussions on these clinical cases.

In 2019, the European Society of Retina Specialists (EURETINA) recommended that the injection interval of Ozurdex<sup>®</sup> monotherapy should be 3~4 months, with an annual average of 2-3 injection numbers [13]. In this study, the average reinjection interval of the combined therapy (IVR+DEX) was 134 days, which was similar to Singer *et al* [14] study. They first used anti-VEGF injection for 2 weeks and then combined DEX to treat 62 RVO-ME patients, who were followed up for 2 years; the reinjection time was 135 days. In a 3-year follow-up study, the average interval between reinjections of DEX was 4.8 months [15]. A 4-5 month interval between reinjections was significantly more beneficial than anti-VEGF monotherapy. These results also provide the basis for clinical re-treatment time (about 4.5 months). Patients may not need monthly monitoring, and they only receive injections before re-edema to ensure that visual and anatomical treatment goals are maintained, which in turn contributes to better compliance.

In this study, we counted the number of injection needles instead of the times of injections, which was to be convenient for patients to compare the costs of anti-VEGF monotherapy and combination therapy. In order to maintain the best improvement in visual acuity, RVO-ME patients received 8.2-11.8 needles of anti-VEGF per year [11, 16], while the average needles of DEX was only 2-3 per year [13]. Adopting the combination therapy, patients just received an average of 4.2 needles (range 2 to 6 injections) per year, and 65.8% of the patients only received 4 needles per year to maintain good vision improvement and anatomical reduction. Accordingly, combined therapy reduced the number of injection needles and hospitalization, thus also reducing the financial burden of patients and medical institutions.

At the end of the follow-up, 52.6% of patients had improved visual acuity by more than 3 lines, which was similar to the results Singer *et al* [14]. These results were also similar to those of ranibizumab monotherapy (BRVO 60% vs. CRVO 48%~51%) [17, 18], which indicated that the combination of anti-VEGF and DEX treatment enhanced the efficacy of anti-VEGF monotherapy but also required a 4-5 month re-treatment interval. These two drugs complemented each other's strengths. Ranibizumab monotherapy resulted in a mean improvement in CFT of 345–452  $\mu\text{m}$  [17, 18]. Compared with the baseline, the CFT of RVO-ME in Chinese treated with DEX decreased by 407  $\mu\text{m}$  [8]. In this study, the CFT decreased by an average of 400  $\mu\text{m}$  compared with the baseline after combined therapy (IVR+DEX). That might suggested that combined therapy no additive effect compared with monotherapy. However, Singer *et al* [14] reported that combined therapy could only decrease by only 200-219  $\mu\text{m}$  from the baseline [4]. It was not clear whether the differences between the two studies were related to race or geography. In conclusion, the BCVA improvement and CFT reduction in this study remained relatively stable during the 12-month follow-up (Figure 1) without a reduction in efficacy caused by

repeated treatment.

Ranibizumab had a rapid onset of action, and the BCVA and CFT of patients were significantly improved in the first week after the injection. Visual acuity improvement was best at 1 month after combined therapy. In view of the innovative sustained-release technology of DEX, the effect of a single injection could be maintained for 3-6 months. Therefore, the monthly follow-up was not needed in the present study, and the third follow-up was selected 3 months after injection. Once visual acuity decreased more than 2 lines or macular thickness greater than 300  $\mu\text{m}$  or subretinal fluid, intraretinal fluid, etc., patients needed to immediately receive combined treatment once again. About 10% of patients could be clinically cured based on BCVA and CFT after only one injection without recurrence of macular edema in long-term follow-up.

In terms of safety, it was unavoidable that DEX could raise intraocular pressure and increase the risks of cataract. Our results showed that the incidence of high IOP was 26.3%. Still, mild to moderate high IOP could be effectively inhibited by medicine without surgery. The safety data of the initial treatment of DEX showed that the incidence of high IOP was 29.5% in Chinese individuals [8]. Intraocular pressure of 25.0% and 37.1% of the patients who received 2 or more injections of DEX were greater than 25 mmHg [19]. The differences in the incidence of high IOP may be related to the different definitions of high IOP, follow-up time, and the number of injection needles. Cataract surgery rate was similar to other combination therapies and DEX monotherapy [14, 20]. The cataract surgery rate was positively correlated with the number of DEX injections [20].

The present study has certain limitations. First of all, this study was not random, and the choice of therapeutic schedule mainly depended on the patient's wishes and the convenience of follow-up. Second, in most previous studies, patients were about 65 years old, while the average age of the patients in the present study was 53 years old. Lu *et al* [21] showed that patients < 40 years of age with dexamethasone intravitreal implants had better long-term outcomes (greater visual acuity and more CFT reduction) and fewer total injection numbers. However, more controlled studies are needed to confirm whether younger people respond better to hormonal therapy. Third, this is only a retrospective observational study that did not include strict control groups, as is the case with prospective studies. Consequently, future studies are needed to address these shortcomings and find the optimal regimen.

## 5. Conclusion

The initial combined therapy of ranibizumab and Ozurdex<sup>®</sup> against RVO-ME could significantly improve vision and macular edema and decrease economic burden with an injection interval of once every 4.5 months.

## Funding

2021 Guangxi Medical and Health self-funded research project (No. Z20210754).

## Conflict of Interest Statement

All authors declare that they have no conflicts of interest.

## Ethical Approval

This study was approved by the Ethics Committee of Nanning Aier Eye Hospital (approval number: NNAIER2019IRB01). All procedures and interventions followed the tenets of the Helsinki declaration.

## Informed Consent

All patients signed written informed consent.

## References

- [1] Song P, Xu Y, Zha M, et al (2019) Global epidemiology of retinal vein occlusion: a systematic review and meta-analysis of prevalence, incidence, and risk factors. *J Glob Health*. 9 (1): 010427. <https://doi.org/10.7189/jogh.09.010427>
- [2] Wang Q, Yang J, Jonas JB, et al (2021) Prevalence of Retinal Vein Occlusions and Estimated Cerebrospinal Fluid Pressure: The Kailuan Eye Study. *Eye Brain*. 21; 13: 147-156. <https://doi.org/10.2147/EB.S290107>.
- [3] Rehak M, Wiedemann P (2010) Retinal vein thrombosis: pathogenesis and management. *J Thromb Haemost*. 8 (9): 1886-1894. <https://doi.org/10.1111/j.1538-7836.2010.03909.x>.
- [4] Koss MJ, Pfister M, Rothweiler F, et al (2012) Comparison of cytokine levels from undiluted vitreous of untreated patients with retinal vein occlusion. *Acta Ophthalmol*. 90 (2): e98-103. <https://doi.org/10.1111/j.1755-3768.2011.02292.x>.
- [5] Noma H, Funatsu H, Yamasaki M, et al (2005) Pathogenesis of macular edema with branch retinal vein occlusion and intraocular levels of vascular endothelial growth factor and interleukin-6. *Am J Ophthalmol*. 140: 256-261. <https://doi.org/10.1016/j.ajo.2005.03.003>.
- [6] Chang-Lin JE, Attar M, Acheampong AA, et al (2011) Pharmacokinetics and pharmacodynamics of a sustained-release dexamethasone intravitreal implant. *Invest Ophthalmol Vis Sci*. 52: 80-86. <https://doi.org/10.1167/iovs.10-5285>.
- [7] Gu X, Yu X, Song S, et al (2017) Intravitreal Dexamethasone Implant versus Intravitreal Ranibizumab for the Treatment of Macular Edema Secondary to Retinal Vein Occlusion in a Chinese Population. *Ophthalmic Res*. 58 (1): 8-14. <https://doi.org/10.1159/000458534>.
- [8] Li X, Wang N, Liang X, Xu G (2018) Safety and efficacy of dexamethasone intravitreal implant for treatment of macular edema secondary to retinal vein occlusion in Chinese patients: randomized, sham-controlled, multicenter study. *Graefes Arch Clin Exp Ophthalmol*. 256 (1): 59-69. <https://doi.org/10.1007/s00417-017-3831-6>.
- [9] Garay-Aramburu G, Gomez-Moreno A (2018) A 5-Year follow-up study of the treatment of macular edema due to retinal vein occlusion using dexamethasone intravitreal implants. *J Ocul Pharmacol Ther*. 34: 436-441. <https://doi.org/10.1089/jop.2017.0148>
- [10] Sivaprasad, S; Amoaku, WM; Hykin, P, RVO Guideline Group (2015) The Royal College of Ophthalmologists Guidelines on retinal vein occlusions: executive summary. *Eye (Lond)*. 29 (12): 1633-8. <https://doi.org/10.1038/eye.2015.164>.
- [11] Campochiaro PA, Clark WL, Boyer DS, et al (2015) Intravitreal aflibercept for macular edema following branch retinal vein occlusion: the 24-week results of the VIBRANT study. *Ophthalmology*. 122 (3): 538-544. <https://doi.org/10.1016/j.ophtha.2014.08.031>
- [12] Haller JA, Bandello F, Belfort R Jr, et al (2011) Dexamethasone intravitreal implant in patients with macular edema related to branch or central retinal vein occlusion: twelve-month study results. *Ophthalmology*. 118 (12): 2453-2460. <https://doi.org/10.1016/j.ophtha.2011.05.014>
- [13] Schmidt-Erfurth, U, Garcia-Arumi, J, Gerendas, BS, et al (2019) Guidelines for the Management of Retinal Vein Occlusion by the European Society of Retina Specialists (EURETINA). *Ophthalmologica*. 242 (3): 123-162. <https://doi.org/10.1159/000502041>
- [14] Singer MA, Jansen ME, Tyler L, et al (2017) Long-term results of combination therapy using anti-VEGF agents and dexamethasone intravitreal implant for retinal vein occlusion: An investigational case series. *Clin Ophthalmol*. 11: 31-38. <https://doi.org/10.2147/OPTH.S119373>
- [15] Blanc, J; Deschasse, C; Kodjikian, L; et al (2018) Safety and long-term efficacy of repeated dexamethasone intravitreal implants for the treatment of cystoid macular edema secondary to retinal vein occlusion with or without a switch to anti-VEGF agents: a 3-year experience. *Graefes Arch Clin Exp Ophthalmol*. 256 (8): 1441-1448. <https://doi.org/10.1007/s00417-018-4016-7>
- [16] Campochiaro PA, Sophie R, Pearlman J, et al (2014) Long-term outcomes in patients with retinal vein occlusion treated with ranibizumab: the RETAIN study. *Ophthalmology*. 121 (1): 209-219. <https://doi.org/10.1016/j.ophtha.2013.08.03>
- [17] Campochiaro PA, Brown DM, Awh CC, et al (2011) Sustained benefits from ranibizumab for macular edema following central retinal vein occlusion: twelve-month outcomes of a phase III study. *Ophthalmology*. 118 (10): 2041-2049. <https://doi.org/10.1016/j.ophtha.2011.02.038>
- [18] Brown DM, Campochiaro PA, Bhisitkul RB, et al (2011) Sustained benefits from ranibizumab for macular edema following branch retinal vein occlusion: 12-month outcomes of a phase III study. *Ophthalmology*. 118 (8): 1594-1602. <https://doi.org/10.1016/j.ophtha.2011.02.022>
- [19] Singer MA, Capone A Jr, Dugel PU, et al (2015) Two or more dexamethasone intravitreal implants as monotherapy or in combination therapy for macular edema in retinal vein occlusion: subgroup analysis of a retrospective chart review study. *BMC Ophthalmol*. 15: 33. <https://doi.org/10.1186/s12886-015-0018-y>.
- [20] Rajesh B, Zarranz-Ventura J, Fung AT, for International Ozurdex Study Group, et al (2020) Safety of 6000 intravitreal dexamethasone implants. *Br J Ophthalmol*. 104 (1): 39-46. <https://doi.org/10.1136/bjophthalmol-2019-313991>.
- [21] Lu Y, Gu X, Yu X et al (2019) Comparative study of intravitreal dexamethasone implant in the treatment of macular edema secondary to central retinal vein occlusion with different ages. *Chin J Exp Ophthalmol*. 5 (37), 363-368. <https://doi.org/10.3760/cma.j.issn.2095-0160.2019.05.009>.