

Case Report

Endovascular Therapy for Thoracic Aortic Mobile Thrombus

James Gregory Roberts*

Surgical Phronesis, Vascular Surgery, Monterey, United States

Abstract

Thoracic aortic mobile thrombus (TAMT) in the absence of atherosclerosis, traumatic injury, or thrombophilia represents an uncommon but well-acknowledged form of a non-cardiogenic thromboembolic source. The morbidity and mortality of acute visceral thromboembolism from an aortic thrombus remains elevated, though delay in diagnosis is common given its underappreciated source as a potentially catastrophic aetiology. Nomenclature to describe any thromboembolism to abdominal viscera remains varied throughout the literature with a cardiac source from arrhythmias most prevalent. Computerized tomographic angiogram (CTA) of chest and abdomen is the modality that most commonly diagnoses TAMT. Trans-esophageal echocardiography (TEE), however, has been the imaging modality of choice in defining the specific thrombus morphology of TAMT. Patient morbidity and mortality of TAMT may entail devastating thromboembolism to myriad sites: cerebrum, mesentery, renal and upper and/or lower extremity peripheral vasculatures. Risks factors of developing aortic mural thrombus are explored within each case. Herein are two illustrative cases of TAMT presenting with acute peritoneal signs and symptoms of visceral ischemia, respectively involving spleen and kidney in the first, and spleen and intestine, the second case. Both cases were successfully managed by physical examination, CTA-diagnosis, intravascular ultrasound (IVUS) to define the morphology of the aortic thrombus, and subsequent thoracic endovascular aortic repair (TEVAR) graft deployment.

Keywords

Visceral Thromboembolism, Arterial Thromboembolism, Aortic Thrombi, Acute Abdomen

1. Introduction

Symptomatic thoracic aortic embolization in the absence of atherosclerosis, dissection or aneurysmal degeneration rarely occurs in the clinical setting. Historically, Weismann *et al.* posited in 1958 that said large vessel embolization transpires only in the presence of intravenous systemic unfractionated heparin [1]. However, in 1981, Williams *et al.* expanded thoracic aortic mobile thrombus (TAMT) etiology by documenting an aortic thrombus *de novo* in the absence of heparin with normal underlying endothelium. [2] The viscer-

al and peripheral end-organ compromise created by TAMT has prompted various medical and surgical management strategies. From systemic heparinization and thrombolysis to surgical aortotomy, these tactics remained the current trend for several decades. More recently, exclusion of TAMT *via* endovascular stenting has gained credence. A report of two TAMT cases, the first involving splenic and renal infarctions, while the second, mesenteric--intestinal and splenic infarctions, each treated with thoracic endovascular aortic repairs

*Corresponding author: vascular929@gmail.com (James Gregory Roberts)

Received: 20 January 2024; **Accepted:** 19 February 2024; **Published:** 29 February 2024



Copyright: © The Author(s), 2024. Published by Science Publishing Group. This is an **Open Access** article, distributed under the terms of the Creative Commons Attribution 4.0 License (<http://creativecommons.org/licenses/by/4.0/>), which permits unrestricted use, distribution and reproduction in any medium, provided the original work is properly cited.

(TEVAR) will be detailed.

2. Cases Presentation

2.1. Case 1

A healthy 34-year-old Hispanic female presented to the Emergency room with abrupt, acute, bilateral flank and left shoulder pains. Hemodynamic profile of blood pressure, heart rate, saturation was normal. All peripheral pulses were palpable. All serum laboratory values including electrolytes, hepatic panel, lactate acid, urinalysis and complete blood count were normal. CTA abdomen noted bilateral renal and splenic infarctions; further imaging of the thorax revealed descending thoracic aortic mobile thrombus (Figures 1 & 2). Systemic unfractionated heparin was initiated, though despite heparin, the patient's symptoms of abdominal and flank pains persisted prompting concern for further emboli.

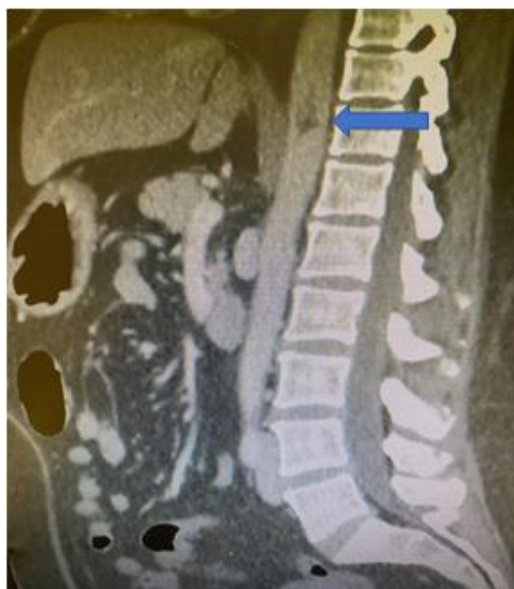

Figure 1. TAMT (Sagittal view).

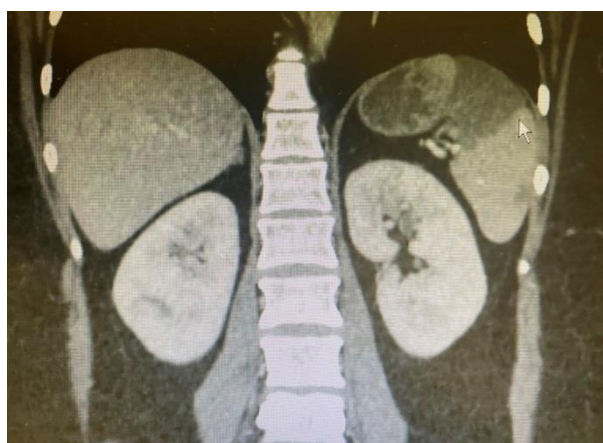

Figure 2. Splenic infarction; bilateral renal infarctions.

Endovascular intervention was considered given patient's reluctance to undergo thoracotomy. That the thrombus origin appeared medially on the descending thoracic aortic wall, a right femoral 5 French access Pinnacle sheath (Terumo®), along with a 0.014" Whisper wire was advanced to the ascending aorta. The Whisper wire biased the lateral aortic wall and did not disturb the medially positioned mobile thrombus. Next, intravascular ultrasound (IVUS) Volcano™, Phillips, Inc. over the Whisper wire delineated the entire aortic thrombus morphology, both on gray scale and color flow using Chromoflo modality (see Figure 3.). The length of the highly mobile thrombus was 7 cm and adjacent aortic wall was normal. Luminal stenosis of 40% was noted by the presence of thrombus.

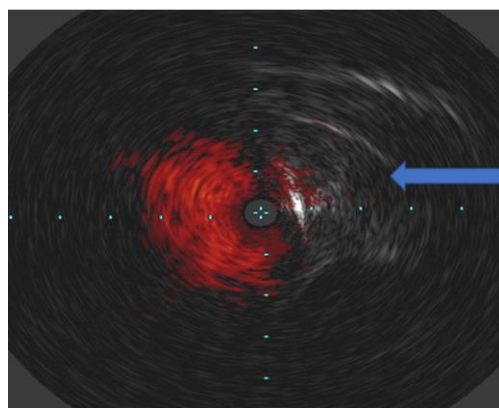


Figure 3. Lateral Thoracic Aortic wall thrombus (~ 50% luminal stenosis), Chromoflo IVUS imaging with luminal compromise 40%.

The 5 French sheath was exchanged for an 18 French, 33 cm Gore Dry sheath. Next, the Whisper wire was exchanged over a 5 Fr straight Glide catheter for a 0.035" Amplatz wire, which permitted deployment of a Gore TAG (21 x 21 mm x 10 cm) TEVAR. Completion IVUS noted no endoleak, adequate graft-to-vessel coaptation and no residual TAMT. Completion visceral and peripheral angiograms were performed noting no further embolization.

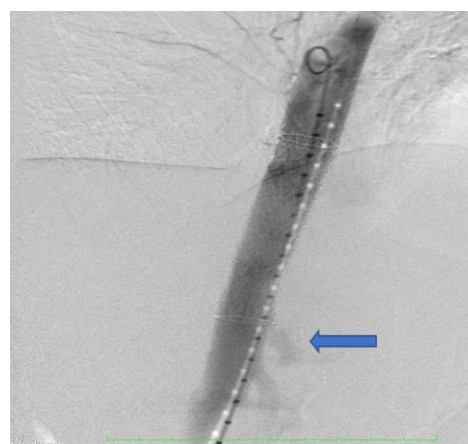


Figure 4. Patent celiac artery at the graft's distal landing zone.

Post-intervention CTA (Figure 5) one month later was performed to assess stent patency and aortic morphology. The TEVAR graft was patent and maintained positioned in the descending thoracic aorta without endoleak, maintained patency of celiac artery (arrow) at its distal landing zone and resolution of TAMT.

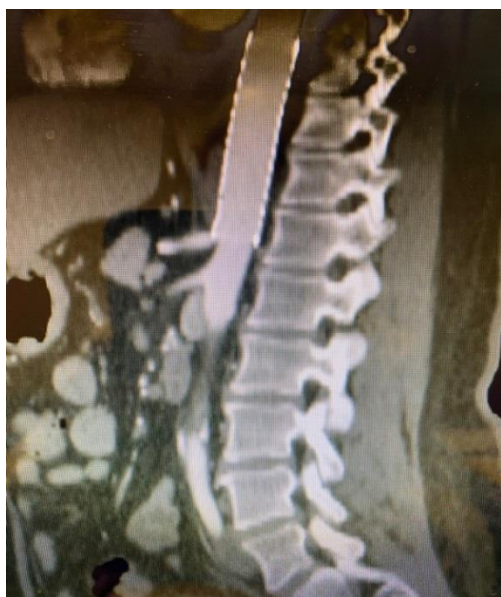

Figure 5. Thoracic Aortic Stent.

2.2. Case 2

A 67-year-old Caucasian female with medical history of stable Crohn's disease without recent steroid use presented to the Emergency room with sudden, acute, and unremitting epigastric and mid-abdominal pains and left flank pains. All peripheral pulses were palpable. Hemodynamic profile noted sinus tachycardia with 118/min and mild hypertension 160/84, low-grade temperature of 99.7 and normal room air saturation 98%. Serum laboratories revealed metabolic lactic acidosis: HCO₃ 16 mEq/L, Lactate 7 mmol/dL. Renal and hepatic function studies were normal. Urinalysis was negative for infection. Complete blood count noted leukocytosis of 18,000/L, and normal hemoglobin 10 g/dL and platelet counts 385,000/L. A CTA of thorax, abdomen and pelvis was performed: pneumoperitoneum, intestinal pneumatosis, and a descending thoracic aortic mobile thrombus. Enoxaparin sodium 1 mg/kg dosing preceded exploratory laparotomy. Intra-operative findings of ischemic distal jejunum mandated stapled resection without reconstitution. Inspection of the spleen noted intact capsule and mild pulp upper pole atrophy with a normal splenic arterial pulse. No overt peritoneal contamination was observed, but cultures were obtained. Copious amounts of irrigation were utilized. An ABTHERA ADVANCE™ device for temporary abdominal closure was applied in anticipation of a second look procedure and complete intestinal continuity 48 hours later. The patient was

maintained on mechanical ventilation and chemical paralysis for three days. Systemic anticoagulation with unfractionated heparin, broad spectrum antibiotics and intravenous hydration were maintained. The leukocytosis (16,000/L to 9,000/L) resolved within 24 hours, as did the acid-base disturbance (lactate 1.5 mmol/dL; HCO₃ 26 mEq/L). The following day, the patient underwent percutaneous thoracic and abdominal aortogram via right common femoral arterial access with a 5 French Pinnacle sheath (Terumo®), then via two Perclose™ devices was upsized to an 18 French, 33 cm Gore Dry™ sheath, while a 0.014" Whisper wire was advanced to the aortic valve. Intravascular ultrasound (IVUS) Volcano®, Phillips, Inc. assessed the thoracic aorta with both gray scale (see Figure 6) and color flow modalities. The length of the highly mobile thrombus was 6 cm and adjacent aortic wall was normal. Luminal stenosis was 30% along aortic wall.

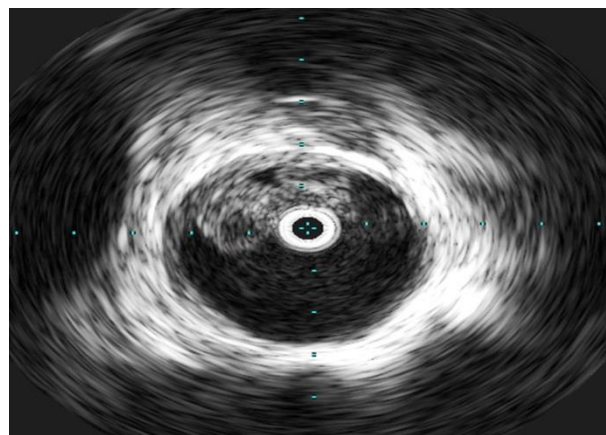


Figure 6. Mobile thrombus in the thoracic aorta demonstrating both hyper- and hypo-echogenicity along medial aortic wall.

A TAG device (21 x 21 mm x 10 cm) was then deployed. Completion IVUS noted resolution of TAMT and adequate of graft-to-vessel coaptation. Completion visceral and peripheral angiograms were performed noting normal perfusion.

On the third day, the patient returned to the operating theater and underwent a second look procedure. No further embolization transpired post-TEVAR. Then, both the jejunal end-to-end stapled anastomosis and abdominal closure proceeded uneventfully. The patient was extubated immediately post-operatively without complication. All cultures, blood, and peritoneal fluid were deemed negative. Systemic intravenous antibiotics continued for 10 days from admission, then oral Ciprofloxacin for a week completed treatment. Subsequent CTA a month later noted no further TAMT and stable TEVAR graft.

3. Discussion

Visceral thromboembolic events may precipitate severe morbidity and mortality. Cryptogenic thromboembolic

sources are disappearing given the advancements of imaging technology such CT angiography (CTA). Thoracic aortic mobile thrombus remains rare a clinical presentation but is incrementally being diagnosed by CTA. The incidence of TAMT is not well known, however, Machleder *et al.* noted in 10,671 autopsies an incidence of 0.45% of thoracic aortic mural thrombus (48 cases), eight of which evinced evidence of embolization. [3]

Yet multiple nomenclatures of thoracic aortic thrombus have been utilized in the literature: TAMT (thoracic aortic mobile thrombus) [3, 9, 10]; PAMT (primary aortic mural thrombus) [5]; AAT (atypical aortic thrombus) [6]; AMT (aortic mural thrombus) [7]. That thrombus “mobility” describes the mechanism of embolization, standardization of nomenclature of aortic thrombus would improve its delineation of global incidence. Moreover, Criado *et al.*, credited with the first case report in the vascular literature, described this thromboembolic presentation as “thoracic aortic mobile thrombi.” [8]

The pathophysiology of the thrombus remains uncertain. Contributors to non-atherosclerotic thrombus formation include iron deficient anemia [12], thrombophilia, autoimmune and neoplastic diseases, and endothelial injury. To this point, Williams *et al.* remarked during an open aortotomy “Once the thrombotic material was removed, the aortic wall was smooth in the majority of cases.” [2] Siani *et al.*, however, have documented mobile thrombus adherent to “atherosclerotic plaque with a small flap” within the descending thoracic aorta. [9]

Imaging of TAMT typically utilizes transthoracic echocardiography (TEE). Yet, as illustrated in these cases, IVUS provides the degree of thrombus echogenicity (hyper- vs. hypo-echoic), length of thrombus, mobility, adjacent endothelial abnormalities, and luminal compromise by thrombus burden. Each patient presented exhibited highly mobile thrombus and normal endothelium. Neither thrombophilia, nor malignancy was noted in both patients. The patient with Crohn’s disease was stabilized on dietary restriction and last had steroids over a decade previously.

Verma *et al.* using PAMT nomenclature proposed an algorithm of treatment options wherein the descending thoracic aorta is labeled IIa and IIb, which described 42% of the patient profiles. [5] To this design, both patient cases harbored thrombus extending between IIa and IIb, that is, originating in thoracic aorta distal to the left subclavian artery and proximal to the celiac artery.

Diverse opinions on management of TAMT create no consensus on treatment options ranging from systemic anticoagulation, thrombolysis, thrombo-aspiration to surgical intervention including aortotomy with thrombectomy and aortic interposition graft. Yet the endovascular technique using covered stent grafts has been performed more recently without complications in this subset of descending thoracic aortic mobile thrombus patients. Intercostal arterial coverage with resultant paraplegia and the potential need for spinal drainage has not been born out to date, though strategies to miti-

gate it include uninterrupted anticoagulation, avoidance of hypotension, and assurance of internal iliac arterial patencies. No neurologic sequelae transpired in either case presented. The TEVAR grafts, with their 10 cm coverage, resolved the issue of the mobile thrombus, as well as any adjacent aortic wall abnormality not fully appreciated on imaging. Endovascular stenting for TAMT has been successfully performed by Boufi *et al.*, Borghese *et al.*, Piffaretti *et al.* and Fueglistaler *et al.*, each of whom proffer an aggressive approach to TAMT management after embolization occurred, rather than systemic anticoagulation as first line treatment. [4, 7, 10, 11] Future studies of this potentially life-threatening vascular pathology will clarify the role of endovascular versus surgical treatment options.

4. Conclusion

Thoracic aortic mobile thrombus (TAMT) represents an overlooked aetiology of visceral thromboembolism in the past. Advances in CTA of thoracic and abdominal imaging are enhancing prompt physician diagnosis of TAMT. Although still controversial, TEVAR for TAMT as these two cases demonstrate provides resolution of the thromboembolic threat with low surgical morbidity and mortality. Further study in the morphology of aortic mural thrombus and its precise aetiology, along with a treatment algorithm is recommended.

Abbreviations

TAMT: Thoracic Aortic Mobile Thrombus
PAMT: Primary Aortic Mural Thrombus
AMT: Aortic Mural Thrombus
AAT: Atypical Aortic Thrombus
TEVAR: Thoracic Endovascular Aortic Repair
IVUS: Intra-Vascular Ultrasound
TEE: Trans-Esophageal Echocardiography
CTA: Computerized Tomographic Angiogram

Conflicts of Interest

The author declares no conflicts of interests.

References

- [1] Weismann RE, Tobin RE. Arterial embolism occurring during systemic heparin therapy. *Arch Surg* 1958; 76: 219-227.
- [2] Williams GM, Harrington D, Burdick, J, White, RI. Mural Thrombus of the Aorta: An important, Frequently Neglected Cause of Large Peripheral Emboli. *Ann Surg* 1981; 194 (6): 737-744.
- [3] Machleder HI, Takiff H, Lois JF, Holburt E. Aortic Mural Thrombus: an occult source of arterial thromboembolism. *J Vasc Surg.* 1986; 4: 473-478.

- [4] Boufi M, Mameli A, Compes P, Hartung O, Alimi YS. Elective Stent-graft Treatment for the Management of Thoracic Aorta Mural Thrombus. *Eur J Vasc Endovasc Surg* 2014; 47 (4): 335-341.
- [5] Verma H, Meda N, Vora S, George RK, Tripathi RK. Contemporary Management of Symptomatic Primary aortic Mural Thrombus. *J Vasc Surg* 2014; 60: 1524-1534.
- [6] Turley RS, Unger J, Cox MW, Lawson J, McCann RL, Shortell C. Atypical Aortic Thrombus: Should Nonoperative Management Be First Line? *Ann Vasc Surg* 2014; 28(7): 1610-1617.
- [7] Borghese O, Pisani A, Di Centa. Symptomatic Aortic Mural Thrombus Treatment and Outcomes. *Ann Vasc Surg* 2020; 69: 373-381.
- [8] Criado E, Wall P, Lucas P, Gasparis A, Profitt T, Ricotta J. Transesophageal echo-guided endovascular exclusion of thoracic aortic mobile thrombi. *J Vasc Surg* 2004; 39: 238-242.
- [9] Siani A, Accrocca F, De Vivo G, Mounayergi F, Marcucci G. Endovascular Treatment of Symptomatic Thrombus of the Descending Thoracic Aorta. *Ann Vasc Surg* 2016; 36: 295e13-16.
- [10] Piffaretti G, Tozzi M, Mariscalco G, Bacuzzi A, Lomazzi C, Rivolta N, Carrafiello G, Castelli P. Mobile Thrombus of the Thoracic Aorta: management and Treatment Review. *Vasc Endovasc Surg* 2008; 42(5): 405-411.
- [11] Fueglistaler P, Wolff T, Guerke L, Stierli P, Eugster T. Endovascular stent graft for symptomatic mobile thrombus of the thoracic aorta. *J Vasc Surg* 2005; 42: 781-783.
- [12] Bukharovich IF, Wever-Pinzon O, Shah A, Todd G, Chaudhry FA, Sherrid MV. Echocardiography 2012; 29(3): 369-372.