

Implications of Arterial Variations in Pancreatoduodenectomy for Cancer

Silvio Marcio Pegoraro Balzan^{1,2,3,*}, Vinicius Grando Gava³, Érika Luiza Maschio¹,
Victoria Lucateli Bernardi¹, Giana da Silva Lima¹, Graziela de Gasperi¹,
Morgana Pizzolatti Marins¹, Vanessa Batistella Kunzler¹, Bruna Aparecida Fontana Costa¹

¹Department of Biology and Pharmacy (Liga Acadêmica do Cancer), University of Santa Cruz do Sul (UNISC), Santa Cruz do Sul, Brazil

²Saint Gallen Institute of Oncology, Santa Cruz do Sul, Brazil

³Oncology Center Lydia Wong Ling (Moinhos de Vento Hospital), Porto Alegre, Brazil

Email address:

sbalzan@hotmail.com (S. M. P. Balzan)

*Corresponding author

To cite this article:

Silvio Marcio Pegoraro Balzan, Vinicius Grando Gava, Érika Luiza Maschio, Victoria Lucateli Bernardi, Giana da Silva Lima, Graziela de Gasperi, Morgana Pizzolatti Marins, Vanessa Batistella Kunzler, Bruna Aparecida Fontana Costa. Implications of Arterial Variations in Pancreatoduodenectomy for Cancer. *Journal of Surgery*. Vol. 8, No. 1, 2020, pp. 5-8. doi: 10.11648/j.js.20200801.12

Received: November 10, 2019; **Accepted:** January 2, 2020; **Published:** January 17, 2020

Abstract: Pancreatoduodenectomy for cancer is a complex surgical procedure with significant morbidity and mortality. Technical aspects of this procedure typically comprise dissection of celiac trunk, the common and the proper hepatic arteries. The presence of hepatic arterial anomalies is not uncommon and influences surgical technique. An aberrant right hepatic artery (replaced or accessory) or a common hepatic artery originating from the superior mesenteric artery are present in nearly 13% of cases and usually run in contact with the posterior aspect of the head of the pancreas. These anomalous arteries are at risk of iatrogenic injury and tumor involvement. Iatrogenic vascular lesions can lead to bleeding and/or ischemic complications, such as anastomotic stenosis, hepatic abscess and liver failure. Also, vascular tumor involvement might require arterial resection and reconstruction. The presence of arterial variations should not affect the radicalness of pancreatic resection as the involvement of aberrant arteries does not seem to affect postoperative outcomes or overall survival. These vascular variations should be, preferably, recognized pre-operatively in order to define possible surgical strategies. Preoperative contrast enhanced computed tomography provides accurate arterial anatomy evaluation. Lastly, aberrant hepatic arteries require proper dissection and/or occasionally resection and reconstruction during pancreatoduodenectomy to achieve a safe resection with proper radicalness. Knowledge of arterial variations is crucial for pancreatic cancer surgery.

Keywords: Pancreatic Cancer, Pancreatoduodenectomy, Arterial Variations, Pancreatic Surgery

1. Introduction

Pancreatoduodenectomy (PD) is the main surgical technique for the treatment of periampullary tumors. [1] Despite technical advances in pancreatic surgery, PD remains a challenging procedure with mortality rates from 1% to 6%. [1–5] Some arterial variations can be of major surgical significance during PD for cancer. Recognition of such anomalies is of major importance to avoid iatrogenic vascular lesions with consequent bleeding or ischemia of structures or organs leading to possible anastomotic stenosis (such as

biliary or pancreatic anastomosis), hepatic abscess, or even liver failure. Additionally, tumor involvement of aberrant arteries might demand vascular resection and reconstruction. [6]

The main arterial variations presenting clinical implications in PD for cancer are those concerning liver arterial blood supply, i.e. abnormal hepatic arteries. [7, 8]

Knowledge of the range of arterial anomalies during PD prevents intraoperative and postoperative complications and allows the use of appropriate oncological surgical techniques, leading to better oncological results.

2. Pancreatoduodenectomy and Arterial Variations

Pancreatoduodenectomy was first described by Whipple *et al.* [9] in 1935. Despite several modern technical modifications, PD remains a complex procedure. Pancreatoduodenectomy comprises dissection of common and proper hepatic arteries and dissection and section of the gastroduodenal artery in its origin. Pancreatoduodenectomy for cancer usually includes lymphadenectomy of the common hepatic artery and celiac trunk. Also, pancreatic arterial branches from superior mesenteric artery are ligated and sectioned during retroportal pancreatic lamina section. [10, 11]

Following normal development, common hepatic artery arises from celiac trunk and it continues as the proper hepatic artery after giving origin to the gastroduodenal artery. The proper hepatic artery usually originates the right and the left hepatic arteries before reaching the hepatic parenchyma. The superior mesenteric artery usually provides branches to pancreatic head and middle gun. However, this regular arterial pattern is present in only 62% to 90% of patients. [12–16] Thus, anatomical arterial variations of the hepatic arterial system are quite frequent. The most used classification for these variations was that proposed by Hiatt

[17] in 1994, as described in Table 1.

Table 1. Hiatt classification of hepatic arterial supply.

Type	Description	Percent
1	Normal	75.7
2	Replaced or accessory LHA	9.7
3	Replaced or accessory RHA	10.6
4	Replaced or accessory RHA and replaced or accessory LHA	2.3
5	CHA from SMA	1.5
6	CHA from aorta	0.2

LHA, left hepatic artery. RHA, right hepatic artery. CHA, common hepatic artery. SMA, superior mesenteric artery.

The mains arterial variations with potential implications during a PD was investigated in a recent large study and prevalence of standard and aberrant patterns. [6] The presence of a right hepatic artery (replaced or accessory) or a common hepatic artery originating from the superior mesenteric artery were considered as the main variations requiring special caution or modifications during pancreatoduodenectomy. [6] In that study, anomalous right hepatic artery was found in 13% of cases with 6% having a replaced aberrant right hepatic artery (Figure 1).

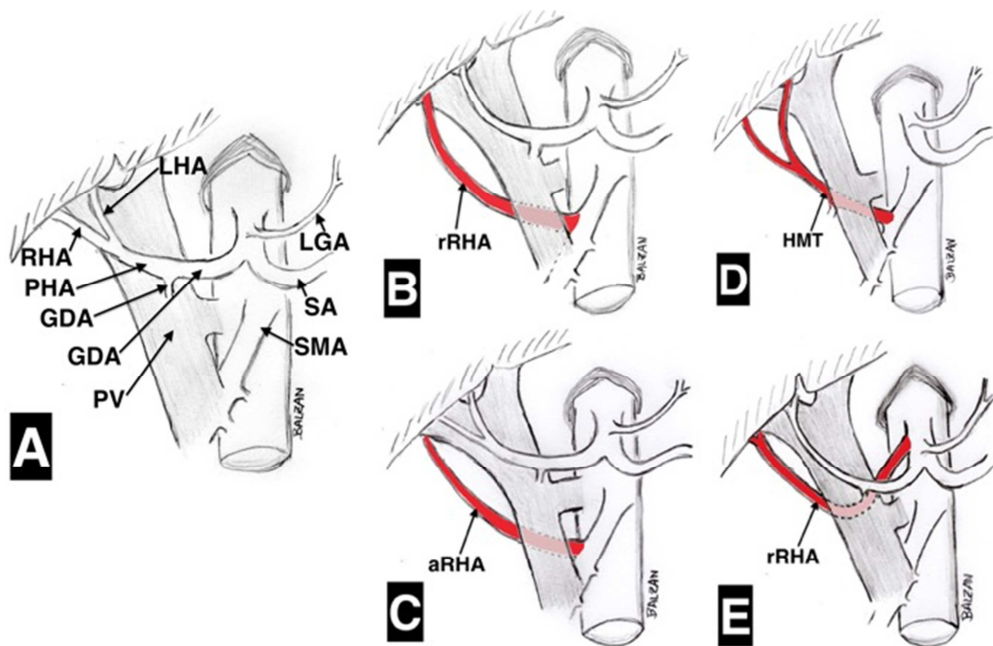


Figure 1. Schematic representation of hepatic arterial system variations with implications in pancreatoduodenectomy. A) standard arterial anatomy; B) replaced right hepatic artery from superior mesenteric artery (prevalence 6%); C) accessory right hepatic artery from superior mesenteric artery (prevalence 1%); D) right hepatic artery from hepatomesenteric trunk (prevalence 3.5%); E) replaced right hepatic artery from celiac trunk (prevalence 2.5%). Modified from Balzan *et al.* [6] LHA, left hepatic artery. RHA, right hepatic artery. PHA, proper hepatic artery. GDA, gastroduodenal artery. PV, portal vein. LGA, left gastric artery. SA, splenic artery. SMA, superior mesenteric artery. rRHA, replaced right hepatic artery. aRHA, accessory right hepatic artery. HMT, hepatomesenteric trunk.

An aberrant right hepatic artery typically runs upward behind the head of the pancreas and is often in contact with the posterior aspect of the pancreas and lateral and posterior aspect of the portal vein trunk. Rarely its course is prepancreatic. [18, 19]

All these abnormal arteries and its courses are accurately

recognizable in preoperative contrast enhanced computed tomography. Thus, cautious preoperative imaging evaluation allows adequate surgical strategies.

2.1. Vascular Injury of Abnormal Hepatic Arteries

Ligation of a hepatic artery may result in life-threatening

complications such as hepatic necrosis, liver abscesses, ischemic biliary injury, and anastomotic fistula. [20, 21] Thus, except in some cases of accessory vessels, ligation of aberrant hepatic arteries should be avoided.

A variant technique of PD that beginning with the dissection of the origin of the superior mesenteric artery above the left renal vein and section of the retroportal pancreatic lamina could be useful to a secure dissection of the superior mesenteric artery and safe identification of main arterial anatomic variations. [22–24] This approach could prevent lesions of anomalous arteries not identified preoperatively.

2.2. Tumoral Involvement of Anomalous Arteries

The radicality of PD for cancer is crucial. Dissection of an aberrant hepatic artery far from the pancreas is possible with no radicality compromising if the artery is not involved by the tumor. This is a technically demanding procedure but could avoid vascular reconstruction. Arterial resection and reconstruction may be necessary in case of tumor encasement or intra-pancreatic course of the anomalous hepatic artery. The presence of arterial variations should not affect the radicality of pancreatic resection and involvement of aberrant arteries seems does not affect postoperative outcomes or overall survival. [25–27] Despite it is not clear if the involvement of aberrant hepatic arteries has the same clinical impact than involvement of normal arteries, resection of a tumor involved anomalous right hepatic artery is acceptable. [8, 25, 28]

2.3. Arterial Reconstruction in Pancreatoduodenectomy for Cancer

Despite of most cases of PD for cancer does not require arterial resection, if an anomalous hepatic artery is found to be encased with tumor the usual option is resection and reconstruction. According to the length of vessel resection and its diameter, an end-to-end anastomosis is performed. Also, the distal segment can be anastomosed to other arteries, such as the sectioned gastroduodenal artery or even splenic artery. [29, 30] An alternative to reconstruction is to perform preoperative angiographic embolization of the artery to be ligated. This procedure should allow collateralization and prevent hepatic ischemia. [8, 31, 32]

3. Conclusion

Arterial anomalies, mainly of hepatic arteries, are not uncommon and can result in vascular involvement by pancreatic tumors and increase the risk of vascular injury during pancreatoduodenectomy. Tumor involvement of aberrant arteries around the pancreas can make pancreatoduodenectomy a procedure even more complex, especially if arterial resection and reconstruction are necessary. Thus, arterial variations may require a change in the surgical approach to achieve an adequate and safe resection. Precise preoperative knowledge of such anomalies

is helpful for proper surgical planning.

References

- [1] Reames BN, Blair AB, Krell RW, Groot VP, Gemenetis G, Padussis JC, et al. Management of Locally Advanced Pancreatic Cancer. *Ann Surg* 2019; 1. <https://doi.org/10.1097/SLA.0000000000003568>.
- [2] Noussios G, Dimitriou I, Chatzis I, Katsourakis A. The Main Anatomic Variations of the Hepatic Artery and Their Importance in Surgical Practice: Review of the Literature. *J Clin Med Res* 2017; 9: 248–52. <https://doi.org/10.14740/jocmr2902w>.
- [3] Narayanan S, Martin AN, Turrentine FE, Bauer TW, Adams RB, Zaydfudim VM. Mortality after pancreaticoduodenectomy: assessing early and late causes of patient death. *J Surg Res* 2018; 231: 304–8. <https://doi.org/10.1016/j.jss.2018.05.075>.
- [4] Pallisera A, Morales R, Ramia JM. Tricks and tips in pancreatoduodenectomy. *World J Gastrointest Oncol* 2014; 6: 344–50. <https://doi.org/10.4251/wjgo.v6.i9.344>.
- [5] Sabesan A, Gough BL, Anderson C, Abdel-Misih R, Petrelli NJ, Bennett JJ. High volume pancreaticoduodenectomy performed at an academic community cancer center. *Am J Surg* 2018. <https://doi.org/10.1016/j.amjsurg.2018.10.041>.
- [6] Balzan SMP, Gava VG, Pedrotti S, Magalhães MA, Schwengber A, Dotto ML, et al. PREVALENCE OF HEPATIC ARTERIAL VARIATIONS WITH IMPLICATIONS IN PANCREATODUODENECTOMY. *Arq Bras Cir Dig* 2019; 32: e1455. <https://doi.org/10.1590/0102-672020190001e1455>.
- [7] Koops A, Wojciechowski B, Broering DC, Adam G, Krupski-Berdien G. Anatomic variations of the hepatic arteries in 604 selective celiac and superior mesenteric angiographies. *Surg Radiol Anat* 2004; 26: 239–44. <https://doi.org/10.1007/s00276-004-0229-z>.
- [8] Alexakis N, Bramis K, Toutouzas K, Zografos G, Konstadoulakis M. Variant hepatic arterial anatomy encountered during pancreatoduodenectomy does not influence postoperative outcomes or resection margin status: A matched pair analysis of 105 patients. *J Surg Oncol* 2019; 119: 1122–7. <https://doi.org/10.1002/jso.25461>.
- [9] Whipple AO, Parsons WB, Mullins CR. TREATMENT OF CARCINOMA OF THE AMPULLA OF VATER. *Ann Surg* 1935; 102: 763–79.
- [10] Patel H, Chaudhary N, Nundy S. Pancreaticoduodenectomy: Techniques and controversies. *Curr Med Res Pract* 2014; 4: 274–83. <https://doi.org/10.1016/j.cmrp.2014.11.007>.
- [11] Malgras B, Ezanno AC, Dokmak S. Lymphadenectomy of the hepatic pedicle during hepato-pancreato-biliary surgery. *J Visc Surg* 2018; 155: 219–22. <https://doi.org/10.1016/j.jvisurg.2018.03.015>.
- [12] Marco-Clement I, Martinez-Barco A, Ahumada N, Simon C, Valderrama JM, Sanudo J, et al. Anatomical variations of the celiac trunk: cadaveric and radiological study. *Surg Radiol Anat* 2016; 38: 501–10. <https://doi.org/10.1007/s00276-015-1542-4>.

- [13] SANTOS PV dos, BARBOSA ABM, TARGINO VA, SILVA N de A, SILVA YC de M, BARBOSA F, et al. ANATOMICAL VARIATIONS OF THE CELIAC TRUNK: A SYSTEMATIC REVIEW. ABCD Arq Bras Cir Dig (São Paulo) 2018; <https://doi.org/10.1590/0102-672020180001e1403>.
- [14] Zagyapan R, Kurkcuoglu A, Bayraktar A, Pelin C, Aytekin C. Anatomic variations of the celiac trunk and hepatic arterial system with digital subtraction angiography. Turkish J Gastroenterol 2015; 25: 104–9. <https://doi.org/10.5152/tjg.2014.5406>.
- [15] Ferrari R, De Cecco CN, Iafrate F, Paolantonio P, Rengo M, Laghi A. Studio sulla variabilità anatomica del tripode celiaco e delle arterie mesenteriche mediante angiografia con TC spirale multistrato a 64 strati. Radiol Medica 2007; 112: 988–98. <https://doi.org/10.1007/s11547-007-0200-2>.
- [16] Agarwal S, Pangtey B, Vasudeva N. Unusual variation in the branching pattern of the celiac trunk and its embryological and clinical perspective. J Clin Diagnostic Res 2016; 10: AD05–7. <https://doi.org/10.7860/JCDR/2016/19527.8064>.
- [17] Hiatt JR, Gabbay J, Busuttil RW. Surgical anatomy of the hepatic arteries in 1000 cases. Ann Surg 1994; 220: 50–2.
- [18] Crețu OM, Hut EF, Dan RG, Munteanu M, Totolici BD, Andercou OA. Replaced common hepatic artery originating from the superior mesenteric artery and prepancreatic, anterior course in a patient with cephalic pancreaticoduodenectomy - case report. Rom J Morphol Embryol 2017; 58: 553–6.
- [19] Huang Y, Liu C, Lin J. Clinical significance of hepatic artery variations originating from the superior mesenteric artery in abdominal tumor surgery. Chin Med J (Engl) 2013; 126: 899–902.
- [20] Kleive D, Sahakyan MA, Khan A, Fosby B, Line PD, Labori KJ. Incidence and management of arterial injuries during pancreatectomy. Langenbeck's Arch Surg 2018; 403: 341–8. <https://doi.org/10.1007/s00423-018-1666-1>.
- [21] Sánchez AM, Tortorelli AP, Caprino P, Rosa F, Menghi R, Quero G, et al. Incidence and Impact of Variant Celiacomesenteric Vascularization and Vascular Stenosis on Pancreatic Surgery Outcomes: Personal Experience. Am Surg 2018; 84: 181–7.
- [22] Pessaux P, Regenet N, Arnaud JP. [Resection of the retroportal pancreatic lamina during a cephalic pancreaticoduodenectomy: first dissection of the superior mesenteric artery]. Ann Chir 2003; 128: 633–6.
- [23] Rose JB, Rocha F, Alseidi A, Helton S. Posterior “superior mesenteric artery first” approach for resection of locally advanced pancreatic cancer. Ann Surg Oncol 2014; 21: 1927–8. <https://doi.org/10.1245/s10434-013-3431-6>.
- [24] Sanjay P, Takaori K, Govil S, Shrikhande S V, Windsor JA. {textquotefirst}Artery-first{textquoteright} approaches to pancreaticoduodenectomy. Br J Surg 2012; 99: 1027–35. <https://doi.org/10.1002/bjs.8763>.
- [25] Eshuis WJ, Olde Loohuis KM, Busch ORC, van Gulik TM, Gouma DJ. Influence of aberrant right hepatic artery on perioperative course and longterm survival after pancreaticoduodenectomy. HPB 2011; 13: 161–7. <https://doi.org/10.1111/j.1477-2574.2010.00258.x>.
- [26] Kim PTW, Temple S, Atenafu EG, Cleary SP, Moulton C-A, McGilvray ID, et al. Aberrant right hepatic artery in pancreaticoduodenectomy for adenocarcinoma: impact on resectability and postoperative outcomes. HPB (Oxford) 2014; 16: 204–11. <https://doi.org/10.1111/hpb.12120>.
- [27] Sulpice L, Rayar M, Paquet C, Bergeat D, Merdrignac A, Cunin D, et al. Does an aberrant right hepatic artery really influence the short- and long-term results of a pancreaticoduodenectomy for malignant disease? A matched case-controlled study. J Surg Res 2013; 185: 620–5. <https://doi.org/10.1016/j.jss.2013.07.015>.
- [28] Yoshida T, Matsumoto T, Morii Y, Aramaki M, Matsumoto S, Mori H, et al. Implications of arterial anatomy in patients with cancer of the periampullary region. Hepatogastroenterology n.d.; 52: 8–12.
- [29] Lai ECS. Vascular resection and reconstruction at pancreaticoduodenectomy: Technical issues. Hepatobiliary Pancreat Dis Int 2012; 11: 234–42. [https://doi.org/10.1016/S1499-3872\(12\)60154-4](https://doi.org/10.1016/S1499-3872(12)60154-4).
- [30] Perwaiz A, Singh A, Singh T, Chaudhary A. Incidence and management of arterial anomalies in patients undergoing pancreaticoduodenectomy. JOP 2010; 11: 25–30.
- [31] Taguchi M, Sata N, Kaneda Y, Koizumi M, Hyodo M, Lefor AK, et al. Preoperative segmental embolization of the proper hepatic artery prior to pylorus-preserving pancreaticoduodenectomy: A case report. Int J Surg Case Rep 2015; 8C: 62–7. <https://doi.org/10.1016/j.ijscr.2015.01.029>.
- [32] Cloyd JM, Chandra V, Louie JD, Rao S, Visser BC. Preoperative embolization of replaced right hepatic artery prior to pancreaticoduodenectomy. J Surg Oncol 2012; 106: 509–12. <https://doi.org/10.1002/jso.23082>.