

# One-Stage Hybrid Breast Reconstruction with Inflatable Saline Implants: Minimizing the Need for Major Revision Surgery

Anna Zhou, Peter Deptula, Pooja Yesantharao, Irene Ma, Dung Nguyen\*

Division of Plastic and Reconstructive Surgery, Stanford University Medical Center, Stanford, USA

**Email address:**

nguyendh@stanford.edu (D. Nguyen)

\*Corresponding author

**To cite this article:**

Anna Zhou, Peter Deptula, Pooja Yesantharao, Irene Ma, Dung Nguyen. One-Stage Hybrid Breast Reconstruction with Inflatable Saline Implants: Minimizing the Need for Major Revision Surgery. *Journal of Surgery*. Vol. 9, No. 6, 2021, pp. 256-263.

doi: 10.11648/j.js.20210906.12

**Received:** August 3, 2021; **Accepted:** August 12, 2021; **Published:** November 10, 2021

---

**Abstract:** Autologous breast reconstruction is an appealing choice for breast cancer undergoing mastectomy. Evaluating for adequate donor tissue volume is a highly subjective process with potentials for miscommunication. It is not uncommon for patients to desire significant augmentation of their autologous breast reconstruction with delayed insertion of an implant. However, flap elevation in the pre-pectoral plane can be treacherous. Our novel technique combines autologous abdominal free flaps with immediate pre-pectoral adjustable saline implants to provide a customizable, single-stage strategy. A retrospective review of patients undergoing breast reconstruction with abdominal free tissue transfer and either immediate placement of adjustable saline implants or delayed placement of implants for augmentation was performed. Patient characteristics, operative details and complications were recorded. Complications, patient satisfaction and ability to achieve goal breast size was compared between the immediate adjustable saline implant group and delayed implant placement group. Twenty-four patients (41 breasts) were identified and met inclusion criteria. Sixteen patients received implants in a delayed manner (28 breasts), while 8 received adjustable saline implants immediately with flap reconstruction (13 breasts). High patient satisfaction with breast size and shape was noted across both cohorts. Nearly all patients across both cohorts believed that it was beneficial to be able to adjust breast volumes post-reconstruction. Immediate saline implant placement was demonstrated to increased odds of patient-reported satisfaction by multivariable analysis. A single-stage hybrid approach breast reconstruction with a pre-pectoral adjustable saline implant and abdominal free flap is feasible. This novel technique reduces the rate of major revision surgery and optimizes patient satisfaction in autologous breast reconstruction.

**Keywords:** Autologous Breast Reconstruction, Adjustable Implant, Hybrid Reconstruction, Revision Breast Surgery

---

## 1. Introduction

Autologous breast reconstruction is an appealing choice for breast cancer undergoing mastectomy. It is associated with higher patient satisfaction overall, greater psychosocial well-being, and superior sexual well-being. [1, 2] However, not all patients are candidates for autologous reconstruction due to insufficient donor tissue for the patient's preferred breast size. Evaluating for adequate donor tissue volume is a highly subjective process with potentials for miscommunication. Breast cup size is variable and not standardized, yet it is typically how the patient communicates

their preferred breast size. While these estimates are sometimes sufficient in achieving the patient's goals, an increasing number of patients have returned seeking augmentation at the time of their elective breast reconstruction revisions surgeries.

Elective breast reconstruction revisions are commonly performed. These revisions range from simple procedures such as fat grafting to correct asymmetries to complex procedures with re-elevation of mastectomy skin flaps and mobilization of the underlying flap to adjust breast shape and size. For patients who desire significant augmentation of their autologous breast reconstruction, delayed insertion of an

implant can be performed. However, flap elevation in the pre-pectoral plane is treacherous with potential for pedicle damage leading to loss of the entire reconstruction. Subpectoral implant insertion is associated with increased discomfort, animation deformity, and risk of implant bottoming out over time as the pectoral muscle pushes the implant inferiorly and laterally. Neither option for delayed implant placement is ideal.

A hybrid approach augmenting autologous breast reconstruction with implant at the time of flap surgery is a solution to the resolve mismatch between donor site volume and desired breast volume. The implant can be placed in the sub-pectoral or pre-pectoral position, secured with or without acellular dermal matrices, and combined with the gamut of free flaps. [3-5] Rates of postoperative complications are comparable to the standard reconstruction practice. However, up to 13% of patients underwent implant exchange with placement of a larger implant after initial hybrid flap with implant reconstruction. [3, 4] This high implant exchange rate demonstrates the how difficult it can be to match patient expectations.

To address this reconstructive challenge, our authors propose a hybrid approach utilizing an autologous based reconstruction with immediate placement of an adjustable saline implant. Expandable saline implants are commonly used in breast augmentation, but have been proposed as a technique for single stage breast reconstruction as well. [6-8] Widespread adoption was initially limited by postop complications such as rippling, implant infection, and capsular contracture requiring reoperation. However, these complications can be minimized with improved soft tissue coverage provided by a free flap and use of acellular dermal matrices. [6, 7, 9-12] Adjustable implant placement allows for a customizable approach, allowing for increased patient input in the reconstructive process.

Our novel technique combines autologous abdominal free flaps with immediate pre-pectoral adjustable saline implants to provide a customizable, single-stage strategy. We report our experience in women with insufficient abdominal adiposity to achieve their desired breast volume. We compare the results of this novel technique to delayed implant placement following autologous breast reconstruction. We focus on patient satisfaction and ability to achieve goal breast size while minimizing repeat operative intervention.

## 2. Methods

A retrospective review of a single surgeon's patients undergoing breast reconstruction with abdominal free tissue transfer and either immediate placement of adjustable saline implants or delayed placement of implants for augmentation was performed. Patient characteristics such as age, body mass index, smoking status, history of diabetes, history of radiation therapy and chemotherapy were collected. Operative details such as type of mastectomy, type of flap, immediate vs delayed breast reconstruction, initial implant fill, and final implant volume were recorded. Complications

such as mastectomy skin flap necrosis, infection, fat necrosis, implant malposition, venous congestion, and hematoma were reviewed. Ability to achieve goal breast size was compared between the two groups by examining the need for further implant upsizing. Patient satisfaction and follow up time were examined as well.

### 2.1. Statistical Analyses

All statistical analyses were completed using Stata v.15 (StataCorp, College Station, TX). The Shapiro-Wilk test was used to determine whether continuous variables were normally distributed. Patient demographic and clinical information was compared between delayed and immediate implant cohorts using chi square and Student's t test analyses as appropriate. Fischer's exact testing was used for cases in which cell counts were less than 5. Multivariable regression with stepwise forward selection was used to determine predictors of postoperative patient satisfaction. Cluster robust variances were used to account for potential clustering of 41 breast interventions from 24 women. Likert-scale survey responses were compared between cohorts using Fisher's Exact analyses. The two-tailed threshold for statistical significance was set at an alpha value of 0.05.

### 2.2. Surgical Technique

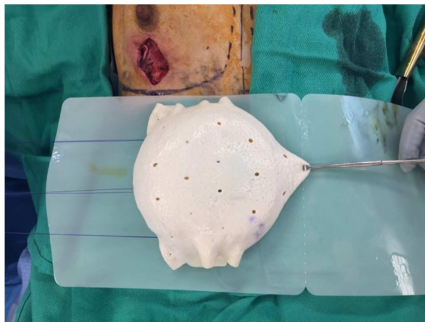The technique for autologous breast reconstruction with free abdominal tissue transfer and immediate placement of pre-pectoral adjustable saline implants is outlined as follows.

Pre-operative CT angiogram of the abdomen is obtained to help determine the patient's optimal perforators. The patient is marked in the preoperative area with the standard breast markings. The abdomen is marked for an abdominal-based free flap.

Following mastectomy, meticulous hemostasis is achieved. The preparation of the internal mammary vessels is performed at the level of the third rib. The abdominal free flap is harvested in the standard manner, either as a deep inferior epigastric perforator flap (DIEP) or a muscle-sparing free transverse rectus abdominis muscle flap (MS-TRAM). The free flap is brought to the chest and microvascular anastomosis is performed to the internal mammary vessels. The arterial anastomosis is typically performed in an interrupted fashion with 9-0 nylon and a venous coupler is used for the venous anastomosis.

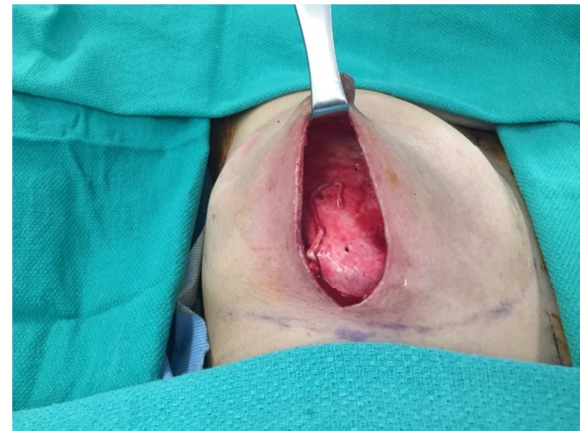
Prior to flap inset, an adjustable saline implant is selected based on chest base width and soaked in antibiotic irrigation. Any remaining air contained within the implant is removed. A construct consisting of the adjustable saline implant with 0 ml initial fill volume is wrapped and secured circumferentially with acellular dermal matrix (ADM), as seen in Figure 1. This is placed between the free flap and pectoralis muscle taking care to ensure minimal tension on the pedicle. The ADM enveloping the implant is secured to the chest wall to prevent implant migration as seen in Figure 2. It is anchored to the chest wall 2 cm from the pedicle to ensure that the construct does not overlay the anastomosis or

impinge on the pedicle. The construct is further secured to the inframammary fold to allow maximal lower pole expansion of the flap with subsequent expansions. A drain is placed and brought out through the skin inferolaterally. The external remote port of the adjustable saline implant is secured next to but separate from the drain exit site in the subcutaneous tissue. The flap is inset over the implant-ADM construct with interrupted 3-0 Vicryl sutures. The adjustable saline implant may be filled with a small volume depending on the tension upon closure. The mastectomy skin flap is draped over the abdominal flap and the wound is closed. A diagram of the different components of this hybrid reconstruction is illustrated in Figure 3.



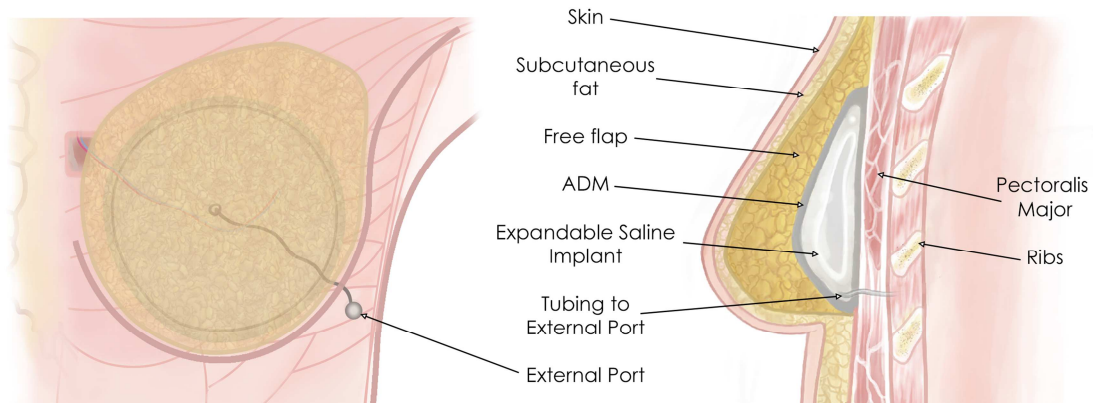
**Figure 1.** Creation of the implant and ADM construct.

A construct consisting of a fully inflated adjustable saline implant wrapped circumferentially with acellular dermal matrix is prepared.



**Figure 2.** Insetting the implant and ADM construct.

The adjustable saline implant is deflated, and the construct is placed in a pre-pectoral position, being careful not to compress the pedicle. The acellular dermal matrix (ADM) is secured to the chest wall. The implant is temporarily removed from the ADM pocket for flap anastomosis. After the flap is inset, the implant is placed back into the ADM pocket.



**Figure 3.** Schematic of one-stage hybrid breast reconstruction.

Schematic of hybrid one stage breast reconstruction with free flap and immediate placement of pre-pectoral expandable saline implant wrapped in acellular dermal matrix.

### 3. Results

Twenty-four patients (41 breasts) were identified and met inclusion criteria. Sixteen patients received implants in a delayed manner (28 breasts), while 8 received adjustable saline implants immediately with flap reconstruction (13 breasts). Of the 24 study patients, 22 also provided postoperative survey responses.

Delayed and immediate patient cohorts were largely similar in terms of demographics and clinical history (Table 1). Mean

age was 41.2 years (range 25-61), and average BMI was 26.2 (range 18 – 33.8). A majority of patients (79.2%) were non-smokers. One patient had a history of diabetes. Three patients had a history of cosmetic breast augmentation. Preoperatively, bra cup size ranged from B (N=2), C (N=5), to D (N=1). Most patients desired upsizing (58.3%), the most modest being B to small C, and the most extreme being B to full C/D and C to DD/DDD. Mean length of follow-up was significantly longer in the delayed cohort versus the immediate cohort (43.5 months versus 6.0 months,  $p < 0.0001$ ).

**Table 1.** Demographics and Clinical Characteristics, by Patient (n=24 patients).

Characteristic	Delayed (n=16)	Immediate (n=8)	p-value
Mean Age (SD)	43.0 (8.0)	41.0 (7.7)	0.56
Mean BMI (SD)	25.6 (3.9)	26.7 (5.3)	0.56
Tobacco Use – n (%)			1.0
Former	3 (18.8)	2 (25.0)	
Current	13 (81.3)	6 (75.0)	
Diabetes Mellitus – n (%)	1 (6.3)	0 (0.0)	1.0
History of Breast Augmentation – n (%)			
Desired Larger Cup Size – n (%)	9 (56.3)	5 (62.5)	1.0
Procedure Laterality – n (%)			0.65
Unilateral	4 (25.0)	3 (37.5)	
Bilateral	12 (75.0)	5 (62.5)	
Mean Length of Follow Up in Months (SD)	43.5 (19.1)	6.0 (4.7)	<0.0001

SD: Standard deviation

Delayed and immediate cohorts were largely similar in terms of breast cancer history (Table 2). Indications for mastectomy across the two patient cohorts included invasive ductal carcinoma (IDC)/invasive lobular carcinoma (ILC) (N=21 breasts), ductal carcinoma in situ (DCIS; n=2 breasts)

and prophylactic procedures, including contralateral prophylactic mastectomies (n=17 breasts). Nineteen breasts were radiated. There was no difference in mean mastectomy specimen weights.

**Table 2.** Breast Cancer History, by Breast (n=41 breasts).

Characteristic <sup>a</sup>	Delayed (n=28)	Immediate (n=13)	p-value
Diagnosis – n (%)			0.70
BRCA/TP53/Prophylactic	10 (37.0)	7 (53.9)	
Ductal Carcinoma In-Situ	2 (7.4)	0 (0.0)	
Invasive Ductal Carcinoma	14 (51.9)	6 (46.1)	
Invasive Lobular Carcinoma	1 (3.7)	0 (0.0)	
Chemotherapy – n (%)	4 (14.8)	8 (61.5)	0.18
Radiation – n (%)	15 (57.6)	4 (30.8)	0.28
Mean Mastectomy Specimen Weight (SD)	438.6 (54.6)	341.6 (92.4)	0.46
Mastectomy Type – n (%)			0.002
MRM	1 (3.7)	2 (15.4)	
SSM	12 (44.4)	0 (0.0)	
NSM	9 (33.3)	11 (84.6)	

SD: Standard deviation

<sup>a</sup> percentages reported out of number of breasts for which clinical data was available**Table 3.** Reconstructive Characteristics, by Breast (n=41 breasts).

Characteristic <sup>a</sup>	Delayed (n=28)	Immediate (n=13)	p-value
History of Prior Reconstructive Implants – n (%)	9 (33.3)	1 (7.7)	0.12
Delayed Free Flap Reconstruction – n (%)	15 (55.6)	6 (46.2)	0.74
Free Flap Type – n (%)			0.63
DIEP	5 (18.5)	4 (30.8)	
MS TRAM	21 (77.8)	9 (69.2)	
SIEA	1 (3.7)	0 (0.0)	
IMA Recipient Vessel – n (%)	25 (92.6)	2 (100.0)	1.0
Final Implant Type – n (%)			<0.0001
Silicone	26 (92.9)	3 (23.1)	
Saline	2 (7.4)	10 (76.9)	
ADM Use	6 (24.0)	13 (100)	<0.0001
Number of Postoperative Expansions – (SD)	n/a	3.1 (3.0)	n/a
Time (Months) to Final Volume <sup>b</sup> – (SD)	9.4 (8.8)	2.3 (0.8)	0.0003
Mean Implant Volume (SD)	238.1 (80.1)	248 (118.4) <sup>c</sup>	0.77

SD: Standard deviation; ADM: acellular dermal matrix

<sup>a</sup> percentages reported out of number of breasts for which clinical data was available<sup>b</sup> Time to final implant placement or time for volume expansion<sup>c</sup> final volume after expansion or after definitive implant exchange

A total of 41 breasts total were reconstructed, consisting of 13 hybrid abdominal flaps with immediate inflatable saline

implants and 28 abdominal flaps with delayed implant placement. Reconstruction characteristics are summarized in

Table 3. The majority of flaps performed were MS-TRAM, and type of flap performed did not differ between groups. In the immediate cohort, the acellular dermal matrix used to envelop the expandable prosthesis was DermACELL (Novadaq, Bonita Springs, Fla.) in 4 breasts and AlloDerm (LifeCell Corp., Branchburg, N. J.) in 7 breasts. Mentor Smooth Round Spectrum Saline Implant with 125-375 cc volume were used in the immediate cohort. Initial implant fill in all cases were 0 cc except one case where tension allowed for 50 cc of initial prefill. The final implant volume was on average 248 cc (range 150-450 cc) achieved over 3 in-office expansions over a 2.3-month period. In the delayed cohort, mean time to implant reconstruction was 9.4 months and final breast volume was 236 cc on average. Final breast implant volumes did not significantly differ between delayed and immediate cohorts ( $p=0.77$ ), but the immediate cohort did have significantly shorter follow up time ( $p=0.0003$ ).

Postoperative complications by breast are reported in Table 4. In the immediate implant cohort, one flap developed venous congestion due to a large hematoma kinking the pedicle. The implant/ADM construct was found at a distance from the anastomosis and was not the cause of pedicle compromise. The flap was salvaged, and the patient ultimately had a good result with high patient satisfaction. Additionally, one patient in the immediate implant cohort developed cellulitis of the ipsilateral radiated breast with implant infection after she reinserted a drain that had been pulled out. Her implant was explanted after a failed course of antibiotic therapy. Two patients elected to exchange saline implants for silicone implants based on personal preference. In the delayed implant cohort, there was one hematoma requiring evacuation. No mastectomy skin flap necrosis, infection, fat necrosis, or immediate implant malposition were observed in either group.

Major revision surgery included manipulation of the breast implant or capsule to correct asymmetry, address inadequate breast size, or correct implant malposition. In the immediate

group, one implant was explanted following removal of the flap's skin paddle, which resulted in a fuller and more projected. In the delayed group, implants placed in the submuscular plane resulted in animation deformity requiring revision ( $n=2$ ), bottoming out of the breast requiring inframammary fold repair ( $n=2$ ), and chronic breast pain resulting in implant removal ( $n=1$ ). Implant exchanges were also performed for inadequate volume resulting in implant upsizing ( $n=4$ ) or excessive volume resulting in implant downsizing ( $n=6$ ). Overall, the delayed cohort had a significantly greater rate of major breast revision surgery compared to the immediate cohort (50% vs 7.7%,  $p=0.006$ ).

**Table 4.** Post-Reconstruction Outcomes/Complications, by Breast ( $n=41$  breasts).

Characteristic	Delayed (n=28)	Immediate (n=13)	p-value
Immediate Complications- n (%)			
Postoperative Flap Complications	1 (3.7)	1 (7.7)	0.54
Postoperative Implant Complications	0 (0)	1 (7.7)	0.54
Major Revision Surgeries- n (%)	15 (50.0)	1 (7.7)	0.006
Upsizing implant	4 (10.7)	0 (0)	
Downsizing implant	6 (21.4)	0 (0)	
Implant removal	1 (3.6)	1 (7.7)	
IMF revision	2 (7.1)	0 (0)	
Animation deformity	2 (7.1)	0 (0)	

IMF inferior mammary fold

High patient satisfaction with breast size and shape was noted across both cohorts, as shown in Table 5. Nearly all patients across both cohorts believed that it was beneficial to be able to adjust breast volumes post-reconstruction. Upon multivariable analysis, having immediate saline implant placement was demonstrated to increased odds of patient-reported satisfaction, though the study was underpowered to determine statistical significance (Table 6). A representative preoperative and postoperative result is shown in Figure 4.

**Table 5.** Postoperative Patient Survey Responses ( $n=22$  patients).

Characteristic	Delayed (n=15)	Immediate (n=7)	p-value
Satisfied with Current Breast Size - n (%) <sup>*</sup>			0.52
Unsatisfied	3 (20.0)	0 (0.0)	
Neutral	0 (0.0)	0 (0.0)	
Satisfied	12 (80.0)	7 (100.0)	
Utility of Postoperative Breast Volume Adjustment - n (%)	14 (93.3)	7 (100.0)	1.0

<sup>\*</sup>Patient responded either "very satisfied" or "slightly satisfied"

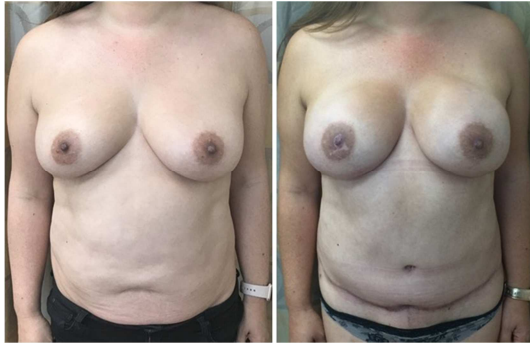**Table 6.** Crude and Adjusted Associations for Patient-Reported Satisfaction.

	Overall Delayed	Immediate	OR <sup>a</sup>	95% CI	p value	OR <sup>b</sup>	95% CI	p value
Patient Satisfaction								
Yes								
n	12	7						
%	75.0	100.0	4.2	0.3-10.1	0.36	4.0	0.2-12.3	0.44
No								
n	3	0						
%	25.0	0.0						

<sup>a</sup> unadjusted odds ratio

<sup>b</sup> odds ratio adjusted for BMI, smoking history, indication for mastectomy, revision surgery rates





**Figure 4.** Pre-operative and Post-operative photographs.

Patient preoperatively (left) and 6 months postoperatively (right) following bilateral mastectomy and immediate breast reconstruction with abdominal free flap and adjustable saline implant. The final result is an aesthetic augmented appearance and high patient satisfaction.

## 4. Discussion

As breast reconstruction techniques evolve, aesthetic standards are set increasingly higher. While most aspects of breast reconstruction, including softness, shape, symmetry, and sensation, have a well-defined ideal, goal breast size is a highly personal choice that varies from patient to patient. However, discussing breast size goals and achievable results with autologous reconstruction is challenging, especially in patients who have insufficient tissue for their desired breast size. Unfortunately, there are no studies to our knowledge that specifically evaluate surgeons' ability to meet patient's goals regarding breast size, and most studies do not specifically report percentage of patients that undergo elective breast reconstruction revision for augmentation. Amongst those performing hybrid breast reconstruction with implant and free flap, Bach *et al.* reported a 4.1% rate of delayed implant placement for asymmetry and aesthetically unsatisfying results following autologous reconstruction. [13] In our experience and patient population, the need for delayed implant placement following autologous breast reconstruction has been observed with increasing frequency.

To address this issue, patients are offered pre-pectoral or subpectoral breast implant placement for augmentation during elective revision procedures. While one revision with implant placement is usually sufficient to meet the patient's goals, 9 breasts (32%) in 6 patients (37.5%) required a second revision for implant exchange to upsize or downsize the breast. This rate falls within the range of previously reported rates (7%, 15%, 49%) of secondary revision for implant exchanges due to a desire for change in size. [3, 14] The revision rates demonstrate how difficult it can be to accurately estimate donor tissue volume the ability to achieve the patient's goal breast size, even for an experienced senior surgeon. Revision surgery is not only costly, but also exposes the patient to additional anesthetic and surgical risk. Additionally, both pre-pectoral and subpectoral implant placement are not ideal following autologous reconstruction. Subpectoral implants are subjected to the downwards and

lateralizing forces from intact portions of the intact pectoralis. The resulting bottoming-out deformity necessitates an additional major revision surgery to correct the IMF, as was the case in 2 patients. As with all subpectoral implants, animation deformity and discomfort can be a bothersome problem, which was the case in 3 patients, prompting them to have their implants removed. While pre-pectoral implants avoid these problems, flap elevation can be treacherous since the flap pedicle lies directly over the pectoralis muscle. Anecdotally, injury to the pedicle even years following reconstruction can threaten the flap and the entire reconstruction.

To minimize the need for major revision surgeries, we developed an approach whereby abdominal free tissue transfer is combined with immediate placement of a pre-pectoral expandable saline implant. This approach is especially useful in slim patients who elect to increase their breast volume compared to their native breast tissue, as illustrated in our patients with an average BMI of 26.2 requesting a full C to D size breast. By using an adjustable saline implant, nonsurgical postoperative adjustments to size can be performed in clinic. In contrast to the delayed implant placement group, none of the patients who received immediate inflatable saline implants returned to the operating room for implant upsizing or downsizing. Additionally, a few patients with delayed implant placement required additional implant exchange for size asymmetry, which may be avoided with inflatable saline implants that can be adjusted on a continuous spectrum. Our placement of the inflatable saline implant in the pre-pectoral space avoids animation deformity and long-term breast deformities due to contractile forces of the pectoralis major. Our data demonstrated that immediate pre-pectoral placement also decreased revision surgery requirements, thereby reducing global costs, postoperative morbidity, and additional exposure to general anesthesia.

Placement of an implant or tissue expander at the time of free flap reconstruction include early descriptions by Miller (1996) and Serletti (1998). [15-16] Our experience is consistent with the reported safety profile of hybrid reconstructions, including no flap loss, no microvascular thrombosis, and low rate of implant infection. [4, 15-20] Intraoperative fill volumes historically have ranged from 0 cc to placement of 150-300 cc implants. [4, 15, 16, 20] With our technique, the intraoperative fill volume was typically 0 cc to remove any concern that the implant could potentially cause undue tension or compression of the pedicle, free flap, or mastectomy flap, which is supported by Kronowitz's experience. [18] The circumferential ADM pocket is used to precisely define the implant pocket and prevent migration, similar to the technique described by Momeni and Kanchwala. [4] Pre-pectoral placement allows for maximal lower pole expansion with a natural appearance. While predecessors used tissue expanders for hybrid reconstruction, the adjustable saline implant is a softer more comfortable device designed as an implant that does not require a second operation to complete reconstruction. The subcutaneous

remotely located port allows for safer expansion because it does not require piercing through the flap potentially damaging the pedicle. Once the desired volume is achieved the port can be removed or left intact as a few of our patients have chosen to do.

Additional long-term benefits with immediate placement of inflatable saline implants exist as well. Future modifications of the implant or capsule are likely safer and technically easier with ADM protecting the pedicle. Considering breast cancer treatment beyond breast reconstruction, this one stage procedure may also be preferable for patients who require adjuvant chemotherapy or radiation therapy, by allowing them to proceed with oncologic treatment sooner after surgery, and complete reconstruction without the need for additional surgery. In our study, patients completed their reconstruction in a significantly shorter time with immediate implant placement when compared to delayed implant placement (2.3 vs 9.4 months,  $p=0.0003$ ). Furthermore, treatments such as radiation or surgery to the contralateral breast may result in asymmetries that can potentially be corrected without surgery if the remote port is left intact.

Lastly, we sought to evaluate patient satisfaction specifically regarding breast size. Our hybrid technique essentially takes the majority of the guesswork out of the reconstructive process. The patient is able to dictate their final breast size in clinic and make small adjustments as they see fit. While our sample size was underpowered to determine statistical significance, those with immediate inflatable implants with flap reconstruction tended to have higher rates of satisfaction than those who received delayed implants. There is increasing literature supporting a shared decision-making process in medicine, citing that patients who make their own decisions are more satisfied with their care and possess better quality of life. [21-23] This confers a psychological benefit to patients who may sometimes feel as if they have lost control of their bodies and lives while dealing with breast cancer treatment. [24] This shared decision making and use of adjustable saline implants offers the surgeon and patient more flexibility, which was appreciated across both groups, as evidenced by 93.3% in the delayed group and 100% in the immediate group preferring to having an option for nonsurgical adjustment of breast size postoperatively.

Finally, there are limitations to this technique and to this study. Expandable implants have a set range of minimum and maximum volumes so the general range of postoperative expansion must be discussed preoperatively and is defined at the time of surgery. Accurate estimations of flap volume and goal breast size are helpful, but not required as long as an implant with a large enough range is selected. Regarding the study, our two cohorts are relatively small and follow up times relatively short in the immediate implant placement group. As more of these procedures are performed, future analyses with larger sample sizes and longer follow up times will allow us to better evaluate our results. Our initial results are promising and a larger study with comparison groups is

forthcoming.

## 5. Conclusion

Inherent challenges exist in providing autologous breast reconstruction outcomes that precisely reflect patient preferences. The desire for secondary augmentation after autologous breast reconstruction is therefore not uncommon amongst patients. Our authors propose a single-stage hybrid approach with a pre-pectoral adjustable saline implant and abdominal free flap. This one-stage breast reconstruction technique reduces the rate of major revision surgery and optimizes patient satisfaction in autologous breast reconstruction.

## Acknowledgements

Special recognition is given to Hope Xu, MD for assistance with illustrations.

## References

- [1] Pusic AL, Matros E, Fine N, et al. Patient-reported outcomes 1 year after immediate breast reconstruction: Results of the Mastectomy Reconstruction Outcomes Consortium study. *J Clin Oncol*. 2017; 35 (22): 2499-2506.
- [2] Santosa KB, Qi J, Kim HM, et al. Long-term Patient-Reported Outcomes in Postmastectomy Breast Reconstruction. *JAMA Surg*. 2018; 153 (10): 891-899.
- [3] Kanchwala S, Momeni A. Hybrid breast reconstruction-the best of both worlds. *Gland Surg*. 2019; 8 (1): 82-89.
- [4] Momeni A, Kanchwala S. Hybrid prepectoral breast reconstruction: A surgical approach that combines the benefits of autologous and implant-based reconstruction. *Plast Reconstr Surg*. 2018; 142 (5): 1109-1115.
- [5] Chu MW, Samra F, Kanchwala SK, et al. Treatment Options for Bilateral Autologous Breast Reconstruction in Patients with Inadequate Donor-Site Volume. *J Reconstr Microsurg*. 2017; 33 (5): 305-311.
- [6] Hsieh F, Shah A, Malata CM. Experience with the Mentor Contour Profile Becker-35 expandable implants in reconstructive breast surgery. *J Plast Reconstr Aesthetic Surg*. 2010; 63 (7): 1124-30.
- [7] Scuderi N, Alfano C, Campus GV, et al. Multicenter study on breast reconstruction outcome using becker implants. *Aesthetic Plast Surg*. 2011; 35 (1): 66-72.
- [8] Choo AMH, Forouhi P, Malata CM. Innovative combination of therapeutic mammoplasty and expandable-implant breast augmentation for immediate partial breast reconstruction. *Int J Surg Case Rep*. 2016; 23: 146-150.
- [9] Spear SL, Seruya M, Clemens MW, et al. Acellular dermal matrix for the treatment and prevention of implant-associated breast deformities. *Plastic Surgical Nursing*. 2011; 127 (3): 1047-1058.
- [10] Lardi AM, Ho-Asjoe M, Junge K, et al. Capsular contracture in implant based breast reconstruction-the effect of porcine acellular dermal matrix. *Gland Surg*. 2017; 6 (1): 49-56.

- [11] Mowlds DS, Salibian AA, Scholz T, et al. Capsular Contracture in Implant-Based Breast Reconstruction. *Plast Reconstr Surg.* 2015; 136 (4): 629-635.
- [12] Vardanian AJ, Clayton JL, Roostaeian J, et al. Comparison of implant-based immediate breast reconstruction with and without acellular dermal matrix. *Plast Reconstr Surg.* 2011; 128 (5): 403e-410e.
- [13] Bach AD, Morgenstern IH, Horch RE. Secondary “hybrid Reconstruction” concept with silicone implants after autologous breast reconstruction - Is it safe and reasonable? *Med Sci Monit.* 2020; 26: e921329.
- [14] Roehl KR, Baumann DP, Chevray PM, et al. Evaluation of outcomes in breast reconstructions combining lower abdominal free flaps and permanent implants. *Plast Reconstr Surg.* 2010; 126 (2): 349-357.
- [15] Miller MJ, Rock CS, Robb GL. Aesthetic breast reconstruction using a combination of free transverse rectus abdominis musculocutaneous flaps and breast implants. *Ann Plast Surg.* 1996; 37 (3): 258-64.
- [16] Serletti JM, Moran SL. The combined use of the TRAM and expanders/implants in breast reconstruction. *Ann Plast Surg.* 1998; 40 (5): 510-4.
- [17] Chang KP, Lin SD, Lin TM, et al. The simultaneous combination of implants and tram flaps for an aesthetically pleasing breast. *Kaohsiung J Med Sci.* 2002; 18 (5): 215-20.
- [18] Kronowitz SJ, Robb GL, Youssef A, et al. Optimizing autologous breast reconstruction in thin patients. *Plast Reconstr Surg.* 2003; 112 (7): 1768-78.
- [19] Momeni A, Kanchwala SK. Improved pocket control in immediate microsurgical breast reconstruction with simultaneous implant placement through the use of mesh. *Microsurgery.* 2018; 38 (5): 450-457.
- [20] Spear SL, Wolfe AJ. The coincidence of TRAM flaps and prostheses in the setting of breast reconstruction. *Plast Reconstr Surg.* 2002; 110 (2): 478-86.
- [21] Greenfield S, Kaplan S, Ware JE. Expanding patient involvement in care: Effects on patient outcomes. *Ann Intern Med.* 1985; 102 (4): 520-8.
- [22] Moyer A, Salovey P. Patient participation in treatment decision making and the psychological consequences of breast cancer surgery. *Womens Health.* 1998; 4 (2): 103-16.
- [23] Street RL, Voigt B. Patient participation in deciding breast cancer treatment and subsequent quality of life. *Med Decis Mak.* 1997; 17 (3): 298-306.
- [24] Shell, J. A. & Kirsch S. Psychosocial issues, outcomes, and quality of life. In S. E. Otto (Ed.). *Oncology Nurs.* 2001: 4th ed., pp. 948-972.