

Immunohistochemical Analysis of Mediastinal Lymph Node Metastasis of Lung Cancer by EBUS-TBNA

Zhao Congxuan¹, Yu Tao²

¹Department of Ultrasound, Affiliated Hospital of Liaoning University of Traditional Chinese Medicine, Shenyang, China

²Department of Diagnostic Ultrasound, Cancer Hospital of China Medical University, Liaoning Cancer Hospital & Institute, Shenyang, China

Email address:

epestion0908@163.com (Zhao Congxuan), yutao@cancerhosp-ln-cmu.com (Yu Tao)

To cite this article:

Zhao Congxuan, Yu Tao. Immunohistochemical Analysis of Mediastinal Lymph Node Metastasis of Lung Cancer by EBUS-TBNA. *Journal of Surgery*. Vol. 10, No. 3, 2022, pp. 125-130. doi: 10.11648/j.js.20221003.17

Received: March 20, 2022; **Accepted:** June 8, 2022; **Published:** June 9, 2022

Abstract: *Objective:* To analyze the immunohistochemical characteristics of mediastinal lymph node metastasis of lung cancer, and compare the positive expression of immunohistochemical markers in the main pathological types of lung cancer. *Materials and Methods:* From January 2015 to March 2019, 142 patients who underwent EBUS-TBNA examination in Cancer Hospital Affiliated to China Medical University due to hilar and mediastinal lymphadenopathy on CT were analyzed retrospectively. The pathological and immunohistochemical results of these patients were statistically analyzed. *Results:* P63 and CK5 / 6 were significantly expressed in lymph node metastasis from lung squamous cell carcinoma; CK8 / 18 was only statistically different between small cell lung cancer group and squamous cell carcinoma group ($P < 0.0001$), with higher positive expression in squamous cell carcinoma group; TTF-1 was almost not expressed in mediastinal lymph node metastasis from lung squamous cell carcinoma group, so it can effectively distinguish and exclude lymph node metastasis from lung squamous cell carcinoma; Napsin A and CK7 could effectively identify lymph node metastasis from lung adenocarcinoma; Syn, TTF-1, CD56 and CgA were significantly different in lymph node metastasis from small cell lung cancer, of which Syn was the most sensitive (positive expression rate was 90%). *Conclusions:* Immunohistochemistry can improve the accuracy of EBUS-TBNA in the diagnosis of lung cancer with lymph node metastasis, and is conducive to the accurate classification of lung cancer with mediastinal lymph node metastasis.

Keywords: Endobronchial Ultrasound-Guided Transbronchial Needle Aspiration (EBUS-TBNA), Lung Cancer, Mediastinal Lymph Node Metastasis, Pathologic Diagnosis, Pathological Classification, Immunohistochemistry

1. Introduction

Lung cancer is one of the most common and fatal malignant tumors. At present, its incidence rate and cancer mortality rank first in the world [1]. In China, lung cancer ranks first among all malignant tumors [2]. The diagnosis and treatment of lung cancer depend on accurate TNM staging and accurate pathological typing. The accurate evaluation of mediastinal lymph node metastasis is an important content of N-stage, which is very important for the diagnosis and treatment of lung cancer patients. In the process of clinical diagnosis and treatment, many patients were found to have advanced lung cancer at the first visit, and it is impossible to determine the pathological stage and diagnosis by

mediastinoscopy or surgery [3]. Different stages and pathological types of lung cancer have different treatment schemes, so accurate pathological results are particularly important [4]. EBUS-TBNA technology is visual, minimally invasive, easy to operate and highly reproducible [5]. It can puncture and sample the diseased tissues, and carry out cell staining, cytological morphology and immunohistochemistry on the obtained tissues. It has important clinical value in the diagnosis of lung cancer and mediastinal lymph node staging [6, 7]. Immunohistochemistry (IHC) is of great significance in the diagnosis and differential diagnosis of tumor related diseases [8, 9]. However, can the immunohistochemical results of EBUS-TBNA effectively classify the primary lung cancer? Therefore, this study reviews the patients with mediastinal lymph node metastasis of lung cancer who

underwent EBUS-TBNA biopsy, determines the final diagnosis according to the postoperative pathological examination results and follow-up for 6 months, and analyzes the immunohistochemical pathological results, so as to accumulate experience for the accurate diagnosis of mediastinal lymph node metastasis of lung cancer.

2. Material and Methods

2.1. Clinical Material

From January 2015 to March 2019, 142 patients who underwent EBUS-TBNA examination in the Affiliated Tumor Hospital of China Medical University due to CT findings of hilar and mediastinal lymph nodes enlargement were retrospectively analyzed, including 84 males and 58 females, aged between 29 and 76 years, with an average age of 57 years. The immunohistochemical results of EBUS-TBNA pathology were statistically analyzed.

2.2. Instruments and Equipment

Ultrasound endoscopy adopts BF-TYPE-UC260FW 260 of Olympus company in Japan, convex array scanning; The puncture needle adopts the special No. 22 needle of Japan Olympus company, NA-201SX-4022.

2.3. Pathological Examination

Cytological smears and HE staining were used for EBUS-TBNA biopsy cytological examination; Immunohistochemical detection was performed for those who could not be accurately identified and typed.

2.4. Result Judgment

The criteria and classification of pathological diagnosis refer to the classification of tumors (2015 Edition) formulated by the World Health Organization (who) [10]. If any one item in cytology and histology shows malignant tumor cells, it is determined to be positive. For highly

suspicious malignant tumors or abnormal cells (atypical hyperplasia), it is necessary to combine clinical tumor markers and imaging follow-up or use other methods to make a definite diagnosis and determine it as positive. Negative patients were followed up for more than 6 months combined with clinical data.

2.5. Statistical Analysis

SPSS 20.0 software was used for statistical analysis. Kruskal Wallis h test was used for comparison between groups; When the difference between groups is statistically significant, the indexes with significant difference are compared in pairs within the group, and Bonferroni correction is used. The difference between groups was statistically significant ($P < 0.05$). Compared within the group, the statistical level after correction was $p < 0.0167 (0.05 / 3)$.

3. Results

Among 142 patients, 72 patients were finally diagnosed with lung cancer and mediastinal lymph node metastasis, and 120 enlarged mediastinal lymph nodes were detected. Among them, 70 cases were diagnosed by immunohistochemistry and 114 mediastinal enlarged lymph nodes; There were 50 enlarged lymph nodes from small cell lung cancer metastasis, 42 from lung adenocarcinoma metastasis, 16 from squamous cell carcinoma metastasis, 2 from lung cancer sarcomatoid carcinoma metastasis, 2 large cell neuroendocrine carcinoma, and 2 poorly differentiated adenocarcinoma with sarcomatization.

Summarize the immunohistochemical characteristics of metastatic lymph nodes from small cell lung cancer, lung adenocarcinoma and lung squamous cell carcinoma, and summarize the positive expression rate of different immunohistochemical indexes in metastatic lymph nodes of small cell lung cancer, lung adenocarcinoma and lung squamous cell carcinoma (Figure 1), and then compare these indexes between groups by Kruskal Wallis h test. (Table 1).

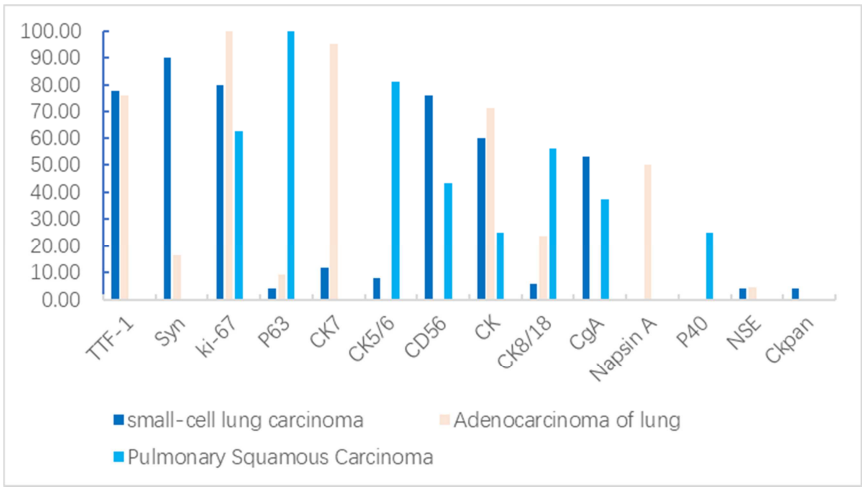


Figure 1. The positive expression rates of different immunohistochemical markers in metastatic lymph nodes of small cell lung cancer, lung adenocarcinoma and pulmonary Squamous Carcinoma [n (%)].

Table 1. Comparison of immunohistochemical markers of mediastinal lymph node metastasis from different pathological types of lung cancer [n (%)].

Immune index	small-cell lung carcinoma (n=50)	Adenocarcinoma of lung (n=42)	Pulmonary Squamous Carcinoma (n=16)	P value
TTF-1	39 (78.0%)	32 (76.2%)	-	1.000
Syn	45 (90.0%)	7 (16.7%)	-	<0.0001
CD56	38 (76.0%)	-	7 (43.4%)	<0.0001
CK	30 (60.0%)	30 (71.4%)	4 (25.0%)	0.058
CgA	26 (53.0%)	-	6 (37.5)	<0.0001
Ckpan	2 (4.0%)	-	-	-
NSE	2 (4.0%)	2 (4.8%)	-	1.000
CK5/6	4 (8.0%)	-	13 (81.3%)	<0.0001
P63	2 (4.0%)	4 (9.5%)	16 (100.0%)	<0.0001
P40	-	-	4 (25.0%)	-
Napsin A	-	21 (50.0%)	-	-
CK7	6 (12.0%)	40 (95.2%)	-	<0.0001
CK8/18	3 (6.0%)	10 (23.8%)	9 (56.3%)	<0.0001
ki-67	40 (80.0%)	42 (100.0%)	10 (62.5%)	

Note: - means innumerable.

As can be seen from Figure 1 and table 1, the positive expression rates of Synaptophysin Syn, thyroid transcription factor-1 (TTF-1), CD56, cytokeratin (CK) and chromogranin A (CgA) were 90%, 78%, 76%, 60% and 14% respectively; The positive expression rates of TTF-1, cytokeratin 7 (CK7) and CK in adenocarcinoma group were 100.0%, 95.2% and 71.4% respectively; The positive expression rates of P63, CK5 / 6 and CK8 / 18 in squamous cell carcinoma group were 100.0%, 81.3% and 56.3% respectively. Among them, Syn, CD56 and CgA were significantly different in the expression of lymph node metastasis from small cell lung

cancer ($P < 0.0001$); CK5 / 6 was significantly expressed in lymph node metastasis from squamous cell carcinoma; There was no significant difference in the expression of cytokeratin CK in metastatic lymph nodes of small cell carcinoma, adenocarcinoma and squamous cell carcinoma ($P = 0.58$), and the expression of CK7 in metastatic lymph nodes from adenocarcinoma was significant ($P < 0.0001$); There was significant statistical difference between P63 and CK8 / 18 groups ($P < 0.0001$). The statistical level after correction was $p < 0.0167$ ($0.05 / 3$).

Table 2. Pairwise comparison of P63 and CK8 / 18 in small cell lung cancer, adenocarcinoma and squamous cell carcinoma (Bonferroni correction method).

Int groups comparison	P value P63	P value CK8/18
Small-cell lung cancer vs. adenocarcinoma	0.406 ^a	0.018 ^a
Adenocarcinoma vs. squamous cell carcinoma	<0.0001 ^a	0.290
Small-cell lung cancer vs. squamous cell carcinoma	<0.0001 ^a	<0.0001 ^a

Note: ^a: Fisher exact test.

It can be seen from table 2 that there was no significant difference in the positive expression of P63 between small cell carcinoma and adenocarcinoma groups ($P = 0.406$), while there was significant difference between squamous cell carcinoma group and adenocarcinoma and small cell carcinoma group ($P < 0.0001$). The positive expression of CK8 / 18 was higher in small cell lung cancer group than that in squamous cell carcinoma group ($P < 0.0001$).

4. Discussion

At present, it is still a challenge to clarify the diagnosis and pathological typing of small sample biopsy. For lung cancer with mediastinal lymph node metastasis, a clear pathological diagnosis is the basis of treatment. Studies have shown that on the basis of EBUS-TBNA, the diagnostic rate of immunohistochemical detection of obtained cells and tissues is significantly higher than that of routine puncture smear and TCT, and can provide pathological typing [11, 12]. However, there are few reports on whether the mediastinal lymph node metastasis of lung cancer is completely consistent with the immune markers between the primary stove.

Our results showed that the positive expression rates of P63, CK5 / 6 and CK8 / 18 in squamous cell carcinoma group were 100.0%, 81.3% and 56.3% respectively. Previous studies have shown that P63, P40 and CK5 / 6 are common markers of lung squamous cell carcinoma, and most studies have shown that P63 and CK5 / 6 have high sensitivity in the diagnosis of lung squamous cell carcinoma [13, 14]. P63 is a member of the p53 family of tumor suppressor genes, which is related to the squamous differentiation of various tissues [15]. P63 is a common immune marker for the diagnosis of lung squamous cell carcinoma, especially in poorly differentiated squamous cell carcinoma. The results of this study showed that the expression rate of P63 was 100% in the group of mediastinal lymph node metastasis of lung squamous cell carcinoma, and showed a low degree of expression in the lymph node metastasis of small cell lung cancer and adenocarcinoma; The statistical results showed that there was significant difference in P63 among the three groups and between squamous cell carcinoma lymph node metastasis group and adenocarcinoma metastasis group and small cell carcinoma metastasis group ($P < 0.0001$), but there was no significant difference in the positive expression of

P63 between small cell carcinoma metastasis group and adenocarcinoma metastasis group ($P = 0.406$), indicating that P63 was specifically expressed in mediastinal lymph node metastasis from lung squamous cell carcinoma. It can also be seen from table 1 and table 2 that the positive expression rate of CK8 / 18 in mediastinal lymph node metastasis of squamous cell carcinoma was 56.3%, and there was significant difference only in the comparison between lung small cell carcinoma metastasis group and squamous cell carcinoma metastasis group ($P < 0.0001$).

Immunohistochemical results showed that the positive expression rates of TTF-1, cytokeratin 7 (CK7) and CK in adenocarcinoma group were 100.0%, 95.2% and 71.4% respectively. Jafaria et al. [16] showed that the expression of TTF-1 in primary lung adenocarcinoma had high sensitivity and specificity, and most SCLC also expressed TTF-1, while lung squamous cell carcinoma almost did not express TTF-1. Therefore, using TTF-1 and P63 to distinguish lung squamous cell carcinoma from adenocarcinoma and NSCLC can reduce the misdiagnosis rate caused by abnormal immune response, and because they are nuclear markers, they are more reliable than cytoplasmic markers (such as Syn and CgA). In this study, TTF-1 was highly expressed in mediastinal lymph node metastasis from small cell lung cancer and lung adenocarcinoma (78.0% vs. 76.2%), and there was no significant difference ($P = 1.000$). Therefore, TTF-1 can only distinguish lymph node metastasis from lung squamous cell carcinoma, but it can not effectively distinguish lymph node metastasis from small cell lung cancer and lung adenocarcinoma. Napsin A is another commonly used marker for the diagnosis of lung adenocarcinoma after TTF-1. It is mostly positive in primary lung adenocarcinoma, but negative in other organ squamous cell carcinoma and adenocarcinoma [17]. The results of this study showed that Napsin A was only expressed in lung adenocarcinoma group. Although the positive expression rate was not very high (50.0%), it was not expressed in lung squamous cell carcinoma and small cell lung cancer group, so it was one of the effective indicators to distinguish lymph node metastasis of lung adenocarcinoma. CK7 is a alkaline cytokeratin, which is expressed in different parts of adenocarcinoma and is also commonly used in the differential diagnosis of lung adenocarcinoma [18]. In this study, the positive expression rate of CK7 in lymph node metastasis group of lung adenocarcinoma was 95.2%, and it was not expressed in squamous cell carcinoma metastasis group, but there was significant difference compared with small cell carcinoma metastasis group, which was consistent with previous studies.

SCLC is an epithelial tumor composed of small cells. It is highly malignant and prone to spread and metastasis. The results showed that the positive expression rates of Syn, TTF-1, CD56 and CgA in lymph node metastasis group of small cell lung cancer were 90.0%, 78%, 76.0% and 53.0% respectively, among which Syn was the most sensitive for diagnosis. Previous studies have shown that CD56 (98.3%), TTF-1 (91.7%) and Syn (86.7%) are sensitive indicators for

the diagnosis of SCLC [19]; Previous studies have also shown that CD56 has high sensitivity and specificity in distinguishing SCLC and NSCLC, and is a sensitive index for the diagnosis of SCLC [19-21], Š Vajdlery [22] and Yu et al. [23] showed that CD56 is the best single marker in the diagnosis of small cell lung cancer and non-small cell lung cancer, which is different from the results of this study. In addition, studies have shown that Syn is not sensitive in diagnosing SCLC (57.1%, 137 / 240) [15]. Some studies believe that Syn and CgA belong to cytoplasmic markers and are not stable without nuclear markers, which may lead to unreliable diagnostic results [20].

The results of this study showed that P63 and CK5 / 6 were significantly expressed in lymph node metastasis from squamous cell carcinoma; The positive expression of CK8 / 18 was higher in small cell lung cancer group than that in squamous cell carcinoma group ($P < 0.0001$); TTF-1 is hardly expressed in mediastinal lymph node metastasis from lung squamous cell carcinoma group, which can effectively distinguish and exclude lymph node metastasis from lung squamous cell carcinoma; Napsin A and CK7 can effectively distinguish lymph node metastasis from lung adenocarcinoma; Syn, TTF-1, CD56 and CgA were significantly different in the expression of lymph node metastasis from small cell lung cancer, among which Syn was the most sensitive (the positive expression rate was 90%).

Our previous studies have shown that the ultrasonic imaging features of EBUS-TBNA are of high value in the diagnosis of mediastinal lymph node metastasis of lung cancer (AUC: 0.879) [24], but there are still difficulties in the differential diagnosis with pulmonary tuberculosis and pulmonary sarcoidosis [25], and its ultrasonic imaging features have failed to effectively classify the primary lung cancer [24], and the final diagnosis still depends on the pathological diagnosis. In this study, the diagnostic rate of EBUS-TBNA immunohistochemistry was 95% (114 / 120), which was consistent with the results of Fei Mingjian et al. [26], significantly higher than the ultrasonic imaging diagnosis, and had more advantages in clarifying the pathological type compared with the cytomorphological examination.

The immunohistochemical results of this study overlap and differ from those of previous studies. The reasons are as follows: (1) Small sample size; (2) There are differences in the expression of tumor markers between primary lung cancer and lymph node metastasis; (3) Different immunohistochemical methods, the sensitivity and specificity of different antibodies and complements and the experiment itself can affect the diagnostic results. In addition, among the patients with mediastinal lymph node metastasis from the three subtypes of lung cancer, some patients have large postoperative pathological results, and the number of postoperative cases of some subtypes is less than 10. Therefore, it is difficult to compare the lymph node metastasis with the primary stove, which may lead to bias in the evaluation of statistical efficacy, so the relevant comparative research cannot be carried out, and the sample

should be expanded for further research in the future.

5. Conclusions

Immunohistochemistry can improve the accuracy of EBUS-TBNA in the diagnosis of lung cancer with lymph node metastasis, and is conducive to the accurate classification of lung cancer with mediastinal lymph node metastasis. Selecting reasonable markers by immunohistochemical technology can not only provide an objective basis for diagnosis and differential diagnosis but also reduce the economic burden of patients. Nevertheless, experts suggest that cell morphology is still the basis and key of diagnosis [27], which should still be paid attention to.

References

- [1] Bray F, Ferlay J, Soerjomataram I, et al. Global cancer statistics 2018: GLOBOCAN estimates of incidence and mortality worldwide for 36 cancers in 185 countries [J]. *CA: A Cancer Journal for Clinicians*, 2018, 68 (6): 394-424.
- [2] Cao Maomao, Chen Wanqing. Epidemiology of cancer in China and the current status of prevention and control [J]. *Chinese Journal of Clinical Oncology*, 2019, 46 (03): 145-149.
- [3] Fan T W M, Zhang X, Wang C, et al. Exosomal lipids for classifying early and late stage nonsmall cell lung cancer [J]. *Anal Chim Acta*, 2018, 1037: 256-264.
- [4] National, Health, Commission, et al. Chinese guidelines for diagnosis and treatment of primary lung cancer 2018 (English version)[J]. *Chinese Journal of Cancer Research*, 2019, 31 (1): 1-28.
- [5] Li xiaoyan, Zhao ziwen, Zhong weinong, et al. Endobronchial ultrasound-guided transbronchial needle aspiration EBUS-TBNA vs conventional transbronchial needle aspiration cTBNA in the diagnosis of mediastinal and hilar lymph nodes [J]. *Guangzhou Medical Journal*, 2016, 47 (3): 22-25.
- [6] Etterbeck FC, Jantz MA, Wallace M, et al. Invasive mediastinal staging of lung cancer: ACCP evidence -based clinical practice guidelines (2nd edition) [J]. *Chest*, 2007 (132): 202S-220S.
- [7] Rossifigueiredo V, Guerreirocardoso P F, MarciaJacomelli, et al. EBUS-TBNA versus surgical mediastinoscopy for mediastinal lymph node staging in potentially operable non-small cell lung cancer: a systematic review and meta-analysis [J]. *Jornal Brasileiro de Pneumologia*, 2020, 46 (6).
- [8] Li A, Yang DH. Application of Immunohistochemistry in Basic and Clinical Studies. *Methods Mol Biol*. 2020, 2108: 43-55. doi: 10.1007/978-1-0716-0247-8_4.
- [9] Schildhaus HU. Immunhistochemie-basierte prädiktive Biomarker bei Lungenkarzinomen [Immunohistochemistry-based predictive biomarkers for lung cancer]. [J]. *Pathologe*, 2020; 41 (1): 21-31. doi: 10.1007/s00292-020-00750-7.
- [10] Travis WD, Brambilla E, Burke AP, et al. WHO classification of tumors of the lung, pleura, thymus and heart [M]. 4th ed. Lyon: IARC Press, 2015: 153-181.
- [11] Su shicheng, Chen hong, Wu fengshu, et al. Value of EBUS-TBNA in the diagnosis of mediastinal lesions and paratracheal/parabronchial masses [J]. *Clinical Research and Practice*, 2019, 4 (07): 138-140.
- [12] Dhooria S, Madan K, Pattabhiraman V, et al. A multicenter study on the utility and safety of EBUS-TBNA and EUS-B-FNA in children [J]. *Pediatric Pulmonology*, 2016, 51 (10): 1031-1039.
- [13] Kim M J, Shin H C, Shin K C, et al. Best immunohistochemical panel in distinguishing adenocarcinoma from squamous cell carcinoma of lung: tissue microarray assay in resected lung cancer specimens [J]. *Annals of Diagnostic Pathology*, 2013, 17 (1): 85-90.
- [14] Bhatti V, Kwatra K S, Puri S, et al. Histopathological Spectrum and Immunohistochemical Profile of Lung Carcinomas: A 9-Year Study from a Tertiary Hospital in North India. [J]. *International journal of applied & basic medical research*, 2019, 9 (3): 169-175.
- [15] Massion P P, Taflan P M, Rahman S M, et al. Role of P63 amplification and overexpression in lung cancer development [J]. 2004, 125 (5): 7113-7121.
- [16] Jafarian A H, Gharib M, Roshan N M, et al. The diagnostic value of TTF-1, P63, HMWK, CK7, and CD56 immunostaining in the classification of lung carcinoma [J]. *Iranian Journal of Pathology*, 2017, 12 (3): 195-201.
- [17] Shen weimin, Xu jiayi, Tang xi. Study on the significance of expression of alpha-B-crystallin, TTF-1 and Napsin A in patients with primary lung adenocarcinoma [J]. *Journal of Clinical and Experimental Medicine*, 2016, 15 (18): 1800-1803.
- [18] Wang B, Ye N, Cao S J, et al. Identification of novel and differentially expressed MicroRNAs in goat enzootic nasal adenocarcinoma [J]. *BMC Genomics*, 2016, 17 (1): 896.
- [19] Li yiming, Quan li, Long zhinhua, et al. Small cell lung cancer with bronchoscopic biopsy specimens: immunohistochemical analyses of 60 cases [J]. *Chinese Journal of Diagnostic Pathology*, 2019, 26 (7): 423-426.
- [20] Zhou dongmei, Sun yu, Li xianghong. Diagnostic value of microtubule-associated protein-2 in small cell lung carcinoma: an analysis of 240 biopsy cases [J]. *Chinese Journal of Pathology*, 2013, 42 (5): 321-324.
- [21] Švajdler M, Mezencev R, Šašková B, Ondič O, Mukenšnábl P, Michal M. Triple marker composed of p16, CD56, and TTF1 shows higher sensitivity than INSM1 for diagnosis of pulmonary small cell carcinoma: proposal for a rational immunohistochemical algorithm for diagnosis of small cell carcinoma in small biopsy and cytology specimens. [J]. *Hum Pathol*, 2019, 85: 58-64. Doi: 10.1016/j.humpath.2018.10.016.
- [22] Švajdler M, Mezencev R, Ondič O, Šašková B, Mukenšnábl P, Michal M. P16 is a useful supplemental diagnostic marker of pulmonary small cell carcinoma in small biopsies and cytology specimens [J]. *Annals of Diagnostic Pathology*, 2017: S1092913417302873.
- [23] Yu L, Yao Y, Wang Y, et al. Preparation and anti-cancer evaluation of promiximab-MMAE, an anti-CD56 antibody drug conjugate, in small cell lung cancer cell line xenograft models. [J]. *J Drug Target*, 2018, 26 (10): 905-912.

- [24] Zhao congxuan. The application of EBUS-TBNA in the diagnosis of mediastinal lymph nodes metastasis of lung cancer [D]. China Medical University, 2020.
- [25] Wang L, Wu W, Teng J, et al. Sonographic Features of Endobronchial Ultrasound in Differentiation of Benign Lymph Nodes [J]. Ultrasound in Medicine & Biology, 2016, 42 (12): 2785-2793.
- [26] Fei Mingjian, Wu bin, Zhong zhengxiang. Value of Cytological smear and it combined with cell block immunohistochemistry in endoscopic ultrasonography guided fine needle aspiration biopsy [J]. China Journal of Endoscopy, 2019, 25 (09): 65-69.
- [27] Xiang guoqing, Zhu jia, Gao na. The value of endoscopic ultrasound-guided fine needle aspiration combining with immunohistochemistry in solid mediastinal lesions [J]. Laboratory Medicine and Clinic, 2018, 15 (4): 488-491.