

Transcranial Magnetic Stimulation for Post-Stroke Dyslexia 1 Case and Clinical Analysis

Yong Qin Xie¹, Hong Wang^{2,*}

¹Department of Rehabilitation, Jinan University, Guangzhou, China

²Department of Rehabilitation, The First Affiliated Hospital of Jinan University, Jinan University, Guangzhou, China

Email address:

daxiaobaotwins@126.com (Hong Wang)

*Corresponding author

To cite this article:

Yong Qin Xie, Hong Wang. Transcranial Magnetic Stimulation for Post-Stroke Dyslexia 1 Case and Clinical Analysis. *Rehabilitation Science*. Vol. 8, No. 1, 2023, pp. 1-4. doi: 10.11648/j.rs.20230801.11

Received: January 30, 2023; **Accepted:** February 22, 2023; **Published:** February 28, 2023

Abstract: Objective: To investigate the efficacy of repetitive transcranial magnetic stimulation therapy combined with speech training on the speech function of patients with post-stroke aphasia, understanding the mechanisms of cognitive neuropsychological recovery in patients with dyslexia. METHODS: One case of aphasia patients was collected and treated with repetitive transcranial magnetic stimulation and speech therapy, and the patients' Chinese language aphasia examination assessment and hydrogen protons nuclear magnetic resonance spectroscopy results were collected before and after treatment. Based on the combination of neurocognitive psychological model, the relationship between the change of speech function and the dual-channel model before and after patients' repetitive transcranial magnetic stimulation combined with speech therapy was investigated. RESULTS: After 2 months of treatment, the patient's reading function, conversation, comprehension, repetition, and naming function improved when compared with before, and hydrogen protons nuclear magnetic resonance spectroscopy suggested that the patient's bilateral cerebral hemispheres Cr/Ch, and NAA/Cr all increased after treatment compared with before. Conclusion: Transcranial magnetic stimulation therapy combined with speech training can promote the increase of brain metabolites and improve patients' reading function, providing a new therapeutic idea for the treatment of post-stroke dyslexia. Meanwhile, the combination of repetitive transcranial magnetic stimulation technique and hydrogen proton MRI spectroscopy can be used as a non-invasive treatment-examination combination to explore the mechanisms of recovery from dyslexia.

Keywords: Post-Stroke Dyslexia, Transcranial Magnetic Stimulation, Magnetic Resonance Spectroscopy Imaging

1. Introduction

Acquired alexia, a partial or complete loss of comprehension of written language symbols (words) with or without dyslexia, due to brain damage, is a special type of Benson classification [1]. Most of the current domestic studies on aphasia treatment are clinical control studies that encompass different types of aphasia [12-14], and there are fewer studies on individuals with aphasia to analyze patient-specific cognitive models of speech [2]. This study investigates the possible mechanism of transcranial magnetic stimulation therapy on the recovery of aphasia after stroke based on the speech cognition model combined with magnetic resonance spectroscopy imaging (MRS).

2. Clinical Information

The patient, male, 46 years old, right-handed, was admitted to the rehabilitation department of our hospital in the afternoon of July 28, 2022 due to "unfavorable speech for more than 1 month". 1 month ago, the external cranial CT indicated: left temporal lobe cerebral hemorrhage, midline structural displacement. He denied previous history of stroke, psychiatric disease, and substance abuse, and was clinically diagnosed with left temporal lobe hemorrhage and brain herniation. After the onset of the disease, the patient often complained that he could not read the words he used to know now, and his reading ability was significantly reduced. or semantic errors, i.e., reading words as semantically related words, such as "yishen" as "daifu" (Both words mean "doctor") and "cold" as "hot". "hot". His spontaneous speech was

mainly simple sentences, with decreased listening comprehension and average retelling and naming ability.

3. Methods

3.1. Treatment Method

3.1.1. Transcranial Magnetic Stimulation Therapy

A TMS stimulator of Wuhan Evidence, model CCY, with a frequency of 10 Hz and an intensity of 80% RMT was used for the treatment, and a total of 1200 stimulations were performed. According to the EEG international standard lead 10-20 system localization method, the left hemisphere inferior frontal gyrus triangle was selected as the stimulation site. The treatment was given for 6 minutes per day, 5 days per week, 2 weeks for 1 session, and 3 sessions (t1-t3) in total. Each session was separated by 1 week.

3.1.2. Speech Therapy

Using Schuell stimulation therapy, according to the patient's condition, speech training was performed twice a day for 30 minutes/time, with 1 training session within 10 minutes after transcranial magnetic stimulation treatment, 5 days a week, 2 weeks as 1 course of treatment, 4 (t1-t4) sessions in total. The treatment course was based on vocabulary training.

3.2. Evaluation Methodology

The aphasia battery of Chinese (ABC) was used to assess patients' language functions in terms of conversation, comprehension, repetition, naming, reading, writing, structure and visual space, use, and computation, with the reading part (sight reading, auditory word recognition, word-picture matching, reading instruction execution, and fill-in-the-blank) as the primary observation and the other speech parts as

secondary observations. The other parts of speech were used as secondary indicators, including conversation (information, fluency, series of words), comprehension (hearing, recognition, verbal instructions), repetition (word repetition, sentence repetition), and naming (word naming, listing). Assessments were made once before (t0) and 2 weeks after treatment (t1, t2, t3, t4), for a total of 5 assessments, each completed by the same therapist.

3.3. Imaging Examinations and Data Analysis

Before treatment (t0) and 1 month after treatment (t2), MRI spectral analysis was completed on the patient, and imaging was performed using a 3.0T GE Discovery 750 MRI device to locate the bleeding lesion using MRI and localize the area of interest using [1] H-MRS. A single voxel was used to localize around the Broca area (Brodmann 44 area) and the Broca mirror area (Figure 1), and data processing was performed to obtain information on the ratio of specific metabolites choline (Ch) to N-acetylaspartate (NAA) and creatine (Cr), i.e., Cr/Ch, NAA/Cr, after completion of the scan.

4. Results

4.1. Results of Speech Function Assessment

The Chinese aphasia set of test scales suggested that patients' reading function improved significantly after treatment, with varying degrees of improvement in conversation, comprehension, repetition, naming, and (Table 1, Figure 1, Figure 1). t3-t4 phase was not performed with transcranial magnetic stimulation, but speech therapy continued, and the overall improvement at t3 over t0 shown in Figure 1 was greater than the overall improvement at t4 over t0.

Table 1. Read Function Results.

	Reading				
	Sight Reading	Auditory Word Recognition	Word-Picture Matching	Reading Instruction Execution	Fill-in-the-blank
t0	40%	80%	47.50%	90%	73.33%
t1	70%	100%	90%	66.67%	93%
t2	70%	80%	87.50%	77%	90%
t3	80%	90%	90%	40%	90%
t4	60%	80%	95%	73.33%	100%

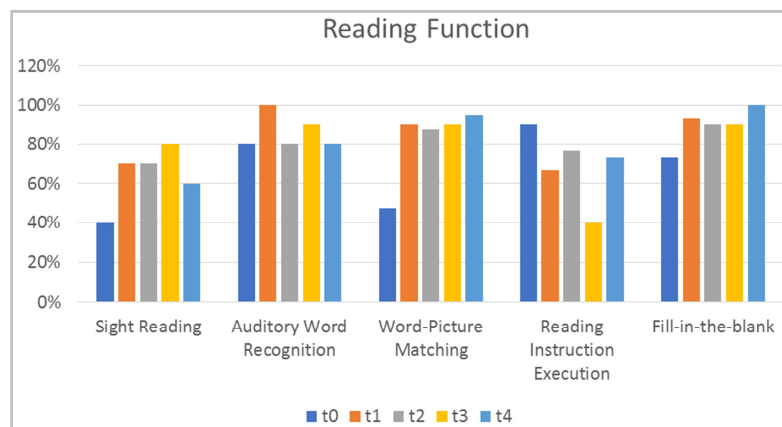


Figure 1. Reading Function Evaluation Results Bar Chart.

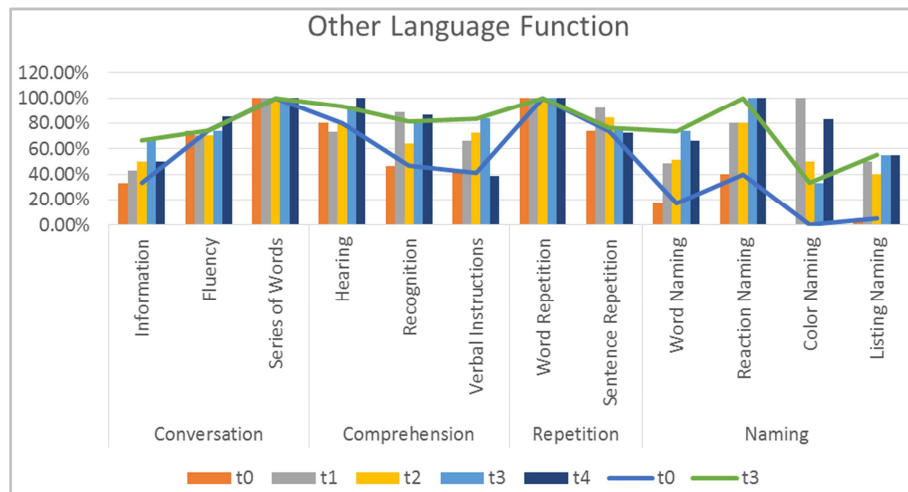


Figure 2. Mixed bar chart of remaining relevant speech functions.

4.2. Nuclear Magnetic Resonance Spectroscopy Imaging Results

The Cr/Ch, NAA/Cr of Broca area and Broca homologous area before and after treatment are shown in Table 2. The results showed that the NAA/Cr and Cr/Ch in the Broca area increased after treatment compared with before treatment (Table 2).

Tables 2. Bilateral hemispheric metabolites before and after treatment.

	Left Hemisphere				Right Hemisphere			
	Cr	Ch	Cr/Ch	NAA/Cr	Cr	Ch	Cr/Ch	NAA/Cr
t0	7766	32048	0.24232	1.33	75440	123344	0.611623	1.35
t2	21488	57632	0.37285	1.81	47712	51728	0.922363	1.69

5. Discussion

Few studies have been conducted on alexia, and few have used non-invasive brain stimulation techniques to treat alexia, supplemented by MRI spectroscopy to observe the efficacy, and only one case study reported transcranial magnetic direct current stimulation for pure alexia [3]. This case study focused on improving the lexical pathway of the patient using speech therapy on the basis of cognitive neuropsychology and improving the phonological and semantic pathway of the patient using transcranial magnetic stimulation technique, and the results showed that the patient's reading function and the rest of the speech function were improved.

In Coslett [4] Study, the acquired dyslexia is divided into surface dyslexia, phonological dyslexia and phonological dyslexia. According to Coltheart [5], in the dual-channel model, there is an impaired lexical pathway for surface dyslexia, which is compensated by the GCP pathway, i.e., by the form-sound transition pathway. The compensatory process is consistent with a regularity effect, meaning that regular words can be read while irregular words appear to be dyslexic, and false words are read according to the morphosyntactic correspondence rule [6]. The deep dyslexia is mainly manifested as semantic errors, which are explained by the dual-channel model, i.e., the lexical pathway and the GCP channel are impaired in substitution, and only the semantic pathway is preserved, but due to semantic misreading occurs. In addition, in Morton and Patterson's [7] study, it was also found that the semantic system is also

impaired in patients with deep dyslexia. Phonological mispronunciation is similar to deep mispronunciation in that patients mainly have impaired GCP pathways [15]. Unlike Western pinyin scripts, Chinese characters are image-based expressive scripts, and it remains controversial whether the mechanism of acquired dyslexia is fully consistent with the dual-channel model. However, since 80% of Chinese characters are morpho-syntactic [8] characters, which are composed of vowel and whole characters, and 1/3 of them have similar vowel and phonetic sounds, such as "tong" and "shy", this form-phonetic correspondence rule is similar to the form-phonetic correspondence rule in pinyin scripts. Brown [9] et al. showed improved results for the phoneme to grapheme training task, suggesting that adding morpho-syntactic training to semantic training may improve reading function in Chinese patients. In this case, the middle-aged patient appeared to substitute the phoneme for the whole word when reading the word. Enhanced lexical treatment (lexical treatment) or brief written language exposure treatment during speech therapy, combined with semantic training, improved the patient's sight-reading function (40% → 60%) and word-picture matching function (47.5% → 95%) at the end of the treatment, suggesting that grapheme visual recognition function or semantic input dictionary improvement was possible.

The placement of the transcranial magnetic stimulation coil in this case study was in the left hemisphere in the inferior frontal gyrus triangle, Brodmann 44, which is associated with speech processing and semantic processing, and Fahmy et al. [10] showed that high-frequency transcranial magnetism

applied to the left broca area improved speech function, including reading function [11] et al. showed that the inferior frontal gyrus plays a key role in the unification process required to comprehend sentences in reading. In this study, we found that after using high-frequency transcranial magnetic stimulation combined with speech therapy, patients' sight-reading, word-picture matching, and fill-in-the-blank functions improved compared to the pre-treatment period, but their reading-command functions relatively decreased during the t0-t3 treatment period and improved during the cessation of transcranial magnetic stimulation treatment, i.e., t3-t4. On the basis of the support of the transcranial magnetic stimulation hemispheric inhibition model, this may be due to the fact that high-frequency stimulation of the right brain is required to improve read-command executive function, and stimulation of the left cerebral hemisphere caused a competitive inhibition of the right brain.

Meanwhile, this study observed the changes in brain metabolites before and after treatment by magnetic resonance spectroscopy imaging. It was shown that NAA/Cr increased around the stroke lesion at about 6 weeks of stroke and returned to near normal levels after 1 year. Also Cr/Cho increased in the hemisphere contralateral to the lesion after stroke, probably due to plasticity and reorganization. In this case study patient, both NAA/Cr and Cr/Cho in bilateral cerebral hemispheres increased after treatment compared to before, with higher NAA/Cr in the left cerebral hemisphere than in the right cerebral hemisphere, which may be due to increased substance metabolism in the left cerebral hemisphere and improved blood circulation in the left cerebral hemisphere after transcranial magnetic stimulation combined with speech therapy, which promoted neuronal reorganization around the lesion.

6. Conclusion

Transcranial magnetic stimulation therapy combined with speech training can promote the increase of brain metabolites and improve patients' reading function, providing a new therapeutic idea for the treatment of post-stroke dyslexia. Meanwhile, the combination of repetitive transcranial magnetic stimulation technique and hydrogen proton MRI spectroscopy can be used as a non-invasive treatment-examination combination to explore the mechanisms of recovery from dyslexia. In future studies, there should be more TMS-MRS combination studies, combined with neuropsychological models, to explore the recovery mechanisms of dyslexia.

References

- [1] Obler LK, Albert ML, Goodglass H, Benson DF. aphasia type and aging. *brain and Language*. 1978; 6 (3): 318-322.
- [2] Kaji, Xue-Ping. *Cognitive neuropsychological mechanisms of Chinese dyslexia* [M.A.], Northwest Normal University; 2007.
- [3] Lacey E, Jiang X, Friedman R, et al. Transcranial direct current stimulation for pure alexia: effects on brain and behavior. *brain Stimulation: Basic, Translational, and Clinical Research in Neuromodulation*. 2015; 8 (2): 305-307.
- [4] Coslett HB, Turkeltaub P. Acquired dyslexia. *neurobiology of language*. 2016: 791-803.
- [5] Coltheart M. Writing systems and reading disorders. *orthographies and reading*: Routledge; 2017: 67-80.
- [6] Luo Wei. Types, symptoms and mechanisms of acquired dyslexia. Paper presented at: The 7th Beijing International Rehabilitation Forum 2012; Beijing, China.
- [7] Morton J, Patterson K, Coltheart M, Marshall JC. Deep dyslexia 1980.
- [8] Tong X, Yip JHY. Cracking the Chinese character: Radical sensitivity in learners of Chinese as a foreign language and its relationship to Chinese word *Reading and Writing*. 2015; 28 (2): 159-181.
- [9] Brown J, Hux K, Fairbanks S. Reading recovery: a case study using a multicomponent treatment for acquired alexia. *aphasiology*. 2016; 30 (1): 23-44.
- [10] Fahmy EM, Elshebawy HM. Effect of High Frequency Transcranial Magnetic Stimulation on Recovery of Chronic Post-Stroke Aphasia. *Journal of Stroke* 2021/08/01/ 2021; 30 (8): 105855.
- [11] Acheson DJ, Hagoort P. Stimulating the brain's language network: syntactic ambiguity resolution after TMS to the inferior frontal gyrus and middle temporal gyrus. *journal of cognitive neuroscience*. 2013; 25 (10): 1664-1677.
- [12] Rubi-Fessen I, Hartmann A, Huber W, et al. Add-on Effects of Repetitive Transcranial Magnetic Stimulation on Subacute Aphasia Therapy: Enhanced Improvement of Functional Communication and Basic Linguistic Skills. A Randomized Controlled Study. *Arch Phys Med Rehabil* 2015; 96 (11): 1935-44.e2 doi: 10.1016/j.apmr.2015.06.017 [published Online First: Epub Date].
- [13] Haghighi M, Mazdeh M, Ranjbar N, Seifrabie MA. Further Evidence of the Positive Influence of Repetitive Transcranial Magnetic Stimulation on Speech and Language in Patients with Aphasia after Stroke: Results from a Double-Blind Intervention with Sham Condition. *Neuropsychobiology* 2017; 75 (4): 185-92 doi: 10.1159/000486144 [published Online First: Epub Date].
- [14] Ren C, Zhang G, Xu X, et al. The Effect of rTMS over the Different Targets on Language Recovery in Stroke Patients with Global Aphasia: A Randomized Sham-Controlled Study. *Biomed Res Int* 2019; 4589056 doi: 10.1155/2019/4589056 [published Online First: Epub Date].
- [15] Goodglass H, Budin C. Category and modality specific dissociations in word comprehension and concurrent phonological dyslexia. *Neuropsychologia* 1988; 26 (1): 67-78.