

**Case Report**

Complete Non-puerperal Uterine Inversion in a Nulliparous Woman Due to Sub Mucous Fibroid – A Case Report

Innocent Anayochukwu Ugwu^{*}, Boniface Uwaezuoke Odugu, Celestine Chukwudi Obiora, Perpetua Kelechi Enyinna, Chude Chukwuka Eze, Innocent Igwebueze Okafor

Department of Obstetrics and Gynaecology, College of Medicine, Enugu State University of Science and Technology (ESUT) and ESUT Teaching Hospital, Enugu, Nigeria

Email address:

innocent.ugwu@esut.edu.ng (I. A. Ugwu), odugub2000@yahoo.com (B. U. Odugu), drobiora2000@yahoo.com (C. C. Obiora), perpekee@gmail.com (P. K. Enyinna), chukwukaeze78@gmail.com (C. C. Eze), okaforii@yahoo.com (I. I. Okafor)

^{*}Corresponding author

To cite this article:

Innocent Anayochukwu Ugwu, Boniface Uwaezuoke Odugu, Celestine Chukwudi Obiora, Perpetua Kelechi Enyinna, Chude Chukwuka Eze, Innocent Igwebueze Okafor. Complete Non-puerperal Uterine Inversion in a Nulliparous Woman Due to Sub Mucous Fibroid – A Case Report. *World Journal of Medical Case Reports*. Vol. 1, No. 1, 2020, pp. 5-8. doi: 10.11648/j.wjmcr.20200101.12

Received: August 11, 2020; **Accepted:** August 26, 2020; **Published:** September 7, 2020

Abstract: Uterine inversion which commonly occurs during the puerperium is the descent of the fundus of the uterus into or through the cervix thereby keeping the uterus in an 'inside out' position. Other structures such as the ovaries and fallopian tubes may also be displaced from the pelvis and restricted within the inverted uterus. However, non puerperal uterine inversion is very rare and represents about one-sixth of all inversion. The most common implicating factor in non-puerperal inversion is prolapsed fibroid with occasional reports of endometrial polyp and uterine neoplasia. Diagnosis of non-puerperal uterine inversion may pose a major problem and treatment in women of reproductive age who desire future fertility may involve conservative surgeries. Case Report: We report a case of a 35 year old nulliparous woman with complaints of sudden protrusion of a mass from her vagina with associated cramping lower abdominal pain and vaginal bleeding. A diagnosis of non puerperal uterine inversion due to sub mucous uterine fibroid was made. Surgical interventions done included excision of fibroid and rectification of the uterus through Haultain's procedure. Histology confirmed uterine fibroid and patient had resumed normal menstrual flow. Conclusion: High index of suspicion is essential for proper diagnosis of non-puerperal uterine inversion. In the setting of fertility sparing surgeries, malignancy need to be ruled out, and the woman must be counseled on interval to next pregnancy and risks associated with different modes of delivery.

Keywords Non-puerperal Uterine Inversion, Uterine Inversion, Sub-mucous Uterine Fibroid, Complete Inversion

1. Introduction

Non puerperal uterine inversion is a clinical state in which the fundus of a non pregnant uterus descends through the endometrial cavity or cervix with a resultant protrusion of the uterus into vagina or out of the body [1]. Other structures like the ovaries and fallopian tubes may be shifted from their original anatomical position into the cavity created by the inverted uterus. This condition is usually associated with uterine pathologies. Prolapsed sub mucous uterine fibroid is the most common implicating factor; however other uterine pathologies implicated include endometrial polyp and uterine neoplasm [2, 3]. The mechanism for uterine inversion is

mainly unknown, but the proposed mechanisms include thinning of the wall of the uterus as a result of an intrauterine tumor, increased tumor growth, cervical dilatation due to the tumor and sudden expulsion of the tumor [2]. This is a case report of the experience we had in the diagnosis and management of a nulliparous woman with non-puerperal uterine inversion due to prolapsed huge sub mucous fibroid.

2. Case Presentation

This is case of a 35 year old nulliparous woman who presented at the gynaecological emergency unit of our hospital. She presented with complaints of sudden protrusion of a mass

from her vagina as she was trying to defecate. The protrusion was associated with cramping lower abdominal pain and vaginal bleeding. The mass was big enough and could not allow ease of movement as it rubbed against the inner aspect of her upper thighs. She also made an unsuccessful attempt at reducing the mass. Five years prior to this presentation, she was having heavy and prolonged menstrual flow, inter-menstrual bleeding with associated dizziness following each menstrual period. She never sought any medical assistance. There was no history of chronic cough, abdominal distension, dysuria, abnormal vaginal discharge, and change in bowel habit or significant weight loss. She separated from her husband four years prior to presentation. She had no known drug allergies or chronic medical illness.

On examination, she was in painful distress, pale, afebrile, and anicteric. She had no pedal edema. Her pulse rate was 108/minute and Blood pressure was 120/70mmHg. There was mild supra-pubic tenderness. Vaginal examination revealed a huge hyperemic, bi-lobed (figure 8 shaped) fleshy, edematous mass with grayish patchy flakes and foul smelling odour. The proximal portion of the mass (inverted uterus) measured about 12cm x 6cm while the distal portion measured 6cm x 8cm in its longitudinal and transverse diameters respectively (Figure 1). There was associated contact bleeding. A clinical diagnosis of non puerperal uterine inversion and anemia probably due to uterine fibroid was made. Other differentials include endometrial polyp, endometrial cancer and uterine sarcoma. Result of her blood screening investigations, full blood count, and serum electrolyte/urea/creatinine were essentially normal except for anaemia (PCV=17%). Abdomino-pelvic ultrasound showed the presence of a significant amount of echo-rich fluid within the cul-de-sac. The uterus appeared bizarre in shape, appearing to consist of two segments within a dividing septum as well as invagination of the fundal aspect. Endometrial plate shape could not be delineated. The clinical condition of the patient was stabilized with IV fluids, blood transfusion, analgesic and antibiotics.

She was then taken to the operating theater for surgery through an abdominal and vaginal approach. The distal end of the mass (fibroid nodule) was excised from the base. There was associated bleeding and haemostatic sutures applied. An attempt to revert the uterus vaginally was unsuccessful due to gross edema. An abdominal (pfannenstiell) incision was made to gain access to the pelvic cavity. An attempt to revert the uterus using Huntington's techniques (with exertion of pressure from the vagina) was unsuccessful due to a very tight constricting ring. Haultain's procedure was performed. A longitudinal incision was made at the constriction ring which was extended to the upper uterine segment posteriorly. Patient sustained iatrogenic injury to the lower uterine segment anteriorly. The uterus was successfully reverted and normal pelvic anatomy restored.

Patient was managed postoperatively with analgesic, antibiotic and intravenous fluids. Her packed cell volume was 30% on the third postoperative day. She was discharged on the fifth post operative day. She attended three follow up visits and had resumed her normal menstrual flow. Histology report

showed a uterine vascular leiomyoma. The histological finding was discussed with the patient and she was educated and counseled on the risk of future pregnancies and delivery in view of the fact that she had vertical extension of the posterior uterine incision.

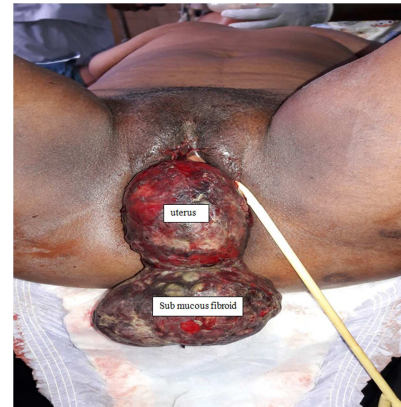


Figure 1. Vaginal view of inverted uterus and sub-mucous fibroid attached to it.

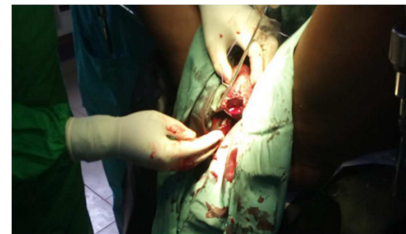

Figure 2. Myomectomy and repair of the bleeding base of excised sub mucous fibroid.

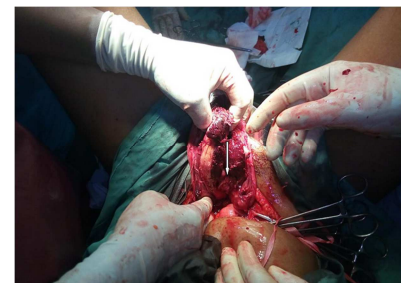

Figure 3. Abdominal view of the uterus after reversal of inversion highlighting a posterior uterine incision from cervical ring to upper uterine segment. Endometrial surface in view (see arrow).

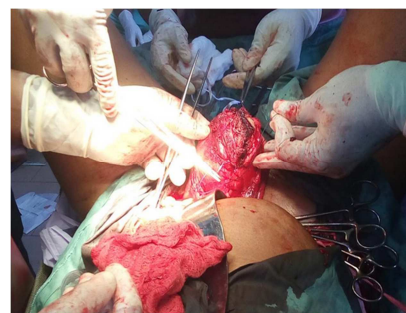


Figure 4. Abdominal view of closure of posterior uterine incision.

3. Discussion

Non puerperal uterine inversion is a rare occurrence and the incidence of the condition is mainly unknown [1]. Based on the time of onset and evolution, non puerperal uterine inversion can be classified into acute and chronic [4, 5]. The acute type is more dramatic and is associated with haemorrhage and severe pain while the chronic type is insidious and associated with irregular vaginal bleeding, vaginal discharge, pelvic discomfort and anemia. It can also be classified into complete and incomplete. It is said to be incomplete when the uterine fundus protrudes through the cervix and is lying within the vagina and complete when the whole uterus including the cervix is inverted. Our patient had heavy and prolonged menstrual flow and intermenstrual bleeding for five years which was due to the sub mucous fibroid that was left untreated and continued to grow up to the size leading to sudden complete inversion of the uterus.

Diagnosis of non puerperal uterine inversion may pose a major problem [3]. The clinical presentation is similar to that of other gynecological conditions and this may result in wrong diagnosis. However, prompt recognition of the fact that the cervix as well as the cervical os and the uterine fundus are not seen and not easily palpable, will help in diagnosis. Abdominal ultrasound shows an indentation as well as 'a longitudinal hypoechoic groove' of the uterine fundus [6]. Magnetic Resonance Imaging (MRI) is also useful in diagnosis and can delineate other lesions in surrounding structures [7]. Sagittal view of a T2 weighted image showing a U-shaped uterine cavity with an inverted and thickened fundus is diagnostic of uterine inversion [8]. Our patient had an abdomino-pelvic scan which was suggestive of uterine inversion.

Treatment of non puerperal uterine inversion oftentimes requires surgical approach because of the formation of constricting ring following contraction of the cervix and lower uterine segment. This constricting ring renders manual reduction through the vagina unsuccessful. Different surgical techniques are usually done trans-abdominally (via laparotomy or laparoscopy) and trans-vaginally. Occasionally a combination of trans-abdominal and trans-vaginal approaches may be needed to correct this condition. The Haultain and Huntington technique are the two abdominal approaches described [9]. In Huntington's procedure, the dimple or cup (containing the fallopian tubes and ovaries) created by the inversion is first identified. A pair of Allis forceps is placed on the round ligaments on both sides and an upward traction exerted. As the uterus continues to advance to a normal position with further upward pressure, this process is repeated till the inversion is fully reversed. In Haultain's procedure, a longitudinal incision is made at the constrictive ring in the cervix and then extended to the posterior uterine wall. This releases the pressure from the constricting ring and thus makes the return of the uterus, tubes and ovaries back to their anatomical positions [10]. This technique was used in our patient; however an upward push of the uterus through the vagina facilitated the reversal.

Trans-vaginally, two approaches have been described: Kustners's and Tew's procedures. In Kustners's technique, the posterior cul-de-sac is opened; the cervix and posterior wall is then incised facilitating the return of inversion. The cervical and posterior uterine wall incision is repaired in layers and then culpotomy closed [9]. The Tew's technique involves dissecting off the cervix as well as the lower uterine segment from the bladder, an anterior hysterotomy is done releasing the constricting ring and finally the inversion is returned.

Once there is a successful return of the uterus to its normal position, further management is dependent on clinical conditions, pathological result as well as patient's fertility desires [1]. Our patient uterus was successfully preserved and she was desirous of future pregnancies. There is no clear cut evidence on the correct time interval for getting pregnant after these procedures. However there is the need to address the risk of possible uterine rupture following future deliveries in women whose uteri were preserved during these procedures. Uterine rupture occurring during pregnancy and delivery is one the severe complications after a uterine surgery and this is associated with incomplete wound formation due to suturing difficulty as well as intra-corporeal tissue damage resulting from electro coagulation [11, 12]. Risk of uterine rupture increases up to 10% or even higher with use of uterotonics in women who had vertical incision that extends through the whole length of the uterus [13, 14]. Zhang and colleagues recommended a time interval of more than 12 months between surgery and subsequent pregnancy [15].

4. Conclusion

Non puerperal inversion of the uterus is a rare clinical condition and should be considered as a differential diagnosis when evaluating patients with protruding mass from the vagina. There is the need to ensure accurate diagnosis prior to surgery so as to provide proper treatment. Surgical choice of treatment in the setting of women of reproductive age is dependent on patients desire for future pregnancy, other comorbidities associated with the prolapsed inverted uterus as well as the experience and skill of the surgeon. When the uterine preservative surgery is done, it is very pertinent to counsel patients on risks associated with future pregnancy and delivery.

Consent

An informed consent was obtained from the patient for the publication of this case report and the images.

Authors' Contributions

Each of the authors made significant contributions in the management of the patient. They were all involved in drafting and critical review of the manuscript for intellectual content and have given approval for this publication.

Conflict of Interest Statement

The authors declare that they have no competing interests.

References

- [1] L. F. Pinder, K. O. Ouma, and B. D. Nelson “Non-Puerperal Uterine Inversion in a Young Woman: A Case Report, Brief Surgical Review, and Clinical Insights”, *Clin Med Rev Case Rep* 2016 3: 122. Online; Available at: <https://clinmedjournals.org/articles/cmrcr/clinical-medical-reviews-and-case-reports-cmrcr-3-122.php?jid=cmrcr> Accessed 30 July 2020.
- [2] M. De Vries, D. A. Perquin, “Non-puerperal uterine inversion due to sub-mucous myoma in a young woman: a case report”, *J Med Case Rep* 2010 4: 21.
- [3] E. Nahid (2007) “Nonpuerperal uterine inversion in a virgin woman”, *Iranian Journal of Reproductive Medicine* 5: pp. 135-136. Online; Available at: <http://www.bioline.org.br/pdf?rm07028> Accessed 5 August, 2020.
- [4] V. Gowri, “Uterine inversion and corpus malignancies. A historical review”, *Obstet Gynecol Surv.* 2000; 55: pp. 703–707.
- [5] A. Tahere, “Non-puerperal uterine inversion: A case report”, *Arch Iranian Med* 2005, 8: 63-66. Online; Available at: <http://razi.ams.ac.ir/AIM/0581/0015.pdf> Accessed 5 August 2020.
- [6] T. T. Hsieh, J. D. Lee, “Sonographic findings in acute puerperal uterine inversion”. *J Clin Ultrasound* 1991, 19: 306e9.
- [7] M. Auber, B. Darwish, A. Lefebure, J. Ness, H. Roman, “Magnetic resonance imaging of non-puerperal complete uterine”. *Iran J Radiol* 2015; 12 (4): e9878.
- [8] J. S. Lewin, P. J. Bryan, “MR imaging of uterine inversion”. *J Comput Assist Tomogr* 1989; 13 (2): 357e9.
- [9] F. Shamsudin, K. Morton (2007) “Novel correction technique of chronic puerperal inversion of the uterus”, *J Obstet Gynaecol*, 2007, 27: pp. 197-198.
- [10] M. Shivanagappa, Bhandiwad A, M. Mahesh, “A case of acute on chronic uterine inversion with fibroid polyp”. *J Clin Diagn Res* 2013, 7: PP 2587-2588.
- [11] P. Desai, P. Patel (2011), “Fibroids, infertility and laparoscopic myomectomy”. *J Gynecol Endosc Surg*; 2 pp: 36–42.
- [12] A. M. Darwish, A. M. Nasr, D. A. El-Nashar, (2005) “Evaluation of postmyomectomy uterine scar”. *J Clin Ultrasound*; 33: pp. 181–186.
- [13] R. Varma, J. K. Gupta, G. C. S. Smith, (2007) “Birth after previous cesarean birth. Royal College of Obstetricians and Gynaecologists 2007 pp. 1-17.
- [14] G. Saade, M. A. Belfort, M. R. Foley, J. P. Phelan, G. A. Dildy (2010) Etiology and Management of Hemorrhage. In: Stafford I, Belfort MA, GAD III, *Critical Care Obstetrics*. John Wiley & Sons, pp. 310-312.
- [15] Y. Zhang, K. Q. Hua “Patients' age, myoma size, myoma location, and interval between myomectomy and pregnancy may influence the pregnancy rate and live birth rate after myomectomy”. *J Laparoendosc Adv Surg Tech* 2014 A 24: PP. 95-99. Online; Available at: <https://www.ncbi.nlm.nih.gov/pmc/articles/PMC3935437/> Accessed 5 August 2020.