

Case Report

Spontaneous Renal Forniceal Rupture Secondary to Fecal Impaction

Mzyiene Mohammed^{1,*}, Ziba Ouima Justin Dieudonné^{2,*}, Adnan Ettanji¹, Bekkaoui Oussami¹, Garcia Leal Carmina¹, Manescu Mihai Razvan¹

¹Department of Urology, Centre Hospitalier de Troyes, Troyes, France

²Departement of Urology, Centre Hospitalier Universitaire Hassan 2, University Sidi Mohamed Ben Abdellah, Fez, Morocco

Email address:

dr.mzyiene@gmail.com (M. Mohammed.), ouimzib@gmail.com (Z. O. J. Dieudonné)

*Corresponding author

To cite this article:

Mzyiene Mohammed, Ziba Ouima Justin Dieudonné, Adnan Ettanji, Bekkaoui Oussami, Garcia Leal Carmina, Manescu Mihai Razvan. Spontaneous Renal Forniceal Rupture Secondary to Fecal Impaction. *World Journal of Medical Case Reports*. Vol. 2, No. 1, 2021, pp. 15-18. doi: 10.11648/j.wjmcr.20210201.15

Received: February 15, 2021; Accepted: March 1, 2021; Published: March 9, 2021

Abstract: Rupture of the pyelocaliceal cavities or rupture of the renal fornix (RFR) with retro-peritoneal extravasation of urine is a rare urological complication most frequently associated with acute obstruction of the urinary tract by a calculus. It is a potential urologic emergency and management of a fornix rupture is not standardized. The aim of this case report is to highlight fecal impaction as a rare cause of spontaneous renal fornical rupture in an elderly woman and to present our management. We present the case of a 84-year-old Ms, admitted in emergency room with an occlusive syndrome associated with acute urinary retention. An initial biological assessment was carried out objectifying: Hemoglobin 16.4 g/dl, a biological inflammatory syndrome with leukocytes at 17,500/mm predominantly neutrophils at 14,670/mm, Platelets at 1,29,000/mm, PCR at 115 mg/l, TP at 79%, Creatinine at 196μmol/l, urea at 21.8 mmol/m, serum potassium at 3.81 mmol/l, slight hyper natremia at 148 mmol/l and hypoproteinemia at 52.9 g/l. The contrast enhanced computed tomography revealed a giant fecal impaction with hydronephrosis and rupture of the fornix in connection with the giant fecal impaction. Evacuation of the fecalome and the placement of double -J ureteral stent led to a clinical and biologic improvement of the patient's health. The Computed Tomography (CT) review at 6 weeks showed a disappearance of the leakage of contrast product and the absence of dilation of the pyelo-caliceal cavities with a double -J stent in place. This case illustrates a conservative management of rupture of pyelocaliceal cavities.

Keywords: Fornix, Fecal Impaction, Jj Stent, Renal Failure, Fecalome, Urinoma, Hydronephrosis

1. Introduction

Forniceal rupture is a condition of perirenal urinary extravasation often associated with ureteral obstruction.

Rupture of the pyelocaliceal cavities or rupture of the renal fornix (RFR) with retroperitoneal extravasation of urine is a rare urological complication [1].

Indeed, the main cause of fornix rupture is ureteral compression, rarely with urethral or bladder obstruction.

The bladder and the rectum share a common embryological origin in the cloaca. The motor nerve supply of each arises from the pelvic parasympathetic outflow (S2–S4). In addition, the external anal sphincter and external urethral striated

sphincter are both innervated by the pudendal nerve and, in healthy individuals, the bladder and rectum function in harmony. Several reports have suggested that dysfunction in either one of these systems may affect the other [2, 3]. Most studies that correlated rectal and bladder dysfunction were carried out in children [4, 5] or in young women. Constipation and lower urinary tract symptoms (LUTS) are very common in the elderly but the relationship between the two conditions has not been adequately assessed.

In patients with obstructive uropathy, there is often a sharp rise in intrapelvic pressure and the collecting system may

rupture at its weakest location—the fornices. Calices of the upper and lower renal pole are mainly involved. One clinical sign of a fornix rupture is an immediate pain release. This is because of a rapid reduction of pressure within the collecting system from urine extravasation [6]. There is theoretical concern that resultant undrained urinomas can form perinephric abscesses and lead to sepsis or kidney loss [7].

We present the case of a ruptured fornix in connection with a giant fecaloma responsible for urethral compression and bilateral hydronephrosis.

1.1. History of the Disease

84-year-old Ms. P. M, initially admitted to the emergency room for acute urine retention with suspicion of occlusive syndrome.

The symptoms dated back to two days before his admission to the emergency room with the onset of abdominal pain with distended abdomen without nausea or vomiting, not passing gas and stool appearing an occlusive syndrome associated with acute retention of urine.

1.2. On Admission to Emergencies

General examination found a Conscious Patient hemodynamically and respiratory stable at 37.2, normotensive at 130/80 mmHg, eupneic at 18cycles/min and Normocardium at 86 beats/min and 99% saturation.

No edema of the lower limbs.

Abdominal examination

Distended abdomen, scar from median laparotomy, diffuse tenderness on palpation with a bladder.

Pelvic examinations:

Rectal examination which found a fecal impaction.

Pelvic touch: unremarkable.

An initial biological assessment was carried out objectifying: Hemoglobin 16.4 g/dl, a biological inflammatory syndrome with leukocytes at 17,500/mm predominantly neutrophils at 14,670/mm, Platelets at 1,29,000/mm, CRP at 115 mg/l, TP at 79%, Creatinine at 196umol/l, urea at 21.8 mmol/m, serum potassium at 3.81 mmol/l, slight hyper natremia at 148 mmol/l and hypoproteinemia at 52.9 g/l and an urine test after bladder catheterization came back positive for Klebsiella pneumoniae resistant to amoxicillin.

An injected Computed Tomography (CT-scan) was performed the same day in the emergency room after advice from nephrologists who recommended a rehydration protocol before and after the injection of the contrast product.

The Computed Tomography (CT) showed a full bladder (24x15x21cm) with dilation of the right pyelon and spontaneous hyperdensity, suggesting a urinoma on suspicion of rupture of the fornix with a left kidney also dilated [Figure 1] and rectal fecal failure [Figure 2].

Patient was taken to the operating room for placement of a double J stent on the right side with placement of a bladder catheter as recommended (image of KUB) [Figure 3].

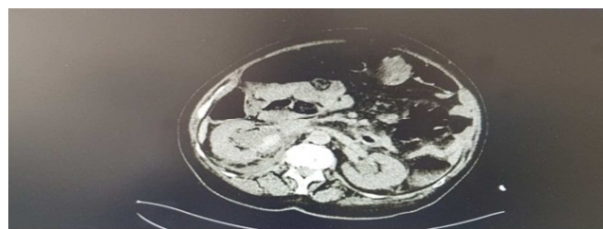


Figure 1. CT scan with injection showing spontaneous hyperdensity, suggestive of urinoma on suspicion of fornix rupture.

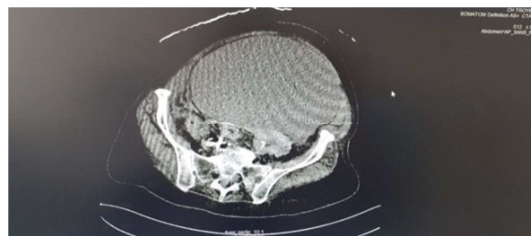


Figure 2. CT scan showing giant fecal impaction.

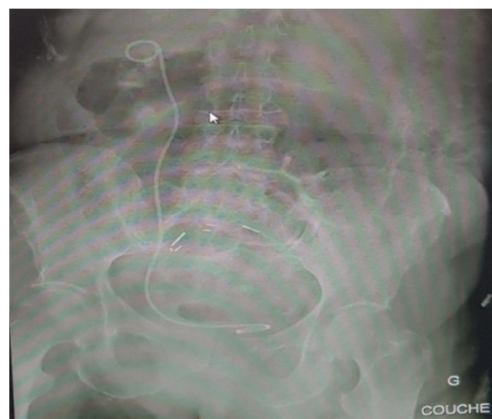

Figure 3. Image of an unprepared urinary tree showing a double J stent on the right well in place with an upper loop at the pelvis level and a loop at the bladder level for urinary diversion.

The patient's status after placement of jj stent and evacuation of the fecal impaction: a good clinical-biological improvement with a normalization of the renal function: Creatininemia at 62umol/l after urinary diversion compared to 196umol/l initially and an infectious report White blood cells at 10,100/mm³ compared to 14,100/mm³ and a PCR of 12.5mg/l compared to 119.7mg/l.

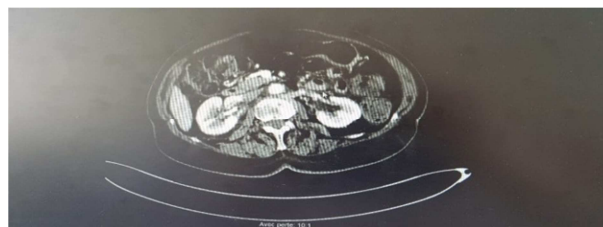

Figure 4. CT scan injected showing disappearance of the leakage of contrast material and the absence of dilation of the pyelocaliceal cavities with a JJ stent in place.

The Computed Tomography (CT) review at 6 weeks [Figure 4] showed a disappearance of the leakage of contrast product and the absence of dilation of the pyelo-caliceal

cavities with a JJ stent in place. This catheter will be removed 6 weeks after the episode resolves.

2. Discussion

Urinomas are peri-renal encapsulated collections of urine.¹² Urinomas can be produced when urine-forming kidneys rupture [7, 9, 10]. To our knowledge, this is the first reported case of fornix rupture secondary to faecal impaction.

We find in the literature several descriptions of simple dilations, in particular in relation to lithiasis, infectious and tumor pathology [6, 12, 13].

The possibility of a connection between bowel habit and LUTS had been investigated in children and women. Studies in children have linked constipation to urinary tract problems [4, 8, 11, 14, 15], including infections, enuresis, vesicoureteral reflux and upper renal tract dilation. The mechanism of these abnormalities has not been clearly defined [16].

Fecal impaction does not inevitably lead to urinary retention. This has been noted by others. Other investigators have noted that 'urinary retention caused by fecal impaction is extremely rare. In those cases in which fecal impaction and urinary retention do occur together in the same patient, the nature of urinary tract dysfunction is variable [11].

Fecal impaction may indeed cause urinary retention in certain settings. In order to identify those situations in which this may occur, it would be useful to know the mechanism by which fecal impaction induces urinary retention. Unfortunately, this area is not well understood. One proposed mechanism of urinary retention caused by fecal impaction is an extrinsic pressure effect: displacement of the bladder, bladder neck or urethra by an overdistended rectum [12].

A different explanation of how fecal impaction causes urinary retention could be postulated [17, 18]. The inflation reflex (external anal sphincter contraction in response to rectal distention) is present in approximately 50% of elderly fecally impacted patients [19]. Because the external anal sphincter and the external urethral sphincter usually have parallel activity rectal distention by feces may cause bladder outlet obstruction due to urethral sphincter contraction [20].

Rupture of the fornix is a release mechanism of the hyperpressure exerted on the renal parenchyma, renal sinus and Gerota's fascia. [3] Rupture during acute phenomena is of mechanical origin [4, 5]. In chronic pathologies, it is the gradual appearance of hydronephrosis in connection with the reflux of urine in the pyelocaliceal tracts which would have an irritant action on the urothelial tissue and which would be responsible for an inflammatory reaction and fibrosis [6, 21].

The treatment consists, in addition to the treatment of the cause, in the first installation of a ureteral catheter and in the event of failure of a percutaneous nephrostomy in the most serious cases. The literature recognizes the performance of the double J stent as a first-line treatment in the treatment of ruptures of the fornix. By allowing emptying of the urinary tract, there is a reduction in the pressure in the pyelocaliceal cavities and extravasation of perirenal urine. Withdrawal cannot be considered for 4 to 6 weeks. Concerning some

authors, Endoscopic procedures carry risk of sepsis, ureteral injury, ureteral stricture, readmissions, and undue economic burden [7].

Treating the cause is the second essential step in treatment. However, there is no consensus on how to monitor therapeutic efficacy and the onset of complications, with the clinic playing a key role [15]. Conservative management is safe in the absence of complicating factors, and antibiotics are only indicated in patients with signs of infection [7]. Intervention should be reserved to complicated cases or cases with sizable urinoma. [22].

3. Conclusion

Forniceal rupture is a complication lending to several clinical concerns. The most important are infectious.

RFR is a rare complication that can be evoked in the presence of nonspecific signs because it requires emergency management to prevent the risk of secondary complications, particularly septic [16]. Prompt imaging for confirmation of diagnosis, decompression of the renal pelvicalyceal system, and drainage of the urinoma limits morbidity. Very limited data exist in the literature regarding clinical practice in the treatment of forniceal rupture [7]. Additional investigation in this area is warranted. However, a common etiology may lead to both urinary and bowel dysfunction.

Declaration of Interests

The authors declare that they have no conflicts of interest in relation to this article.

References

- [1] Porfyrus O, Apostolidi E, Mpampali A, Kalomoiris P. Spontaneous rupture of renal pelvis as a rare complication of ureteral lithiasis. *Turk J Urol.* mars 2016; 42 (1): 37-40.
- [2] Preston DM, Lennard-Jones JE. Severe chronic constipation of young women: «idiopathic slow transit constipation». *Gut.* janv 1986; 27 (1): 41-8.
- [3] Kerrigan DD, Lucas MG, Sun WM, Donnelly TC, Read NW. Idiopathic constipation associated with impaired urethrovesical and sacral reflex function. *BJS Br J Surg.* 1989; 76 (7): 748-51.
- [4] O'Regan S, Yazbeck S, Schick E. Constipation, bladder instability, urinary tract infection syndrome. *Clin Nephrol.* mars 1985; 23 (3): 152-4.
- [5] Dohil R, Roberts E, Jones KV, Jenkins HR. Constipation and reversible urinary tract abnormalities. *Arch Dis Child.* janv 1994; 70 (1): 56-7.
- [6] Doehn C, Fiola L, Peter M, Jocham D. Outcome analysis of fornix ruptures in 162 consecutive patients. *J Endourol.* nov 2010; 24 (11): 1869-73.
- [7] Morgan TN, Bandari J, Shahait M, Averch T. Renal Forniceal Rupture: Is Conservative Management Safe? *Urology.* nov 2017; 109: 51-4.

- [8] Stathopoulos L, Merrot T, Chaumoitre K, Bretelle F, Michel F, Alessandrini P. Prenatal Urinoma Related to Ureteropelvic Junction Obstruction: Poor Prognosis of the Affected Kidney. *Urology*. 1 juill 2010; 76 (1): 190-4.
- [9] Garg PK, Mohanty D, Rath V, Jain BK. Spontaneous rupture of the renal pelvis presenting as an urinoma in locally advanced rectal cancer. *World J Clin Cases WJCC*. 16 avr 2014; 2 (4): 108-10.
- [10] Bannowsky A. Iatrogenic fornix rupture caused during retrograde manipulation of the ureter: a case report. *Cases J*. 17 nov 2008; 1: 3 20.
- [11] Gershman B, Kulkarni N, Sahani DV, Eisner BH. Causes of renal forniceal rupture. *BJU Int*. déc 2011; 108 (11): 1909-11; discussion 1912.
- [12] Setia SA, Massie PL, Epsten MJ, Sharma A, Fogg L, Cherullo EE, et al. Renal Forniceal Rupture in the Setting of Obstructing Ureteral Stones: An Analysis of Stone Characterization and Urologic Intervention Pattern. *J Endourol*. mars 2020; 34 (3): 373-8.
- [13] Larrache Y, Elidrissi Alami O, Nedjima S, Dakir M, Debbagh A, Aboutaieb R. Spontaneous renal forniceal rupture due to a bladder tumor. *Urol Case Rep*. nov 2020; 33: 101340.
- [14] Psychogenic Urinary Retention in Children: A Case Report - ScienceDirect [Internet]. [cité 27 févr 2021]. Disponible sur: <https://www.sciencedirect.com/science/article/pii/S1875957210600587>.
- [15] Gallo D, Presman D. Urinary retention due to fecal impaction in children. *Pediatrics*. févr 1970; 45 (2): 292-4.
- [16] Breun H, Csapo Z, Sigel A. [Fornix rupture--a review of pathophysiology and clinical aspects]. *Urol Ausg A*. nov 1989; 28 (6): 329-33.
- [17] Starer P, Likourezos A, Dumapit G. The association of fecal impaction and urinary retention in elderly nursing home patients. *Arch Gerontol Geriatr*. 1 févr 2000; 30 (1): 47-54.
- [18] Ney C, Hyman RM. Complete urinary retention in female. *Am J Surg*. janv 1954; 87 (1): 34-40.
- [19] Read NW, Abouzekry L. Why do patients with faecal impaction have faecal incontinence. *Gut*. mars 1986; 27 (3): 283-7.
- [20] Dg K, Ct T. Choice of electrode in electromyography of the external urethral and anal sphincters. *J Urol*. 1 juill 1980; 124 (1): 75-7.
- [21] Conde Santos G, Bielsa Gali O, Arango Toro O, Alonso Gracia N, Gelabert Más A. [Extrinsic ureteral obstruction secondary to inflammatory gynecologic pathology]. *Arch Esp Urol*. mars 2003; 56 (2): 181-5.
- [22] Al-Mujalhem AG, Aziz MSA, Sultan MF, Al-Maghraby AM, Al-Shazly MA. Spontaneous forniceal rupture: Can it be treated conservatively? *Urol Ann*. mars 2017; 9 (1): 41-4.