



Case Report

Combination Endoscopy Remove Esophageal Metal Foreign Body

Tianyu Liu^{*}, Meiling Shu, Xiaoqi Long, Zheng Zou

Department of Digestive Endoscopy Center, Suining Central Hospital, Suining, P. R. China

Email address:

58146150@qq.com (Tianyu Liu)

^{*}Corresponding author

To cite this article:

Tianyu Liu, Meiling Shu, Xiaoqi Long, Zheng Zou. Combination Endoscopy Remove Esophageal Metal Foreign Body. *World Journal of Medical Case Reports*. Vol. 2, No. 3, 2021, pp. 41-45. doi: 10.11648/j.wjmcr.20210203.13

Received: July 17, 2021; **Accepted:** July 27, 2021; **Published:** August 2, 2021

Abstract: Background: Esophageal foreign body (EFB) incarceration is a rare but devastating disorder. The most maximum risk is aortic injury. Most of the EFBs could be removed out by only one endoscopy with several accessories if there is no pierce to the aorta. Some EFBs removing needs multidisciplinary co-operation. Herein a case of successful removing by combination of two types of endoscopies is presented. Case presentation: A 40-years-male criminal swallowed a type “c” metal wire deliberately to try to escape capturing. He was diagnosed of EFB incarceration in esophagus. Ordinary chest computerized tomography (CT) in local hospital showed a type “c” metal wire was incarcerated in the esophageal muscle, and the upper hook of the wire was very close to the arch of the aorta. It was hard to remove the metal wire only by gastric endoscopy, since it was likely to occur iatrogenic injury. After combination of gastric endoscopy and rigid esophagoscopy used, the metal wire was removed successfully, and the criminal was discharged and gradually returned to normal diet. Conclusion: More co-operation or various types of endoscopy may be used in the removing of EFB, multidisciplinary and any other tools are necessary whatever works.

Keywords: Case Report, Esophageal Foreign Bodies, Metal Hooks, Gastric Endoscopy, Rigid Esophagoscopy

1. Instruction

Background

Esophageal foreign body (EFB) incarceration is a rare but devastating disorder. The most maximum risk is aortic injury [1]. Most of the EFB could be removed out by only one endoscopy with several accessories if there is no pierce to the aorta [2]. Herein a case of difficulty in removal of EFB by only one endoscopy is presented, after combination of gastric endoscopy and rigid esophagoscopy, the EFB was removed successfully. EFB incarceration in the esophagus was often reported. Mostly, it was occurred; but occasionally, someone performed it deliberately, such as acrobats and criminals. Fetal complications of EFB incarceration in the esophagus demand emergency removing operation; otherwise, it is likely lead to death [3]. In the process of removing, many tools may be used to solve various of situation, and multidisciplinary co-operation is also necessary [4]. This case report is a case of successful removing of esophageal metal foreign body

incarceration by combination of gastric endoscopy and rigid esophagoscopy.

2. Case Presentation

2.1. Chief Complaints

A 40-years-male criminal swallowed a type “c” metal wire to avoid imprisonment after 48 hours of arresting by policemen.

2.2. History of Present Illness

The patient felt just a bit of retrosternal pain. There was no sense of breathing difficulties, swallowing obstruction, drinking choking cough or any other uncomfortable symptoms. Ordinary chest computerized tomography (CT) in local hospital showed a type “c” metal wire was incarcerated in the esophageal muscle, and the upper hook of the wire was very close to the arch of the aorta.

2.3. History of Past Illness

The patient had no previous medical history and no specific family history.

2.4. Physical Examination

At admission, the patient's temperature was 36.5°C, heart rate was 86 bpm, respiratory rate was 18 breaths per minute, blood pressure was 128/76 mmHg, height was 176 cm, and weight was 78.5 kg. No other special findings were reported.

2.5. Laboratory Examinations

Routine blood tests, including white blood cell count of $6.5 \times 10^9/L$, mainly neutrophils 64%, hemoglobin

concentration 167 g/L were normal, blood platelet $189 \times 10^9/L$. The blood biochemistries were also normal. The hypersensitive C-reaction protein was below 0.499mg/L, and fecal occult blood was negative.

2.6. Imaging Examinations

Enhanced CT and 3-dimensional CT angiography (3D-CTA) were used to detect the position of the metal wire, and to evaluate the pathway and the risk of removing operation. No free gas or mediastinal abscess was found in the mediastinum (Figure 1).

2.7. Final Diagnosis

Metal EFB incarceration in esophagus.

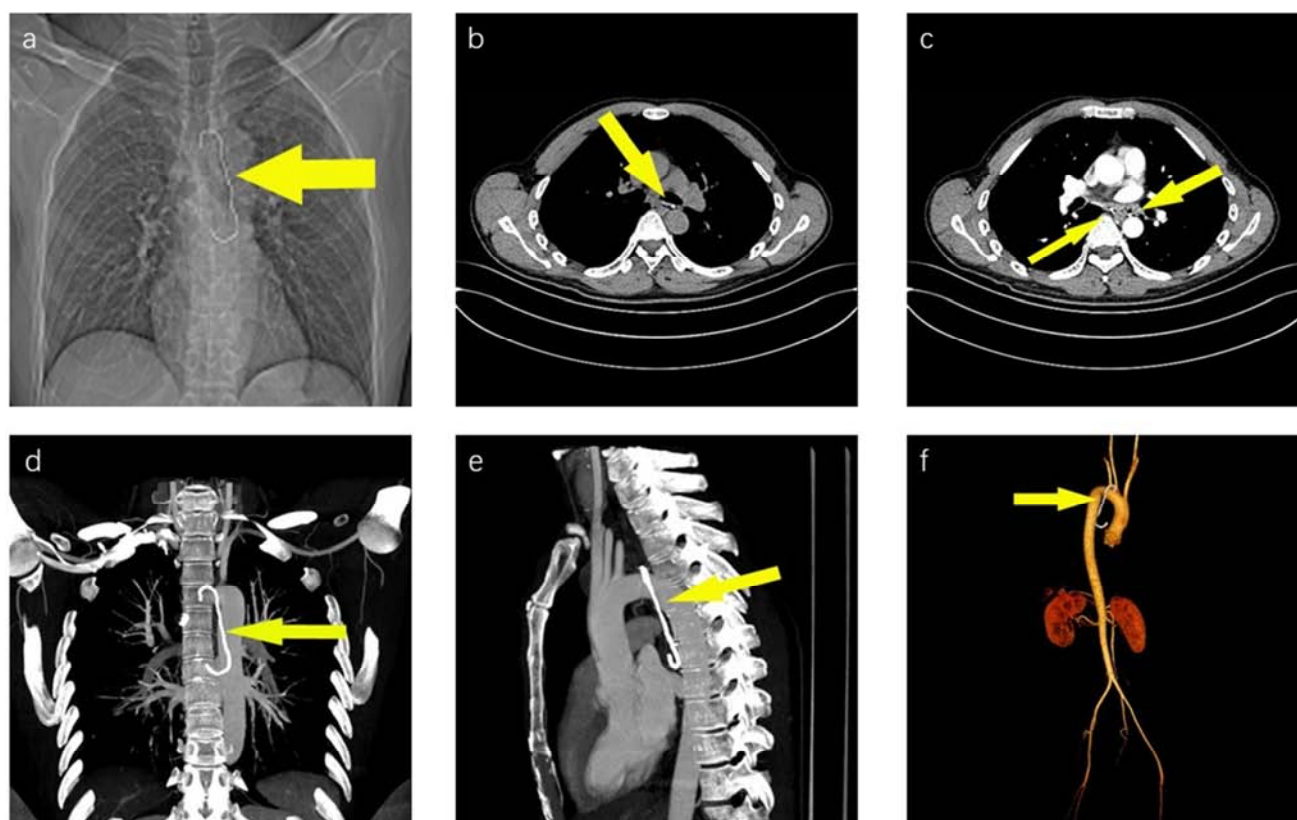


Figure 1. Computed tomography: a coronal fluoroscopy showed a metal wire incarcerated in esophagus (yellow arrow); b the metal wire was almost insert into the aorta (yellow arrow); c enhanced CT showed no contrast extravasation from the aorta (yellow arrow); d coronal CT angiography showed spatial position from the metal wire to aorta (yellow arrow); e sagittal CT angiography showed spatial position from the metal wire to aorta (yellow arrow); f 3D-CTA reconstruction of blood vessels showed spatial position from the metal wire to aorta (yellow arrow).

3. Treatment

After the criminal was general anesthetized, gastric endoscopy was firstly used to locate the metal wire and try to remove it. The upper hook of the metal wire was incarcerated in the esophageal muscle 25cm from the incisors, and the lower hook was also incarcerated in the esophageal muscle 35cm from the incisors. The upper hook was firstly removed out upwards by forceps, and then we rotated it slightly to make sure it would not incarcerate into the muscle again; and then the lower hook was also removed out downwards successfully.

But trouble was soon coming. We found it was impossible to pull it out because of the large diameter of the lower hook, it was easy to incarcerate into the muscle again. It seemed impossible to accomplish this operation. A laryngoscope physician was invited for intraoperative consultation. After examined by rigid esophagoscopy, the metal wire was soon fetched out by a long handle tweezers. Gastric endoscopy was used to examine the esophagus again, it showed the two fistulas were not enlarged, and the contralateral mucosa was just shallow scratched of a small scale (Figure 2). After 24 hours of stay in hospital of observation, no choking cough and retrosternal pain happened, and then the criminal was

discharged and was sent back to imprisonment.

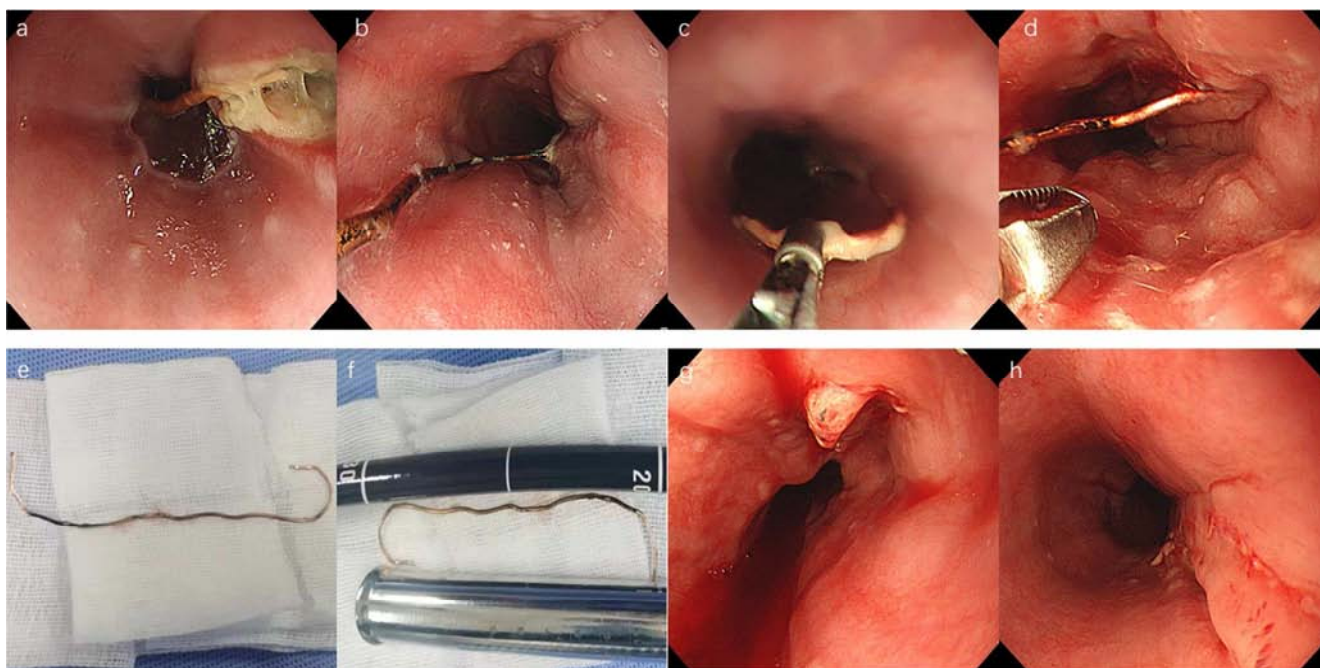


Figure 2. Endoscopy view: a the upper hook was incarcerated into esophageal muscle 25cm from the incisors; b the lower hook was incarcerated into esophageal muscle 35cm from the incisors; c the upper hook was removed out; d the lower hook was removed out but incarcerated again; e the metal wire was removed out by rigid esophagoscopy; f the metal wire was measured by both gastric endoscope and rigid esophagoscope; g the lower fistula was observed again; h the upper fistula was observed again.

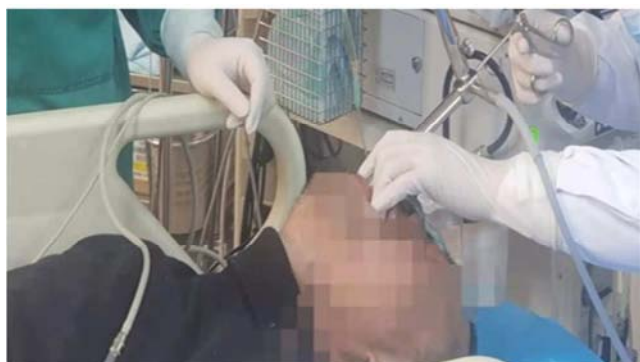

Figure 3. Supplementary: the metal wire was removed out successfully by rigid esophagoscopy.

4. Discussion

Many complications are reported of associated with EFB [5] or operation of removing [6, 7]. Fistulas are often reported of caused by fish bone [8], metal nail [9] and date pit [10], and then complications follow, such as mediastinal infection [11], esophageal rupture [12] and esophagobronchial fistula [13]. The maximum risk is aortic injury, it causes rapid hemorrhagic shock, and results to high fatality rate [14]. Although the combined strategy of endovascular and endoscopic treatment succeeds sometimes [15], but more cases are dead of lack of vascular protection. Long term complications can also be caused by EFB, such as esophageal scar stricture [16], mediastinal abscess [17]. So adequate preoperative assessment is important and necessary.

Symptoms and physical examination provide important clue to the order of severity; enhanced CT or 3D-CTA can exhibit the exact location of the esophageal foreign body and the spatial distance from surrounding organs and tissues [18, 19].

In this case, 3D-CTA of the esophagus and aorta revealed the upper hook of the metal wire was almost insert into the aorta, it was just 2mm away from the arcus aortae. Consider the above, we decided to remove the upper hook upwards firstly to avoid iatrogenic injury. The following challenge was to remove the lower hook, there were two dangers we found in the process of removing. Firstly, when we tried to pull out the lower hook downwards, the upper hook was easily to incarcerate into the esophageal muscle again. Fortunately, it did not happen. Another trouble was how to pull out the metal wire, because the large diameter of the lower hook was easily to insert into the esophageal muscle again, violent pull must lead to esophageal rupture. Some tools were needed to protract the esophagus. Nothing was more appropriate than a rigid esophagoscope. The laryngoscope physician firstly entangled the whole metal wire into the rigid pipe with a forceps, and then pulled it out soon. It cost just several seconds. In the whole process, carbon dioxide was injected to expanse the tract, and after removing, we did not use anything to close the fistulas. The carbon dioxide was quickly absorbed, it could reduce the risk of fistula; and we left the fistula opened, it could keep drainage of the fistula. On the basis of the above work, the criminal recovered eating and drinking after 24 hours.

In the past, EFB was usually reported of many types,

such as straight, triangle, circular and even spherical [20-21], some EFBs were reported with only one hook [22, 23]. In this case, two hooks of a metal wire were both incarcerated in the same direction in esophagus, it increased the difficulty and risk of removal. And in regard to the method of removing, most reports recorded only one endoscopy used, gastric endoscopy, laryngoscopy or rigid esophagoscopy. In this case, gastric endoscopy and rigid esophagoscopy were sequential used to remove the metal wire because of the special type and size of the hooks. It cannot be removed out of mucosa and muscle only by rigid esophagoscopy, and it cannot be removed out of esophagus without rigid esophagoscopy.

5. Conclusion

In summary, certain EFB may be difficult to remove out by only one endoscopy or one tool. In the future, more co-operation or various types of endoscopy may be used in the removing of EFB, multidisciplinary and any other tools are necessary whatever works.

Abbreviations

EFB: Esophageal foreign body; CT: Computed tomography; 3D-CTA: 3-dimensional CT angiography.

Authors' Contributions

LTY, LXQ found this patient and conceived the study; SML performed the gastric endoscopy treatment; LTY drafted the article; ZZ worker as an assistant in the treatment. All authors read and approved the final manuscript.

Funding

This study was funded by a grant from the Youth Innovation Project of Medical Research in Sichuan Province of China (Grant No. Q18046).

Availability of Data and Materials

All data generated or analyzed during this study are included in this published article.

Consent for Publication

Written consent was obtained from the patient for the patient's personal or clinical details along with any identifying images to be published in this study.

Acknowledgements

We would like to thank Heng Huang of performing the rigid esophagoscopy; thank Guohua Qi of providing anesthetic assistance.

References

- [1] E M Kil'dyushov, E V Egorova, A N Kuzin, et al. Foreign body in the esophagus as a reason to assess the medical aid quality during the forensic medical examination [J]. *Sud Med Ekspert.* 2021; 64 (1): 48-50.
- [2] Zhang X, Liu J, Li J, et al. Diagnosis and treatment of 32 cases with aortoesophageal fistula due to esophageal foreign body [J]. *Laryngoscope.* 2011; 121 (2): 267-72.
- [3] Lafferty M, Lyttle MD, Mullen N, et al. Ingestion of metallic foreign bodies: A Paediatric Emergency Research in the United Kingdom and Ireland survey of current practice and hand-held metal detector use [J]. *J Paediatr Child Health.* 2021 Mar 15.
- [4] Jenny Bui, Hadley Wilson, Luigi Pascarella, et al. Multidisciplinary Management of an Aorto-esophageal Injury Caused by Foreign Body Ingestion [J]. *Ann Vasc Surg.* 2020 Dec 14; S0890-5096(20)31027-X.
- [5] Li WX, Dong Y, Zhang A, et al. (Management of deep neck infections from cervicale sophageal perforation caused by foreign body: A case series study [J]. *Am J Otolaryngol.* 2021 Mar-Apr; 42 (2): 102870.
- [6] Hauge T, Kleven OC, Johnson E, et al. (Outcome after accidental food bolus-induced esophageal perforation [J]. *Scand J Gastroenterol.* 2018 Aug; 53 (8): 905-909.
- [7] Chang S, Cheng BC, Huang J, et al. Classification and surgical treatment of intrathoracic esophageal injury caused by foreign body [J]. *Zhonghua Wai Ke Za Zhi.* 2006 Mar 15; 44 (6): 409-11.
- [8] Zhao S, Tinzin L, Deng W, et al. Sudden Unexpected Death Due to Left Subclavian Artery-esophageal Fistula Caused by Fish Bone [J]. *J Forensic Sci.* 2019 Nov; 64 (6): 1926-1928.
- [9] Vats M, Ramasamy S, Neogi S, et al. Ingestion of nine metallic nails with corrosive: what happened next? [J]. *BMJ Case Rep.* 2017 Nov 21; 2017: bcr2017222338.
- [10] Kevin M Lichtenstein, Thomas B Russell, Julia B Lichtenstein, et al. A date pit induced aorto-oesophageal fistula: a case report and concise literature review [J]. *Oxf Med Case Reports.* 2021 Feb 15; 2021 (2): omaa140.
- [11] Ojio H, Tanaka Y, Sato Y, et al. A case of submucosal abscess of the esophagus mimicking a mediastinal abscess [J]. *Clin J Gastroenterol.* 2020 Nov 27.
- [12] Ruan WS, Lu YQ. The life-saving emergency thoracic endovascular aorta repair management on suspected aortoesophageal foreign body injury [J]. *World J Emerg Med.* 2020; 11 (3): 152-156.
- [13] Yanagihara T, Ichimura H, Kobayashi K, et al. Successful Surgical Closure of an Esophagobronchial Fistula Caused by a Foreign Body in the Esophagus of a Female Octogenarian with a Delayed Diagnosis: A Case Report [J]. *Ann Thorac Cardiovasc Surg.* 2018 Jun 1.
- [14] Jiang D, Lu Y, Zhang Y, et al. Aortic penetration due to a fish bone: a case report [J]. *J Cardiothorac Surg.* 2020 Oct 2; 15 (1): 292.

- [15] Yu-Yan Zhang, Shan Li, Xiang-Lei Yuan, et al. Aorto-esophageal fistula caused by fishbone ingestion: a case report on staged endovascular and endoscopic treatment [J]. BMC Gastroenterol. 2021 Feb 2; 21 (1): 46.
- [16] Shaffer AD, Jacobs IN, Derkay CS, et al. Management and Outcomes of Button Batteries in the Aerodigestive Tract: A Multi-institutional Study [J]. Laryngoscope. 2021 Jan; 131 (1): E298-E306.
- [17] Berry AC, Draganov PV, Patel BB, et al. Embedded pork bone causing esophageal and an esophagus-innominate artery fistula [J]. Case Rep Gastrointest Med. 2014: 969862.
- [18] Sammer MBK, Kan JH, Somcio R, et al. Chest CT for the Diagnosis of Pediatric Esophageal Foreign Bodies [J]. Curr Probl Diagn Radiol. 2021 Mar 8: S0363-0188(21)00047-5.
- [19] Chang JM, Yoo YS, Kim DW. Application of Three-dimensional Reconstruction in Esophageal Foreign Bodies [J]. Korean J Thorac Cardiovasc Surg. 2011 Oct; 44 (5): 368-72.
- [20] Wu WT, Chiu CT, Kuo CJ, et al. Endoscopic management of suspected esophageal foreign body in adults [J]. Dis Esophagus. 2011 Apr; 24 (3): 131-7.
- [21] Zhong Q, Jiang R, Zheng X, et al. Esophageal foreign body ingestion in adults on weekdays and holidays: A retrospective study of 1058 patients [J]. Medicine (Baltimore). 2017 Oct; 96 (43): e8409.
- [22] N'Gattia KV, Kacouchia NB, Kouassi YM, et al. Extraction of the esophageal foreign bodies by cervicotomy: our experience about 9 cases [J]. Rev Laryngol Otol Rhinol (Bord). 2011; 132 (2): 123-8.
- [23] Valente AL, Parga ML, Velarde R, et al. Fishhook lesions in loggerhead sea turtles [J]. J Wildl Dis. 2007 Oct; 43 (4): 737-41.