

Case Report

Mature Cystic Teratoma in the Head of the Pancreas: An Unexpected Finding

Juan Jose Andrade-Rojas¹, María José Lizardo-Thiebaud¹, Guillermo Andrade-Orozco¹, Leonel Contreras-Loera², Nelsy Liseth Garza-Hinojosa³, Maria Guadalupe Jazmín De Anda-Gonzalez^{1, *}

¹Department of Anatomic Pathology, Instituto Nacional de Ciencias Médicas y Nutrición Salvador Zubirán, Mexico City, Mexico

²Department of Anatomic Pathology, Hospital Central Doctor Ignacio Morones Prieto, San Luis Potosí, Mexico

³Department of Dermatology, Centro Medico Nacional del Noroeste UMAE25, Nuevo Leon, Mexico

Email address:

deandajaz@hotmail.com (M. G. J. De A. González)

*Corresponding author

To cite this article:

Juan Jose Andrade-Rojas, María José Lizardo-Thiebaud, Guillermo Andrade-Orozco, Leonel Contreras-Loera, Nelsy Liseth Garza-Hinojosa, Maria Guadalupe Jazmín De Anda-Gonzalez. Mature Cystic Teratoma in the Head of the Pancreas: An Unexpected Finding. *World Journal of Medical Case Reports*. Vol. 2, No. 3, 2021, pp. 55-61. doi: 10.11648/j.wjmcr.20210203.16

Received: August 13, 2021; **Accepted:** August 24, 2021; **Published:** August 31, 2021

Abstract: Background: Teratomas are tumors that arise from germ cells in mature gonads and along the midline as extragonadal teratomas. The latter are infrequent, with few cases having been described in the pancreas. Objective: Our aim is to emphasize the importance of determining the histological features of extragonadal teratomas. Case presentation: We present the case of a mature cystic teratoma in the pancreas with focal neuroendocrine differentiation identified in a thirty-five year old male patient with no apparent symptomatology of a pancreatic tumor. The tumor was an unexpected finding made upon a diagnostic approach for SARS-CoV-2 infection. Discussion: At present, there are around fifty reported cases of teratomas in the pancreas. The majority of these are dermoid cysts. Few are mature cystic teratomas, and there is one reported case of an immature teratoma. Of the mature cystic teratomas reported in the literature, one presented a somatic neoplasm. Conclusion: The case highlights the importance on determining the histological features of extragonadal teratomas, including each type of tissue, the degree of differentiation and the presence of benign or malignant neoplasms, as these elements are key to classify teratomas appropriately.

Keywords: Germ Cell Tumors, Extragonadal Teratoma, Mature Teratoma, Pancreas, Pathology

1. Introduction

Teratomas are tumors that arise from germ cells in mature gonads. They are composed of tissues derived from at least two of the three germ cell layers [1]. However, they may develop in any site along the midline, being the mediastinum, the omentum, the retroperitoneum, the sacrococcygeal region and the cranium the most frequent sites of extragonadal teratomas. This phenomenon is explained by the processes that arise during embryogenesis. Germ cells migrate from the yolk sac through the midgut towards the primitive gonads. The pancreas is the least frequent location for these germinal neoplasms, which makes our case an exceptional finding [10, 12, 32].

In an attempt to explain the relationship between the potency

of the precursor cancer cell and the resulting morphology of the tumor, a team based in the Netherlands developed a classification for Germ Cell Tumors (GCT) [11, 27]. The precursor cell in most germ cell tumors seems to be a primordial germ cell (PGC), derived from an epiblast. It has a latent potency state determined by its epigenetic status, which may be reprogrammed spontaneously, leading to neoplastic growth.

Reprogramming occurs due to factors found within the microenvironment. As PGCs migrate, they differentiate and mature according to the surrounding tissue. If they fail to do so, they maintain the PGC phenotype, or develop a more primitive phenotype, and become at risk of neoplastic transformation.

Extragonadal teratomas derive from mismigrated, reprogrammed PGCs, as supported by the epigenetic status of the tumor itself: the state of global methylation and genomic

imprinting. Their developmental potential then explains their capacity to form structures derived from the three germ layers [27]. The ectoderm gives rise to squamous epithelium, adnexal structures and the neuroectoderm (including the cerebellum, glia and ependyma). Mesodermal derivatives include adipose tissue, cartilage, bone and smooth muscle. Gastrointestinal epithelium, respiratory epithelium and glandular structures like salivary and the thyroid gland are derivatives of the endoderm.

Depending on the age group, the pathologic characteristics determine a different prognosis [23, 25, 35]. Congenital or neonatal teratomas are commonly immature; nonetheless, this component is not predictive of malignant behavior. In a decreasing order, the most common sites are the sacrococcygeal, the intracranial, the mediastinal, the head and neck region and retroperitoneum. In childhood or prepuberal age, the incidence of teratoma decreases. The most common sites in this age group are mediastinal, sacrococcygeal and abdominal or retroperitoneal. Adult or post-puberal extragonadal GCT have an adverse prognosis, especially for thoracic tumors. The most common anatomic site for extragonadal teratomas in adults is the mediastinum, accounting for 43% of all GCT. Other sites include the intracranial region, the neck and the sacrococcygeal region. If a teratoma is found in the retroperitoneum, it is usually a metastatic phenomenon [23].

Teratomas are classified according to their tissue components (specifically the components that predominate) and maturity. Immature teratomas are characterized by variable amounts of immature tissues, principally mitotically active neuroectodermal tubules and rosettes [37]. As mentioned before, mature teratomas are composed of mature tissues, hence, they are considered benign tumors. Nonetheless, a mature component may give rise to a benign or a malignant neoplasm. Malignant neoplasms include squamous carcinoma, melanoma, sebaceous carcinoma and adenocarcinoma.

Monodermal teratomas are a subtype of mature teratomas [37]. They encompass:

- Struma Ovarii: it is a mature teratoma in which mature thyroid tissue is the predominant component.
- Ovarian carcinoid: it is a well-differentiated neuroendocrine tumor (NET) resembling those in the gastrointestinal tract. They are classified depending on their growth pattern.
- Neuroectodermal-type tumors: these are malignant tumors characterized by a small round cell proliferation or by a variable degree of glial or neuronal differentiation.
- Monodermal cystic teratomas: it is a benign cystic tumor composed of tissues derived from one germ layer (ectoderm or endoderm) excluding struma ovarii, carcinoid and neuroectodermal type tumors.

There have been few cases reported in the literature of mature teratomas in the pancreas, most of them being monodermal cystic teratomas. By reporting the unexpected finding of a mature cystic teratoma in pancreas with carcinoid differentiation, our aim is to emphasize the importance of determining the histological features of extragonadal teratomas.

2. Case Presentation

A 35 year old male patient was admitted to our hospital due to a moderate SARS-CoV-2 infection. The patient had no other relevant history. During his hospitalization, a CT scan was performed. A tumor in the head of the pancreas was incidentally found. After a thorough interrogation and physical examination, the patient described a two-week pulsating, intermittent, moderate pain on the left flank, which was exacerbated by deep palpation on the epigastrium and elicited no irradiation. The pain was accompanied by early satiety. The laboratory studies were within normal range. Therefore, an MRI was performed, reporting the presence of a cystic mass in the head of the pancreas measuring 7.11 x 5.33 x 4.57 cm, with a hemorrhagic and mucinous/proteinaceous content. The clinical team decided to perform an endoscopic ultrasound, where a macrocystic lesion of 7.87 cm was observed within the neck of the pancreas; it had no communication with the pancreatic duct. Fluid samples were taken for analysis, reporting a CEA 5740 mg/L, glucose 10 mg/L, amylase 262 mg/L, and a negative CA19-9.

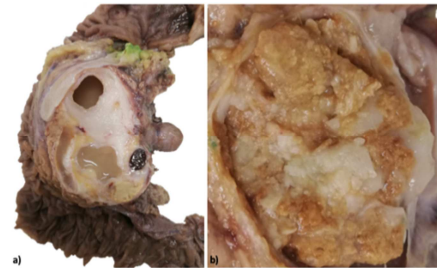


Figure 1. a) Macroscopic examination showed a heterogenous tumor in the head of pancreas, with cartilaginous tissue and several cysts. b) One of the cysts was filled with sebaceous secretion and contained light-colored hair.

The patient was evaluated by the general surgery service, who performed a Whipple procedure. During the postoperative days, the presence of retroperitoneal hematoma adjacent to the pancreato-jejunal anastomosis was identified, requiring a percutaneous drainage. During follow-up, the patient had an adequate evolution, with no gastrointestinal symptoms

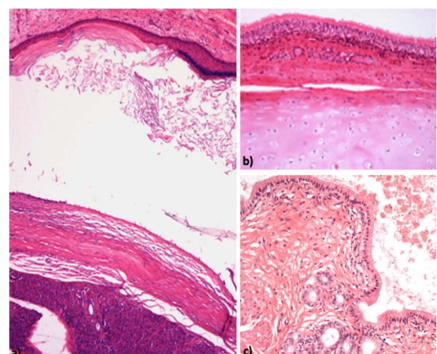


Figure 2. Microscopic examination (hematoxylin and eosin (H&E), 10x magnification) showed several mature tissue including a) squamous epithelia covering a cystic cavity; b) columnar pseudostratified respiratory epithelia and hyaline cartilage beneath it; c) columnar epithelia with microvilli covering a cystic cavity.

We received a Whipple specimen with a 5.1x4.7x8.4 cm tumor at the head of the pancreas. At grossing, we identified cartilaginous tissue and cystic cavities filled with light brown serous fluid as well as keratin. Several light-colored hairs were identified upon section (see Figure 1).

On microscopic examination, the cystic walls were lined by ciliated columnar and squamous epithelia, with production of mucin and keratin, adjacent to them were areas of mature cartilage and nerves (see Figure 2). We identified a 3 mm focus of a typical carcinoid tumor with a proliferative index of <1% (see figure 3).

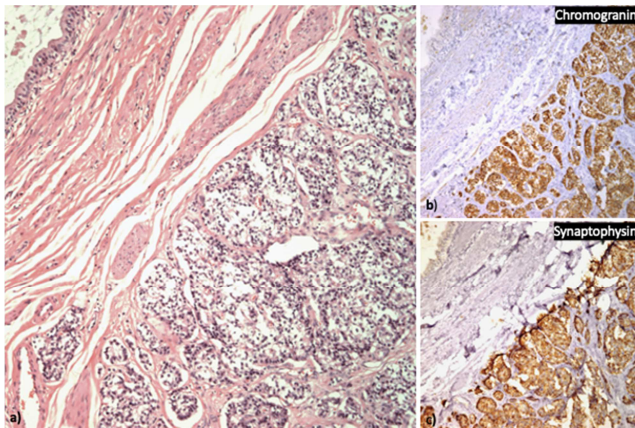


Figure 3. a) Microscopic examination (H&E, 10x magnification) of a focus of carcinoid tumor adjacent to a cystic wall lined by columnar epithelia. The neuroendocrine cells are disposed in sheets and nests, separated by a delicate fibrovascular network. These groups of cells expressed both a) chromogranin A and b) synaptophysin.

3. Discussion

The first case of a pancreatic teratoma was reported in 1918 by Kerr [10, 18, 32]. By 2010, there were only thirty-two cases described [9, 13-15, 22, 24, 29, 30, 33, 34, 36, 40, 41]. At present, ours would be number fifty-one (see Table 1 in Appendix). Pancreatic teratomas occur predominantly in males, in a ratio 1:2, and are diagnosed in patients with a median age of 45.5 years. Most patients (80%) were symptomatic at diagnosis. The principal signs and symptoms were abdominal pain, nausea, vomit, weight loss and a palpable abdominal mass, which are non-specific as they may reflect the presence of other pancreatic neoplasms. Few cases (16%) were asymptomatic, being diagnosed incidentally by image studies [4, 10, 16, 28, 33].

We found thirteen case reports of pancreatic teratomas in children [8-10, 15, 18, 32, 39, 40]. It occurs in the same proportion in females and males, with the median age at diagnosis is 2 years. The clinical presentation varied, with half of them presenting nausea and vomit. All the cases presented a palpable mass when examined.

Tumoral biomarkers, like CEA, CA 19.9, and alpha-fetoprotein (AFP), were measured in 15 out of the 36 cases reported in adults. In all the cases presented, only CA 19.9 was reported as high (5 out of 13 cases) [18, 20, 31, 36, 42]. In the case report from Zhou et al in 2020, they found that

a significant elevation of CEA and CA 19-9 could relate to a malignant lesion [42]. However, they highlight that imaging techniques, like an abdominal ultrasound, CT and magnetic resonance, can better differentiate among types of lesions. Most of the cases report normal levels of pancreatic enzymes [2, 6, 18, 29, 31, 34, 36, 42]; Markovsky reported a case of a teratoma in the body of the pancreas in a 53 year old female patient with significant amylase elevation but it may be explained by the inflammatory process in the pancreas [22].

The head of the pancreas was the most frequent site accounting for 44.8% (22) of the cases, in both pediatric and adult population, which coincides with the data already found in the literature [10]. The imaging findings vary, some being uniloculated cysts [1, 10, 13, 17-19, 33, 36, 39, 40], while others are complex, multiloculated cysts [5, 7, 16, 21, 22, 24, 26, 29, 30, 33, 41] or both a solid and a cystic component predominates [2-4, 6, 8, 15, 20, 28, 32, 34, 38, 42] diameter while in the pediatric population, it was of 10.68 cm.

When grossing, the cystic content of the teratoma is pasty, with abundant sebaceous secretion, as was found in our case [24 already mentioned, teratomas are further classified in immature, mature and highly specialized (NET, struma ovarii and neuroectodermal-type tumors) [31st of the cases reviewed reported dermoid cysts, a cystic cavity lined by squamous epithelium and a combination of other structures like dermal appendages and lymphoid aggregates [2, 32] Only one case, described by Manoj Kela in 2008, found in a 5 month old patient, had the histopathological finding of an immature epithelial component [14]. Our case presented a focal neuroendocrine tumor. To our knowledge, there has been only one case of a NET in a mature pancreatic teratoma. This case was described in 2007 by Rivkine et al [17]. The tumor was a 5x5 cm mature cystic teratoma found in the uncinate process, with a 3 mm lesion with chromogranin A expression and a proliferative index of 1%.

Besides neoplastic processes and immature components, teratomas may be mixed. This is more frequent in gonadal teratomas. However, a case was described in 2013 by Wang et al, in a one year old patient [42]. The patient presented jaundice, an AFP of 9550 ng/ml; the tumor was found in the head of the pancreas, measuring 5x4x3 cm. Microscopic examination revealed a mixed germ cell tumor with endodermal sinus tumor tissue and a mature squamous epithelia from the teratoma.

4. Conclusions

Extragenital teratomas are a rare finding in the pancreas. They remain a diagnosis of exclusion. However frequent mature components are, assiduous attention must be kept in characterizing the entire lesion. We report a case of a mature cystic teratoma in the pancreas with components from all three germ cell layers. After meticulous sampling, a focus of a somatic neoplasm was identified. Areas with somatic neoplasms or areas with immature components validate the need of rigorous sampling to identify the predominant component of the teratoma, classify it adequately, and discard

secondary malignant transformation.

Appendix

Table 1. Reported cases of pancreatic teratoma in the literature.

Year Pub	Author	Age	Sex	Symptoms	Signs	CEA ng/ml	CA 19-9	Location
1918	Kerr	55	F	Epigastric swelling	palpable Palpable mass, RUQ	Unknown	Unknown	Head
1921	Judd	33	F	Backache, weakness	palpable Palpable mass, LUQ	Unknown	Unknown	Tail
1923	Dennis	40	M	Backache	Palpable mass, RUQ and epigastrium	Unknown	Unknown	Head
1943	Decourcy JL	2	F	Vomiting	Palpable mass, epigastrium	Unknown	Unknown	Body
1956	Hoang-su	18	M	Abdominal	Palpable mass, epigastrium	Unknown	Unknown	Unknown
1970	Bittner	2	F	Liver failure	Palpable mass, epigastrium	Unknown	Unknown	Head
1972	Iovchev	8	M	Abdominal pain, vomiting, fever	Palpable mass, LUQ	Unknown	Unknown	Body
1973	Pomosov	6	M	Abdominal pain, vomiting	Palpable mass, LUQ	Unknown	Unknown	Tail
1973	Komarov	4	F	Abdominal pain, vomiting	Palpable mass, epigastrium	Unknown	Unknown	Unknown
1977	Assawamatiyanont S	11	F	Asymptomatic	Palpable mass	Unknown	Unknown	Body
1984	Lazaro da Silva A	21	M	Nausea, constipation	Palpable mass, LUQ	Unknown	Unknown	Head
1990	Mester M	25	F	Abdominal pain, vomiting	RUQ tenderness	Unknown	Unknown	Head
1990	Vermeulen BJ	46	M	Abdominal pain	None	Unknown	Unknown	Body
1993	Markovsky V	53	F	Abdominal pain	Palpable mass, LUQ and epigastrium	Unknown	Unknown	Body
1993	Jacobs JE	57	F	Abdominal pain, weight loss	None	Unknown	Unknown	Body
1993	Iacono C	26	F	Abdominal pain, fever, weight loss	Palpable mass, RUQ	2.1	Unknown	Head
1993	Kraimps JL	42	M	Weight loss, dyspepsia, nausea	None	Unknown	Unknown	Head
1996	Das PC	0.4	F	Asymptomatic	Palpable mass, LUQ	Unknown	Unknown	Body, Tail
1998	Fernandez-Cebrian JM	74	M	Backache, dysuria	Palpable mass, LUQ	Unknown	Unknown	Body
2002	Strasser G	44	M	Abdominal pain	None	Unknown	Unknown	Uncinate process
2003	Yu CW	2	M	Asymptomatic	Epigastric Palpable mass	Unknown	Unknown	Head and body
2004	Salimi J	16	M	Progressive jaundice, weight loss	Hepatosplenomegaly	Unknown	Unknown	Head and body
2005	Seki M	57	M	Asymptomatic	Unknown	Unknown	Unknown	Body
2005	Seki M	60	F	Asymptomatic	Unknown	Unknown	Unknown	Body
2006	Koomalsingh KJ	52	M	Epigastric pain	Mild epigastric tenderness	Unknown	Unknown	Tail
2007	Tucci G	64	M	L4-S1 chronic radiculopathy	Unknown	Normal	High	Tail
2007	Rivkine E	45	F	Abdominal pain	None	Normal	Normal	Uncinate process
2008	Zhang AY	67	M	Chest tightness, shortness of breath	None	Unknown	Unknown	Body
2008	Kela M	0.5	M	abdominal swelling	Palpable mass	Unknown	Unknown	Head
2010	Scheele J	40	M	Upper abdominal pain	None	Unknown	62	Head and body
2010	Badia AC	43	F	Epigastric pain, vomiting	Palpable mass, mesogastrium	Unknown	Unknown	Head and body
2011	Daghfous A	41	F	Epigastric pain	Palpable mass	Unknown	Unknown	Tail
2012	Ben Ameur H	64	M	epigastric pain, WL, T, jaundice	Palpable mass	Unknown	Unknown	Head
2012	Degrate L	61	M	Asymptomatic	None	Normal	Normal	Uncinate process
2012	Lane J	63	M	pain right flank	None	2.8	39	body
2012	Razman J	30	M	Asymptomatic	None	5.3	Unknown	Head
2013	Albayrak A	20	F	Epigastric pain	None	Normal	Normal	Head
2013	Campani D	59	M	Asymptomatic	None	Unknown	Unknown	Tail
2013	Lyons DA	35	M	abdominal and back pain	None	Normal	Normal	Tail
2013	da Silva Menezes K	69	M	Asymptomatic	None	Normal	Normal	Tail
2013	Wang J	1	F	jaundice	Palpable mass, RUQ	Normal	Unknown	Head
2014	Wang Y	0.11	F	anorexia, vomit	Palpable mass, central	Normal	Unknown	body
2015	Ahmed A	65	M	abdominal pain, early satiety	Pain, satiety	Unknown	Unknown	body
2015	Lee SE	54	M	Asymptomatic	None	Normal	Normal	Tail
2016	Chakaravarty KD	41	M	pain, distention	Unknown	Normal	Normal	Head/body
2017	Ofori E	49	M	pain, nausea	Tenderness	Normal	Normal	Tail
2018	Li Z	36	F	recurrent abdominal pain	Unknown	Unknown	45.88	Tail
2019	Wang J	1.1	M	Asymptomatic	Palpable mass	Unknown	86.7	Head
2020	Zhou XH	23	F	pain	None	Normal	54.54	Head

Table 1. Continued.

Year Pub	Cyst size (cm)	Size (longest)	Cyst component	Teratoma type	Ectodermal	Endodermal	Mesodermal	Malignant transformation	Monodermal component
1918	Unknown	n/a	Unknown	Dermoid cyst	Unknown	Unknown	Unknown	Unknown	dermal
1921	Unknown	n/a	Unknown	Unknown	Unknown	Unknown	Unknown	Unknown	Unknown
1923	Unknown	n/a	Unknown	Dermoid cyst	dermal	Unknown	Unknown	Unknown	dermal
1943	Unknown	n/a	Unknown	Dermoid cyst	dermal	None	None	None	dermal
1956	Unknown	n/a	Unknown	Dermoid cyst	Unknown	Unknown	Unknown	Unknown	dermal
1970	Unknown	n/a	Unknown	Mature cystic teratoma	Unknown	Unknown	Unknown	Unknown	Unknown
1972	Unknown	n/a	unknown	Dermoid cyst	dermal	Unknown	Unknown	Unknown	dermal
1973	Unknown	n/a	unknown	Dermoid cyst	dermal	Unknown	Unknown	Unknown	dermal
1973	Unknown	n/a	unknown	Unknown	Unknown	Unknown	Unknown	Unknown	Unknown
1977	Unknown	n/a	Unknown	Dermoid cyst	dermal	Unknown	Unknown	Unknown	dermal
1984	Unknown	n/a	Unknown	Dermoid cyst	dermal	Unknown	Unknown	Unknown	dermal
1990	8x8x8	8	multiloculated	Mature cystic teratoma	dermal, glia, nervous	RT	bone, cartilage, adipose, SMC	None	dermal
1990	3x3x3	3	Unknown	Dermoid cyst	dermal	Unknown	Unknown	Unknown	dermal
1993	20 X 20 X 11.5	20	multiloculated	Mature cystic teratoma	dermal, nervous	RT	SMC	None	None
1993	6.5x3x2	6.5	Unknown	Mature cystic teratoma	dermal, glia	RT	BM, cartilage		
1993	12x12x12	12	uniloculated	Dermoid cyst	dermal	None	None	None	dermal
1993	4.5x4.5x4.5	4.5	Unknown	Dermoid cyst	Unknown	Unknown	Unknown	Unknown	dermal
1996	9.5x8	9.5	solid and cystic	Mature cystic teratoma	dermal, nervous	RT, GI	bone, cartilage, adipose, SMC	None	None
1998	10x8x9	10	Unknown	Dermoid cyst	dermal	Unknown	Unknown	None	dermal
2002	7x5x7	7	solid and cystic	Dermoid cyst	dermal	Unknown	Unknown	Unknown	dermal
2003	12x12x12	12	uniloculated	Mature cystic teratoma	dermal, glia	GI	SMC	None	dermal
2004	Unknown		multiloculated	Dermoid cyst	dermal	None	None	None	dermal
2005	5.5x3.7x3.3	5.5	multiloculated	Mature cystic teratoma	dermal	GI	Unknown	None	None
2005	2.1x2.2x1.5	2.2	uniloculated	Dermoid cyst	dermal	None	None	None	dermal
2006	3.5x3	3.5	uniloculated	Dermoid cyst	dermal	None	None	None	dermal
2007	8.5x3	8.5	uniloculated	Dermoid cyst	dermal	None	None	None	None
2007	5.5	5.5	multiloculated	Mature cystic teratoma w/NET	dermal, nervous	GI, RT	fat, muscle, cartilage, bone	None	well diff NET
2008	4.6x3x2.2	4.6	multiloculated	Dermoid cyst	dermal	None	None	None	None
2008	8x7	8	solid and cystic	imMature teratoma	imMature epithelial tissue, nervous	GI	cartilage, fat	None	None
2010	6.4x4.9x3.8	6.4	solid and cystic	Dermoid cyst	dermal	None	None	None	dermal
2010	15x10x10	15	multiloculated	Mature cystic teratoma	Unknown	RT	adipose, muscle	None	None
2011	25x16x18	25	multiloculated	Dermoid cyst	dermal	None	None	None	dermal
2012	10x8	10	solid and cystic	Mature cystic teratoma	dermal	RT	fat, cartilage, SMC, thyroid	None	None
2012	3.2x1.9x3.6	3.2	uniloculated	Dermoid cyst	dermal	None	None	None	dermal
2012	6x5x5	6	uniloculated	Dermoid cyst	dermal	None	None	None	dermal
2012	8.8x7.5	8.8	solid and cystic	Dermoid cyst	dermal	None	None	None	dermal
2013	10x7x5	10	solid and cystic	Dermoid cyst	dermal	None	None	None	None
2013	2x1.5x1	2	solid and cystic	Dermoid cyst	dermal	None	None	None	dermal
2013	2.5x1.7	2.5	multiloculated	Dermoid cyst	dermal	None	None	None	dermal
2013	7.2x6.4x7.2	7.2	multiloculated	Dermoid cyst	dermal	None	None	dermal	None
2013	4.6x4.1x3.3	4.6	solid and cystic	Mixed GCT	dermal	None	None	n/a	n/a
2014	18x15x10	18	uniloculated	Mature cystic teratoma	dermal	RT	Unknown	Unknown	Unknown
2015	9x7	9	uniloculated	Mature cystic teratoma	dermal	RT, GI	None	None	None
2015	4.5	4.5	uniloculated	Dermoid cyst	dermal	None	None	None	dermal
2016	5x4.8	5	solid and cystic	Mature cystic teratoma	dermal, nervous	None	bone, BM, cartilage, adipose	None	None
2017	8.2x2.4x3.6	8.2	multiloculated	Dermoid cyst	dermal	None	None	None	dermal
2018			solid and cystic	Mature cystic teratoma	nervous	GI, RT	cartilage, bone, BM, adipose	None	None
2019	12x9x8	12	solid and cystic	Mature cystic teratoma	dermal	None	adipose, cartilage	None	None
2020	8.3x7.4x7.1	8.3	solid and cystic	Dermoid cyst	dermal	None	None	None	dermal

References

- [1] Tumours of the ovary, "Tumours of the ovary," in WHO Classification of Tumours of Female Reproductive Organs, 4th ed., R. J. Kurman, M. L. Carcangiu, C. S. Herrington, and R. H. Young, Eds. Geneva: WHO Press, 2014.
- [2] L. Degrate *et al.*, "Mature Cystic Teratoma of the Pancreas. Case Report and Review of the Literature of a Rare Pancreatic Cystic Lesion," *Journal of the Pancreas*, vol. 13, no. 1, pp. 66–72, 2012, [Online]. Available: <http://www.serena.unina.it/index.php/>
- [3] P. Hegde, "Extragenital omental teratoma: A case report," *Journal of Obstetrics and Gynaecology Research*, vol. 40, no. 2, Feb. 2014, doi: 10.1111/jog.12198.
- [4] J. Scheele, T. F. Barth, M. Wittau, M. Juchems, D. Henne-Bruns, and M. Kornmann, "Cystic teratoma of the Pancreas," *Anticancer Research*, vol. 32, pp. 1075–1080, 2012.
- [5] M. de Felici, F. G. Klinger, F. Campolo, C. R. Balistreri, M. Barchi, and S. Dolci, "To be or not to be a germ cell: The extragonadal germ cell tumor paradigm," *International Journal of Molecular Sciences*, vol. 22, no. 11, MDPI AG, Jun. 01, 2021. doi: 10.3390/ijms22115982.
- [6] J. W. Oosterhuis and L. H. J. Looijenga, "Human germ cell tumours from a developmental perspective," *Nature Reviews Cancer*, vol. 19, no. 9, Nature Publishing Group, pp. 522–537, Sep. 01, 2019. doi: 10.1038/s41568-019-0178-9.
- [7] J. K. Mckenney, A. Heerema-Mckenney, and R. v Rouse, "Extragenital Germ Cell Tumors: A Review With Emphasis on Pathologic Features, Clinical Prognostic Variables, and Differential Diagnostic Considerations," *Advances in Anatomical Pathology*, vol. 14, no. 2, pp. 69–92, 2007.
- [8] E. J. O'Donovan, K. Thway, and E. C. Moskovic, "Extragenital teratomas of the adult abdomen and pelvis: a pictorial review," *The British journal of radiology*, vol. 87, no. 1041, p. 20140116, Sep. 2014, doi: 10.1259/bjr.20140116.
- [9] H. Sun *et al.*, "The differences between gonadal and extra-gonadal malignant teratomas in both genders and the effects of chemotherapy," *BMC Cancer*, vol. 19, no. 1, Dec. 2019, doi: 10.1186/s12885-019-5598-0.
- [10] J. Lane, A. Vance, D. Finelli, G. Williams, and P. Ravichandran, "Dermoid cyst of the pancreas: A case report with literature review," *Journal of Radiology Case Reports*, vol. 6, no. 12, pp. 17–25, Dec. 2012, doi: 10.3941/jrcr.v6i12.1152.
- [11] J. L. Decourcy, "Dermoid Cyst of the Pancreas," *Annals of Surgery*, vol. 118, no. 3, pp. 394–395, 1943.
- [12] C. Iacono *et al.*, "Dermoid Cyst of the Head of the Pancreas Area," *International Journal of Pancreatolgy*, vol. 14, no. 3, pp. 269–273, 1993.
- [13] J. E. Jacobs and B. J. Dinsmore, "Mature Cystic Teratoma of the Pancreas: Sonographic and CT Findings," *American Roentgen Ray Society*, vol. 160, pp. 523–524, 1993, [Online]. Available: www.ajronline.org
- [14] M. Kela, S. Singh, and B. Lahoti, "Immature cystic teratoma of head of pancreas," 2008. [Online]. Available: <https://www.jiaps.com/printarticle.asp?issn=0971-9261;year=2008;volume=13;issue=2;page=85;epage=87;aulast=Kela>
- [15] V. Markovsky and V. Russin, "Fine-Needle Aspiration of Dermoid Cyst of the Pancreas," *Diagnostic Cytopathology*, vol. 9, no. 1, pp. 66–69, 1993.
- [16] M. Mester *et al.*, "Cystic Teratomas of the Pancreas," *Archives of Surgery*, vol. 125, pp. 1215–1218, 1990, [Online]. Available: <http://archsurg.jamanetwork.com/>
- [17] E. Rivkine *et al.*, "Tératome kystique du pancréas," *Gastroenterologie Clinique et Biologique*, vol. 31, no. 11, pp. 1016–1019, 2007, doi: 10.1016/S0399-8320(07)78323-9.
- [18] J. Salimi, M. Karbakhsh, S. Dolatshahi, M. Seyyed, and A. Ahmadi, "Cystic teratoma of the pancreas: a case report," *Ann Saudi Med*, vol. 24, no. 3, pp. 206–209, 2004, [Online]. Available: www.kfshrc.edu.sa/annals
- [19] M. Seki *et al.*, "Image-diagnostic features of mature cystic teratomas of the pancreas: Report on two cases difficult to diagnose preoperatively," *Journal of Hepato-Biliary-Pancreatic Surgery*, vol. 12, no. 4, pp. 336–340, Aug. 2005, doi: 10.1007/s00534-005-0994-z.
- [20] G. Strasser, M. Kutilek, P. Mazal, and W. Schima, "Mature teratoma of the pancreas: CT and MR findings," *European Radiology*, vol. 12, no. SUPPL. 3, 2002, doi: 10.1007/s00330-002-1407-1.
- [21] G. Tucci *et al.*, "Dermoid cyst of the pancreas: Presentation and management," *World Journal of Surgical Oncology*, vol. 5, Aug. 03, 2007. doi: 10.1186/1477-7819-5-85.
- [22] C. W. Yu, K. L. Liu, W. C. Lin, and Y. W. Li, "Mature cystic teratoma of the pancreas in a child," *Pediatric Radiology*, vol. 33, no. 4, pp. 266–268, Apr. 2003, doi: 10.1007/s00247-003-0872-2.
- [23] A. Y. Zhang, S. K. Thompson, P. A. Game, and J. J. Allin, "Cystic teratoma of the pancreas: A rare entity," *ANZ Journal of Surgery*, vol. 78, no. 12, pp. 1130–1131, Dec. 2008, doi: 10.1111/j.1445-2197.2008.04766.x.
- [24] D. Campani, G. Gallippi, M. Granai, N. de Lio, and U. Boggi, "Dermoid cyst of the pancreas," *International Journal of Colorectal Disease*, vol. 28, no. 4, pp. 597–598, Apr. 2013. doi: 10.1007/s00384-012-1506-7.
- [25] C. Kellen *et al.*, "Dermoid cyst of the pancreas: a case report," *J Bras Patol Med Lab*, vol. 49, no. 5, pp. 324–346, 2013.
- [26] J. Razman *et al.*, "An interesting case of isolated pancreatic teratoma: lessons to learn Case report," *Clin Ter*, vol. 163, no. 6, pp. 495–497, 2012.
- [27] P. C. Das and P. L. N G Rao, "Cystic teratoma of the pancreas," 1996.
- [28] Y. Wang *et al.*, "Childhood cystic teratoma of the pancreas: Clinical presentation, evaluation and management," *Pancreatolgy*, vol. 14, no. 4, pp. 312–315, 2014, doi: 10.1016/j.pan.2014.03.021.
- [29] Z. Li, N. Ke, X. Liu, and S. Gong, "Mature cystic teratoma of the pancreas with 30 years of clinical course: A case report," *Medicine (United States)*, vol. 97, no. 15, Apr. 2018, doi: 10.1097/MD.00000000000010405.

- [30] J. Scheele, T. F. E. Barth, J. Straburg, M. Juchems, M. Kornmann, and D. Henne-Bruns, "Dermoid cyst of the pancreas," *International Journal of Colorectal Disease*, vol. 25, no. 3, pp. 415–416, Mar. 2010. doi: 10.1007/s00384-009-0811-2.
- [31] X. H. Zhou, J. K. Ma, B. Valluru, K. Sharma, L. Liu, and J. B. Hu, "Diagnosis and differentiation of mature cystic teratoma of pancreas from its mimics: A case report," *Medicine*, vol. 99, no. 47, p. e23267, Nov. 2020, doi: 10.1097/MD.00000000000023267.
- [32] A. Albayrak, U. Yildirim, and M. Aydin, "Dermoid Cyst of the Pancreas: A Report of an Unusual Case and a Review of the Literature," *Case Reports in Pathology*, vol. 2013, pp. 1–5, 2013, doi: 10.1155/2013/375193.
- [33] D. K. Chakaravarty et al., "Mature Cystic Teratoma of the Pancreas," *ACG Case Reports Journal*, vol. 3, no. 1, pp. 80–81, 2016, doi: 10.14309/crj.2016.5.
- [34] A. Ahmed, L. Peng, and D. Agrawal, "Mature cystic teratoma of the pancreas: Role of endoscopic ultrasound," *Pancreatology*, vol. 15, no. 4, pp. 445–448, Jul. 2015, doi: 10.1016/j.pan.2015.05.469.
- [35] K. J. Koomalsingh, R. Fazylov, M. I. Chorost, and J. Horovitz, "Cystic Teratoma of the Pancreas: Presentation, Evaluation and Management," 2006. [Online]. Available: <http://www.joplink.net>
- [36] S. E. Lee, Y. S. Choi, S. U. Hong, H. C. Oh, and E. S. Lee, "Dermoid cyst of the pancreas: A rare cystic neoplasm," *International Journal of Surgery Case Reports*, vol. 17, pp. 72–74, 2015, doi: 10.1016/j.ijscr.2015.10.026.
- [37] A. Casajoana Badia, N. Pelaez Sera, J. Fabregat Prous, T. Serrano Piñol, and C. Valls serra, "Cystic teratoma of the pancreas," *Cirugia Espanola*, vol. 88, no. 6, pp. 414–430, Dec. 2010, doi: 10.1016/j.ciresp.2010.01.005.
- [38] A. Daghfous et al., "Mature teratoma of the pancreas diagnosed by fine-needle aspiration," *Arab Journal of Gastroenterology*, vol. 12, no. 2, pp. 92–93, Jun. 2011, doi: 10.1016/j.ajg.2011.04.009.
- [39] D. A. Lyons, E. A. Coberly, G. M. Hammoud, and M. B. Nicholl, "Case Report of Pancreatic Dermoid Cyst: Can Fine Needle Aspiration Make the Diagnosis?," *Journal of the Pancreas*, vol. 14, no. 6, pp. 653–656, 2013, [Online]. Available: <http://www.serena.unina.it/index.php/>
- [40] E. Ofori, D. Ramai, D. Etienne, M. Reddy, and G. Shahzad, "Large Dermoid Cyst Presenting as Recurrent Pancreatitis," *Gastroenterology Research*, vol. 10, no. 5, pp. 322–324, 2017, doi: 10.14740/gr876w.
- [41] H. ben Ameur, S. Boujelbene, C. Abdelhedi, O. Gheriani, and M. I. Beyrouti, "Mature cystic teratoma of the pancreas," *Updates in Surgery*, vol. 64, no. 4, pp. 311–314, Dec. 2012, doi: 10.1007/s13304-011-0116-1.
- [42] J. Wang et al., "Primary mixed germ cell tumor arising in the pancreatic head," *Journal of Pediatric Surgery*, vol. 48, no. 1, Jan. 2013, doi: 10.1016/j.jpedsurg.2012.10.054.